



OPEN ACCESS

EDITED BY
Zihua Ren,
Sichuan Agricultural University, China

REVIEWED BY
Adil Mehraj Khan,
Sher-e-Kashmir University of
Agricultural Sciences and
Technology, India
Jianzhao Liao,
South China Agricultural
University, China

*CORRESPONDENCE
Walter H. Hsu
whsu@iastate.edu

SPECIALTY SECTION
This article was submitted to
Veterinary Pharmacology and
Toxicology,
a section of the journal
Frontiers in Veterinary Science

RECEIVED 21 August 2022
ACCEPTED 19 October 2022
PUBLISHED 07 November 2022

CITATION
Elazab ST and Hsu WH (2022)
Antagonism of cadmium-induced liver
injury in ducks by α -bisabolol.
Front. Vet. Sci. 9:1024549.
doi: 10.3389/fvets.2022.1024549

COPYRIGHT
© 2022 Elazab and Hsu. This is an
open-access article distributed under
the terms of the [Creative Commons
Attribution License \(CC BY\)](https://creativecommons.org/licenses/by/4.0/). The use,
distribution or reproduction in other
forums is permitted, provided the
original author(s) and the copyright
owner(s) are credited and that the
original publication in this journal is
cited, in accordance with accepted
academic practice. No use, distribution
or reproduction is permitted which
does not comply with these terms.

Antagonism of cadmium-induced liver injury in ducks by α -bisabolol

Sara T. Elazab¹ and Walter H. Hsu^{2*}

¹Department of Pharmacology, Faculty of Veterinary Medicine, Mansoura University, Mansoura, Egypt, ²Department of Biomedical Sciences, College of Veterinary Medicine, Iowa State University, Ames, IA, United States

Cadmium (Cd) is an ecological pollutant which causes hazardous effects in animals and humans. The aim of this study was to investigate the role of α -bisabolol (BISA) in antagonizing the Cd-induced hepatotoxicity in ducks. Two-week old ducks were allocated into 8 groups (10 ducks/group): Group I received basal diet and was gavaged with sunflower oil (BISA vehicle, 1.1 mL/kg/day); group II was administered BISA orally (50 mg/kg/day; diluted with sunflower oil); groups III, IV, and V were fed the basal diet mixed with CdCl₂ at 37.5, 75, and 150 mg/kg diet, respectively, and were gavaged with sunflower oil; group VI, VII, and VIII were given basal diet containing CdCl₂ at the aforementioned consecutive doses plus BISA. All treatments were provided daily for 4 weeks. Exposure to CdCl₂ induced mortality in ducks, increased hepatic Cd content and serum levels of hepatopathic biomarkers, and caused oxidative stress and morphological alterations in ducks' liver. Furthermore, exposure to Cd caused upregulation of the mRNA of proinflammatory cytokine tumor necrosis factor- α and apoptotic gene Bax, and that of cyclooxygenase-2 protein in the liver. All effects of Cd were dose-dependent. BISA antagonized all of the aforementioned CdCl₂-induced changes. These findings suggested that BISA exert the hepatoprotective effect against Cd toxicity through reducing the hepatic content of Cd as well as antagonizing oxidative insults, inflammation, and apoptosis. Thus, BISA has a great potential to be used as an antidote in the control of Cd poisoning.

KEYWORDS

α -bisabolol, cadmium, hepatotoxicity, inflammation, oxidative stress

Introduction

Cadmium (Cd), a heavy metal, is considered one of the deleterious environmental pollutants. Cd is one of the 10 most hazardous compounds to human and animal health (1). In 1993, the International Agency for Research on Cancer ranked Cd as a Class I carcinogen (2, 3). The sources of Cd exposure stem from its industrial utilization as plastic stabilizers, pigments, alloy, and batteries, as well as being used in mining process (4). Additionally, the soil pollution by Cd results from the extensive usage of fertilizers, pesticides, waste water, and sewage sludge (5). Cd is highly water soluble which leads to its rapid absorption by plants with consequent accumulation in food and feed (6).

Former reports have revealed that the bioaccumulation of Cd in chickens can result in serious injuries of several organs, e.g., liver, kidney, heart, lung, brain, testis, and ovary (7). Since Cd has a long half-life of 10–30 years and a slow excretion from the body, it is accumulated in multiple tissues and organs, hence threatening human health *via* transmission through food chain (8).

Oxidative stress is regarded as the chief mechanism for Cd hepatotoxicity (9). Cd enhances the generation of reactive oxygen species (ROS) as hydroxyl radical (OH^-), hydrogen peroxide (H_2O_2), and superoxide (O_2^-) which interact with multiple cellular molecules, resulting in lipid and protein peroxidation and DNA injury as well as apoptosis (10).

Numerous investigations have indicated that antioxidant substances exert their ameliorative effects against Cd-induced hepatic damage through their potential role in free radicals scavenging (11). α -Bisabolol (BISA), also named levomenol, is a volatile sesquiterpene monocyclic alcohol (12). It is a natural component of the essential oil of multiple medicinal plants of the *Asteraceae* family (13). BISA has many biological effects, e.g., antimicrobial (14), antioxidant (15), anti-inflammatory (16), anticancer (17), and antimutagenic activities (18). Furthermore, prior investigations highlighted the palliative role of BISA against isoproterenol-induced myocardial infarction in rats (19), neurotoxicity induced by rotenone in *Drosophila melanogaster* (20), and ischemic reperfusion-induced acute renal injury (21). To the best of our knowledge, the effect of BISA on Cd-induced hepatic damage has not been reported.

The present study was performed to assess the antagonistic effect of BISA on Cd-induced hepatotoxicity. In the present research, we used ducks as an experimental model as they are considered as an important experimental animal in environmental toxicology (22). Moreover, ducks are important in animal production in view of their extensive utilization as traditionally available economic animals. Therefore, this study may confer a practical approach to counteract the global Cd pollution.

Materials and methods

Chemicals

Cadmium chloride (CdCl_2) and α -bisabolol were procured from Sigma Aldrich Co. (St. Louis, MO, USA). BISA was used after being diluted with sunflower oil (50 mg BISA/mL sunflower

oil). Perchloric acid and nitric acid were bought from Merck Co. (Darmstadt, Germany).

Experimental animals

In this study, a total of 80 one-day-old Muscovy ducks were provided by Faculty of Agriculture, Mansoura University, Egypt; they were housed in disinfected floor pens covered with sawdust litter. The ambient temperature was set at 30–32°C during the first 7 days and gradually declined to $25 \pm 1^\circ\text{C}$ at the end of the study. The environmental humidity was set at 50–65%. The ducks underwent a 2-week adaptation period prior to the study. Throughout the experiment, feed and water were freely available to ducks. The feed ingredients and chemical components of the basal diet are shown in [Supplementary Table S1](#). All procedures conducted in the present work were accepted by the Medical Research Ethics Committee of the Faculty of Veterinary Medicine, Mansoura University, Mansoura, Egypt (Approval No. R/117).

Experimental design

A total of 80 two-week old ducks were randomly assigned to 8 groups, with 10 ducks in each group. Group I (control group) was offered basal diet and was gavaged with sunflower oil (BISA vehicle) at a dose of 1.1 mL/kg each day (23). Group II was provided with basal diet and received BISA (50 mg/kg/day), in sunflower oil (50 mg BISA/mL), by gavage. The dose of BISA was selected based on previous reports (24, 25). Groups III, IV, and V were fed basal diet containing CdCl_2 at 37.5, 75, and 150 mg/kg diet, respectively, and were gavaged with sunflower oil at 1.1 mL/kg/day. These CdCl_2 doses were previously used for toxicological studies in chickens (26, 27). Groups VI, VII, and VIII were fed basal diet plus CdCl_2 at the above-mentioned consecutive doses and were administered orally BISA (50 mg/kg/day). This experiment lasted 4 weeks, during which the ducks were monitored for clinical signs of Cd-toxicity and weekly body weight changes and mortality. The experimental period was selected according to a former study (28). At the end of the 4th week, blood samples from 6 ducks in each group were collected from the wing vein. The serum was obtained *via* centrifugation of the clotted blood samples at $3,000 \times g$ for 10 min, and stored at -80°C until the evaluation of liver function biomarkers. The ducks were then euthanized by exsanguination and the liver was dissected and washed with ice-cold 0.9% NaCl solution. The liver tissue was divided into 3 portions; the first portion was homogenized, then centrifuged at $3,000 \times g$ for 15 min and the harvested supernatant was kept at -80°C for later determination of oxidative stress biomarkers. The second portion was kept at -80°C to be used in the quantitative

Abbreviations: ALT, Alanine aminotransferase; BISA, α -bisabolol; BWG, Body weight gain; CAT, Catalase; Cd, Cadmium; COX-2, Cyclooxygenase-2; FBW, Final body weight; GSH, Reduced glutathione; IL-1 β , Interleukin-1 β ; IL-6, Interleukin-6; NF-KB, nuclear factor-kappa B; ROS, Reactive oxygen Species; SOD, Superoxide dismutase; TNF- α , Tumor necrosis factor- α .

TABLE 1 Sequences of primers utilized in qRT-PCR.

Target gene	Forward primer (5'-3')	Reverse primer (5'-3')	References
TNF- α	CCGTGGTCAGTTT7gCCATCAGG	ACTTTGCAGTTAGGTGACGCT	(34)
Bax	GCGGACGGAGCCTTCAACTG	CTGCGAGAACAGAGCCTTGATGG	
Bcl-2	GAGTTCGGCGGCATCATGTG	CCATACAACCTCCACGAAGGCATCC	
β . actin	ATGTCGCCCTGGATTTCG	CACAGGACTCCATACCCAAGAA	

real time polymerase chain reaction (qRT-PCR). The third portion was fixed in 10% formalin for histopathological and immunohistochemical evaluations.

Biochemical investigation

Serum hepatic indices

The activity of serum alanine aminotransferase (ALT) and total bilirubin were assayed spectrophotometrically using commercial kits purchased from Randox Co. (Crumlin, UK) and BioMed Co. (Cairo, Egypt), respectively. The procedures were performed by following the instructions provided by manufacturers.

Antioxidant and oxidative stress parameters

The malondialdehyde (MDA) level in the hepatic tissue homogenate was evaluated as previously described by Ohkawa et al. (29). The antioxidant enzymatic activities of catalase (CAT) and superoxide dismutase (SOD) were determined using a spectrophotometer following the reports of Aebi (30) and Minami and Yoshikawa (31), respectively. In addition, the content of reduced glutathione (GSH), the nonenzymatic antioxidant marker, was evaluated as described by Paglia and Valentine (32).

Determination of hepatic Cd content

One gram of liver sample was excised and subjected to digestion by a mixture of 2.5 mL perchloric acid (70%) and 5 mL nitric acid (65%). After incubation of this mixture overnight in a water bath at 53°C, the suspension was filtered and 30 mL deionized water was added to the filtrate for dilution. The hepatic Cd concentrations were determined using flame atomic absorption spectrophotometer at a wavelength of 228.8 nm (Buck Scientific 210 VGP, Inc.) following the technique recommended by the Association of Official Analytical Chemists (33).

Transcription of target genes [tumor necrosis factor- α (TNF- α), Bax, and Bcl-2] utilizing qRT-PCR)

The hepatic RNA was isolated utilizing QIAamp RNeasy Mini kit (Qiagen, Heidelberg, Germany). A NanoDrop[®] (ND-1000) was used for measuring the purity and concentration of the extracted RNA. The first strand of cDNA was synthesized from the isolated RNA employing QuantiTect Reverse Transcription kit (Qiagen, Heidelberg, Germany) according to manufacturer's guidelines. qRT-PCR reactions were performed using SYBR Green QuantiTect PCR kits (Qiagen, Heidelberg, Germany) by the aid of a Rotor-Gene Q cyler RT-PCR equipment (Qiagen, Heidelberg, Germany). β -Actin was used as the reference housekeeping gene. Primer sequences of the investigated duck genes were derived from a previous study (32) and are listed in Table 1. The cycling conditions of qRT-PCR were as follows: 94°C for 5 min; 30 cycles of 94°C for 30 s, 55°C for 30 s and 72°C for 60 s, at last elongation at 72°C for 10 min. The relative expression levels of the target genes were determined *via* the comparative $2^{-\Delta\Delta Ct}$ method (Ct: cycle threshold) as reported by Yuan et al. (35).

Hepatic histopathological screening

Tissue specimens from liver were preserved in 10% formalin. Thereafter, they were processed following the classical histological technique, starting with dehydration using ascending concentrations of alcohol and ended by embedding in paraffin. Multiple tissue sections (4 μ m in thickness) were prepared for histological staining. The sections were stained with hematoxylin and eosin (H&E) and then investigated under a light microscope as reported by Bancroft and Layton (36). We conducted semiquantitative scoring of hepatic lesions following the method of Gibson-Corley et al. (37). Lesions in 3 fields chosen randomly from each slide for each duck were determined. A blinded process was utilized for lesion scoring [Score scale: 0 = normal with 0% lesions; 1 = \leq 25%; 2 = 26–50%; 3 = 51–75%; 4 = 76–100%]. The identification of hepatic lesions in ducks depended on the ratio of hepatocyte degeneration, congestion and fibrosis. The extent of fibrosis was

examined by staining the liver sections with Masson's trichrome stain. The sections were photographed and investigated using a light microscope. Quantification of the percent of the area with fibrosis was conducted using Image J software (National Institutes of Health, Bethesda, MD, USA).

Immunohistochemistry

Cyclooxygenase-2 (COX-2) immunohistochemical staining of ducks' hepatic sections was conducted utilizing the avidin-biotin peroxidase method as reported by Lin and Prichardas (38). Photomicrographs of the sections were taken employing a digital camera (Leica EC3, Leica, Leica 148 Germany) attached to a microscope (Leica DM500, Leica, Germany). The Image J software (National Institutes of Health, Bethesda, MD, USA) was used to quantify the intensities of immunostaining. The inverse mean density was evaluated as reported by Vis et al. (39) in 3 fields being selected in a random method from different sections of 6 ducks/group.

Statistical analysis

All values are expressed as mean \pm SEM. The Shapiro Wilk test was applied for examining the normality of the data. Statistical analysis was achieved using Statistical Package for Social Sciences (SPSS), version 20 for windows (SPSS Inc., Chicago, IL, USA). Data of histopathological score and immunohistochemical examination were investigated utilizing Kruskal-Wallis followed by Dunn's test to compare all means. All other data were analyzed employing the one-way ANOVA. Mean comparisons were performed utilizing Tukey's *post-hoc* test. The $p < 0.05$ was regarded as statistically significant.

Results

Clinical signs observations, body weight changes and mortality rates

Several clinical signs of Cd toxicity were observed in ducks receiving CdCl₂ at 75 and 150 mg/kg such as dullness, gasping, restlessness, depression, lethargy, increased water consumption, weakness, and imbalanced gait. These clinical signs began to emerge during the 2nd week of the experiment and aggravated by the end of the 4th week. These signs were more prominent in the group receiving CdCl₂ at 150 mg/kg feed. On the other hand, ducks in BISA + Cd 75 and BISA + Cd 150 groups displayed milder clinical signs and reduced water consumption. Furthermore, CdCl₂-treated groups exhibited a significant reduction ($p < 0.05$) in the final body weight (FBW) and body weight gain (BWG), compared to the control group. Meanwhile, a significant elevation ($p < 0.05$) in FBW and BWG

TABLE 2 Effect of α -bisabolol on body weight changes and mortality in ducks receiving CdCl₂ in feed for 4 weeks.

Experimental groups	Parameters			
	IW (g/duck)	FBW (g/duck)	BWG (g/duck)	Mortality
C	51.52 \pm 0.26	1814.00 \pm 20.99 ^{a,b}	1762.48 \pm 19.45 ^{a,b}	0/10
BISA	51.46 \pm 0.19	1853.83 \pm 16.23 ^a	1802.37 \pm 16.11 ^a	0/10
Cd 37.5	51.93 \pm 0.23	1572.00 \pm 22.15 ^c	1520.07 \pm 22.03 ^c	0/10
Cd 75	52.03 \pm 0.18	1368.50 \pm 34.92 ^d	1316.47 \pm 34.99 ^d	2/10
Cd 150	51.56 \pm 0.22	1207.67 \pm 36.47 ^e	1156.10 \pm 36.41 ^e	3/10
BISA + Cd 37.5	51.75 \pm 0.40	1723.33 \pm 27.37 ^b	1671.58 \pm 27.61 ^b	0/10
BISA + Cd 75	52.08 \pm 0.28	1636.50 \pm 37.53 ^c	1584.42 \pm 37.73 ^c	0/10
BISA + Cd 150	51.8 \pm 0.16	1545.00 \pm 27.06 ^c	1493.20 \pm 27.02 ^c	1/10

Data of body weight changes are presented as the mean \pm SEM ($n = 6$). ^{a–e} Different superscripts within each column (for each parameter) represent significant differences ($p < 0.05$). C, control; BISA; α -bisabolol; Cd 37.5, Cd 75, Cd150: CdCl₂ was administered at 37.5, 75, and 150 mg/kg feed, respectively, for 4 weeks; IW, initial weight; FBW, final body weight; BWG, body weight gain.

was observed in groups receiving BISA + CdCl₂, compared to those receiving CdCl₂ only. The mortality rates of CdCl₂-treated ducks at doses of 75 was 20% as one duck died in the 1st week of experiment and another duck in the 3rd week. Moreover, the mortality rate of ducks receiving CdCl₂ at 150 mg/kg was 30% as one duck died in the 1st week, another one died in the 2nd week, and the third duck died in the 4th week. While, the control group had 0% mortality. Contrarily, the mortality rates in BISA + Cd 75 and BISA + Cd 150 groups were 0 and 10% (as one duck died from BISA + Cd 150 in the 2nd week), respectively, which were lower than those in the groups receiving CdCl₂ only at the corresponding dose (Table 2).

Cd content in hepatic tissues

As illustrated in Figure 1, the hepatic Cd content in CdCl₂-exposed ducks at doses of 37.5, 75, and 150 mg/kg diet were significantly higher ($p < 0.05$) than that in the controls. In contrast, a significant reduction ($p < 0.05$) in the hepatic Cd content was recorded in all BISA + Cd groups, compared to those treated with the corresponding CdCl₂ dose only.

Serum hepatic parameters

BISA alone did not cause significant alterations in the hepatic indices ALT and bilirubin. On the other hand, serum ALT activity and total bilirubin level significantly ($p < 0.05$) increased in a dose-dependent manner in CdCl₂-treated groups (III, IV, and V) by 70, 108, and 193%, respectively (for serum ALT) and by 31, 86, and 186%, respectively (for serum total

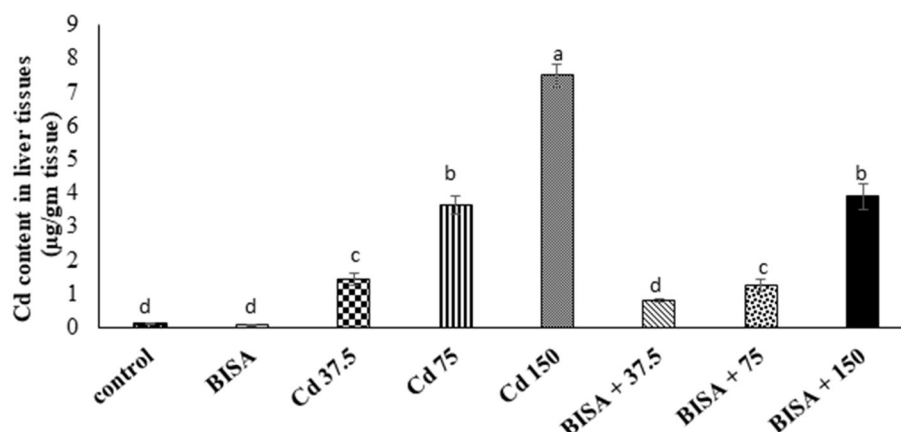


FIGURE 1

Concentration of Cd in the hepatic tissue of ducks following treatment with oral α -bisabolol (50 mg/kg/day) and/or CdCl₂ at 37.5, 75, and 150 mg/kg diet, respectively) for 4 weeks. Data are shown as mean \pm SEM ($n = 6$ ducks). Bars carrying different letters are significantly different from one another ($p < 0.05$). C, control; BISA, α -bisabolol.

TABLE 3 Effect of α -bisabolol on serum ALT and bilirubin levels in ducks receiving CdCl₂ in feed for 4 weeks.

Experimental groups	Parameters	
	ALT (U/L)	Total bilirubin (mg/dL)
C	19.85 \pm 0.94 ^d	0.49 \pm 0.02 ^c
BISA	18.15 \pm 0.98 ^d	0.41 \pm 0.03 ^c
Cd 37.5	33.90 \pm 1.93 ^{b,c}	0.64 \pm 0.05 ^{b,c}
Cd 75	41.47 \pm 3.50 ^b	0.90 \pm 0.06 ^b
Cd 150	58.25 \pm 4.24 ^a	1.39 \pm 0.16 ^a
BISA + Cd 37.5	23.65 \pm 1.57 ^d	0.50 \pm 0.03 ^c
BISA + Cd 75	25.05 \pm 2.47 ^{c,d}	0.55 \pm 0.03 ^c
BISA + Cd 150	36.85 \pm 3.62 ^b	0.86 \pm 0.05 ^b

Data are expressed as the mean \pm SEM ($n = 6$). ^{a-d}Different superscripts within each column (for each parameter) represent significant differences ($p < 0.05$). C, control; BISA; α -bisabolol; Cd 37.5, Cd 75, Cd150: CdCl₂ was administered at 37.5, 75, and 150 mg/kg feed, respectively, for 4 weeks), ALT, alanine aminotransferase.

bilirubin), as compared to the control group. However, co-administration of BISA with CdCl₂ at different CdCl₂ doses (groups VI, VII, and VIII) showed a significant ($p < 0.05$) decline in serum ALT activity and total bilirubin level as compared to ducks exposed to CdCl₂ alone at the corresponding dose. These hepatic indices returned to normal in BISA + Cd 37.5 and BISA + Cd 75 groups, while they were still higher in BISA + Cd 150 group than the control group, but lower than the CdCl₂ alone group (Table 3).

Histopathological findings

Figure 2 shows the light photomicrographs of hepatic tissues. Figures 2A,B display normal hepatocytes arranged in

cords around the central vein with opened sinusoids in the control and BISA groups. In contrast, a dose-dependent histological deformities in the form of hydropic degeneration in hepatic cells, occluded sinusoids, congested central veins, and perivascular fibrosis were detected in CdCl₂-exposed groups receiving 37.5, 75, and 150 mg/kg diet; the most extreme lesions were seen in CdCl₂ 150 mg/kg diet-treated ducks (Figures 2C–E). While, the hepatic sections of groups treated with BISA + CdCl₂ revealed much less severe lesions than the groups receiving the corresponding CdCl₂ dose alone (Figures 2F–H). The semiquantitative scoring of hepatic lesions is illustrated in Figure 2I.

The microscopic photograph of Masson's trichrome-stained hepatic sections exhibited normal hepatic cells and central vein with no collagen deposition in the control and BISA groups (Figures 3A,B). While, hepatic sections from ducks receiving CdCl₂ at 37.5 mg/kg diet showed blue-stained collagen deposition in portal areas (Figure 3C). Collagen deposition increased in Cd 75- and Cd 150-groups (Figures 3D,E). In contrast, a marked decrease ($p < 0.05$) in blue-stained collagen deposition was seen in groups receiving CdCl₂ + BISA. compared with the groups receiving corresponding CdCl₂ dose alone (Figures 3F–H). The percent of area of collagen deposition in hepatic tissues of all experimental groups is shown in Figure 3I.

Oxidative stress and antioxidant markers in hepatic tissues

As shown in Table 4, CdCl₂ administration produced a status of oxidative stress in hepatic tissues as depicted by marked elevation of MDA levels ($p < 0.05$) and reduction in the activities

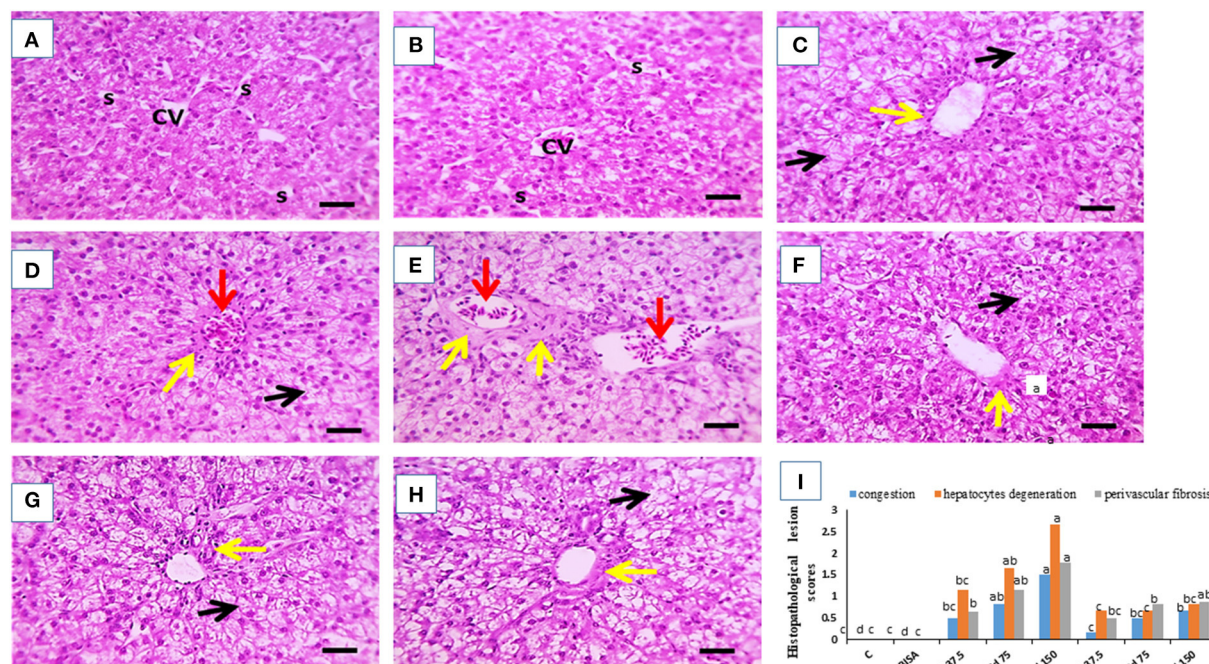


FIGURE 2

Effect of oral α -bisabolol (BISA; 50 mg/kg/day) on histopathological alterations caused by CdCl₂ at different doses in ducks' hepatic tissue. (A) is for the control group (C), and (B) is for the BISA alone group; both groups show normal hepatocytes (H), central vein (CV), and opened sinusoids (S). (C–E) represent groups receiving CdCl₂ at 37.5, 75, and 150 mg/kg diet, respectively, and showing hydroptic degeneration in hepatocytes (black arrows), occluded sinusoids, congested central veins (red arrows), perivascular fibrosis (yellow arrows). The higher the dose of CdCl₂, the more severe the lesions. (F–H) are for groups receiving BISA + CdCl₂ at 37.5, 75, and 150 mg/kg diet, respectively, exhibiting less severe lesions than those of the corresponding Cd alone groups. (I) shows the semiquantitative scoring of hepatic lesions. Lesions in 3 fields chosen randomly from each slide for each duck were determined. A blinded process was utilized for lesion scoring [Score scale: 0 = normal with 0% lesions; 1 = \leq 25%; 2 = 26–50%; 3 = 51–75%; 4 = 76–100%]. The identification of hepatic lesions in ducks depended on the ratio of hepatocyte degeneration, congestion and fibrosis. Bars carrying different letters are significantly different from one another ($p < 0.05$). Scale bar = 50 μ m. The sections were stained with H&E, X400.

of SOD, CAT and GSH levels in Cd 37.5, Cd 75, and Cd 150 groups, compared to the controls ($p < 0.05$). In contrast, BISA + Cd 37.5, BISA + Cd 75, and BISA + Cd 150 groups had a significant reduction ($p < 0.05$) in the hepatic MDA level when compared to the group receiving the corresponding CdCl₂ dose alone. Additionally, in ducks receiving both BISA and Cd, the levels of GSH, SOD, and CAT activities were significantly increased ($p < 0.05$), compared with groups-treated with the corresponding doses of CdCl₂ only.

The mRNA expression of TNF- α , Bax, and Bcl-2 genes

The mRNA expression of a proinflammatory cytokine TNF- α and an apoptotic gene Bax were significantly upregulated ($p < 0.05$) in the hepatic tissue of CdCl₂-treated ducks, compared to the controls. Conversely, a marked downregulation ($p < 0.05$) in the expression of the hepatic anti-apoptotic gene (Bcl-2) was observed in these ducks, compared to the controls.

Also, the mRNA levels of TNF- α and Bax dramatically declined ($p < 0.05$) in ducks receiving BISA + CdCl₂, compared to those exposed to the corresponding dose of CdCl₂ only. The expression patterns of TNF- α and Bax genes were completely reversed in BISA + Cd 37.5 and BISA + Cd 75 groups, while they remained significantly higher than the controls in BISA + Cd 150 group. Besides, co-administration of BISA with CdCl₂ restored the expression levels of Bcl-2 to the level of the controls (Figure 4).

Immunohistochemical findings of COX-2

The microscopic photographs of immunostained hepatic sections for COX-2 demonstrated very mild positive brown staining of COX-2 in the cytoplasm of hepatocytes in the control and BISA groups (Figures 5A,B). The positive brown staining increased with increasing dose of CdCl₂ (Figures 5C–E). In contrast, ducks receiving BISA + CdCl₂ displayed remarkable reduction of COX-2 staining, compared to the corresponding

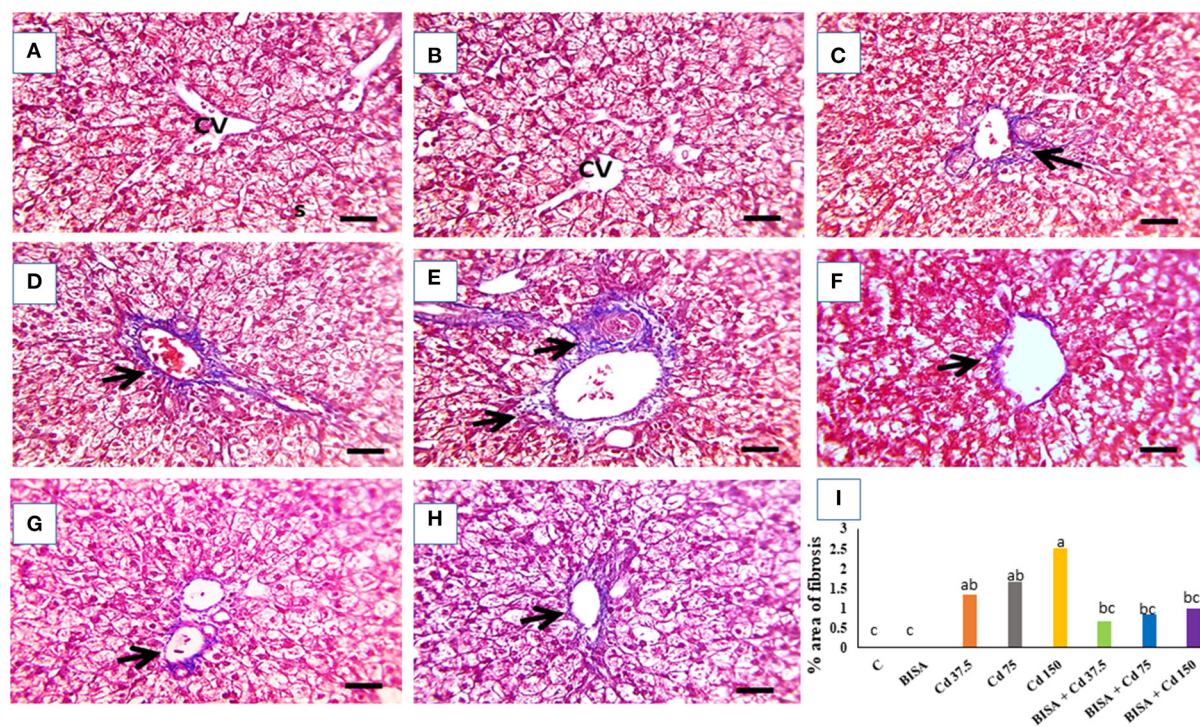


FIGURE 3

The representative light photomicrographs of ducks' hepatic section (stained with Masson's trichrome, X400). (A) Represents the control group (C) and (B) is for the α -bisabolol (BISA) alone group; both groups show normal hepatocytes and central vein (CV) with no collagen deposition. (C–E) are for groups receiving CdCl₂ at 37.5, 75, and 150 mg/kg diet, respectively, revealing blue-stained collagen deposition in portal areas which increase with the increasing dose of CdCl₂. (F–H) Represent BISA + Cd 37.5, BISA + Cd 75, and BISA + Cd 150 groups, respectively, and show remarkable reduction in blue color-stained collagen deposition, compared to the corresponding groups receiving CdCl₂ only. (I) Exhibits the percent of area of collagen deposition. Data are shown as mean \pm SEM ($n = 6$ ducks). Bars carrying different letters are significantly different from one another ($p < 0.05$). Quantification of the percent of the area with fibrosis was conducted using Image J software (National Institutes of Health, Bethesda, MD, USA). Scale bar=50 μ m.

CdCl₂-alone groups (Figures 5F–H). Figure 5I elucidated the quantitative data of COX-2 staining in hepatic tissues for the experimental groups.

Discussion

The current research investigated the toxicological effects of CdCl₂ at 3 doses (37.5, 75, and 150 mg/kg feed), on the hepatic tissues and the role of BISA in antagonizing Cd intoxication in ducks. The present study revealed overt adverse clinical signs in ducks after CdCl₂ administration at 75 and 150 mg/kg. These observations are in accordance with those of Singh et al. (40) who reported similar clinical signs of toxicity in broiler chickens receiving CdCl₂ at 50 mg/L in drinking water. These clinical signs may be due to the immunosuppressant effect of Cd which subsequently increased the bird's susceptibility to stress and disease (40). Furthermore, our results showed a marked reduction in BWG, and an increase in the mortality rate in CdCl₂-treated ducks. Similarly, Erdogan et al. (41) reported a decline in BWG in broiler chickens receiving CdSO₄ at 25 mg/L

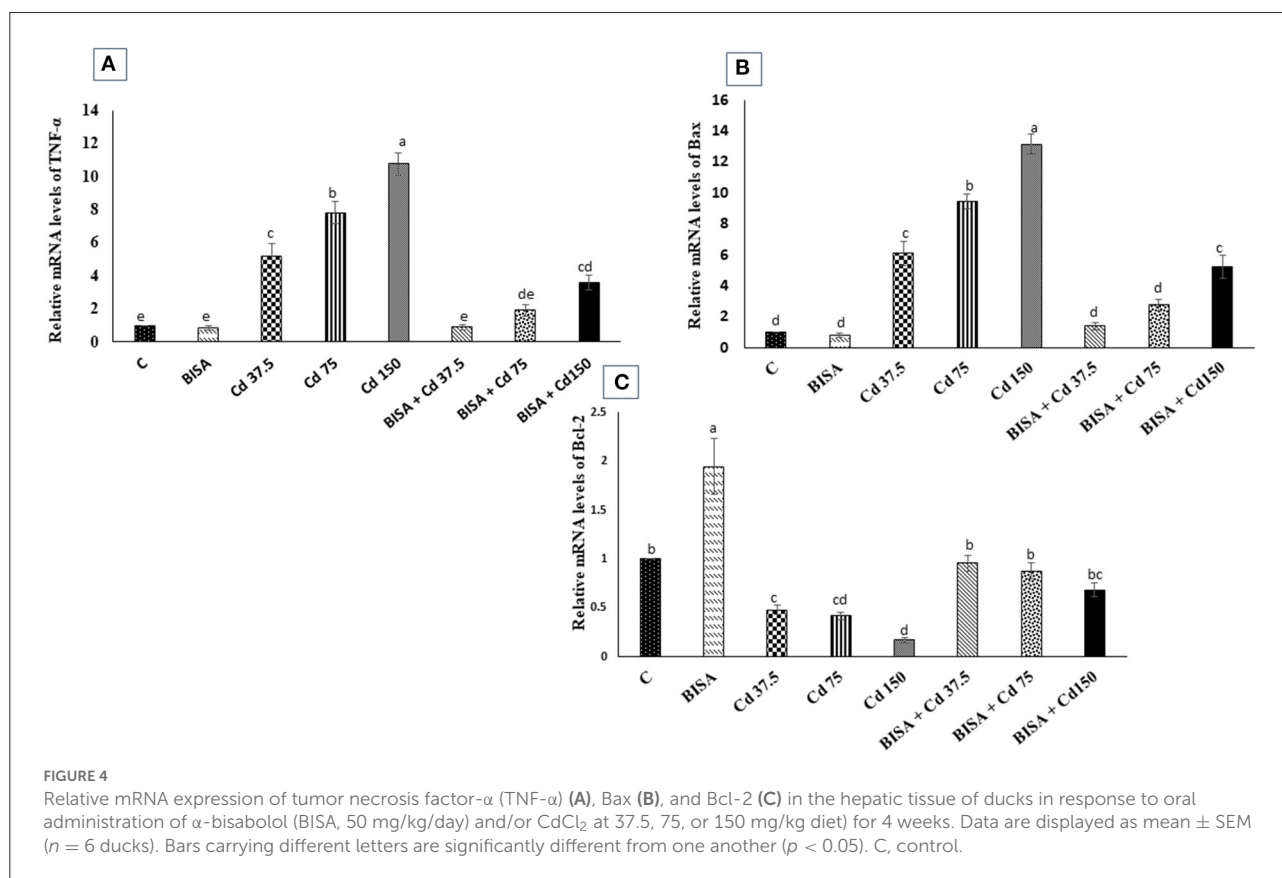
drinking water for 6 weeks. Also, Bharavi et al. (28) revealed a drastic drop in BWG in chickens receiving CdCl₂ at 100 mg/kg feed for 28 days. Moreover, our results showed that the exposure of ducks to CdCl₂ at 37.5 and 150 mg/kg feed for 4 weeks caused marked hepatic injury as witnessed by elevated serum ALT activity and bilirubin level. These findings were consistent with those of Renugadevi and Prabu (42) who reported an elevation in the serum ALT activity and total bilirubin level in rats receiving CdCl₂ orally at 5 mg/kg bw/day for 4 weeks.

In the present study, the histopathological investigation of hepatic sections collected from ducks receiving CdCl₂ at these doses manifested the Cd-induced hepatic damage by showing hydropic degeneration in hepatic cells, occluded sinusoids, congested central veins, and perivascular fibrosis. These structural changes were consistent with those of Li et al. (43) who reported inflammatory cell infiltration, hepatocyte degeneration, and necrosis in the liver of chickens receiving CdCl₂ in the diet at 140 mg/kg for 60 days. Similarly, ballooning degeneration, coagulative necrosis, and cytoplasmic vacuolation were detected in the liver of chickens treated

TABLE 4 Effect of α -bisabolol on hepatic tissue oxidative stress markers in ducks receiving CdCl₂ in feed for 4 weeks.

Experimental groups	Parameters			
	MDA level (nmol/g tissue)	SOD activity (U/g tissue)	CAT activity (U/g tissue)	GSH content (mg/g tissue)
C	28.40 ± 2.02 ^d	45.30 ± 3.34 ^{ab}	2.70 ± 0.17 ^a	24.48 ± 1.80 ^{ab}
BISA	26.75 ± 1.47 ^d	51.50 ± 2.79 ^a	2.85 ± 0.18 ^a	26.18 ± 1.59 ^a
Cd 37.5	45.97 ± 2.88 ^{bc}	31.47 ± 1.50 ^{cd}	1.6 ± 0.15 ^c	16.40 ± 1.46 ^{cd}
Cd 75	57.20 ± 4.98 ^b	25.15 ± 1.45 ^d	1.27 ± 0.09 ^c	12.05 ± 1.14 ^d
Cd 150	76.30 ± 3.68 ^a	14.53 ± 1.39 ^e	0.56 ± 0.07 ^d	7.35 ± 0.93 ^e
BISA + Cd 37.5	31.00 ± 2.29 ^d	42.75 ± 2.15 ^{ab}	2.40 ± 0.13 ^a	21.68 ± 1.65 ^{ab}
BISA + Cd 75	34.85 ± 2.55 ^{cd}	39.80 ± 1.62 ^{bc}	2.28 ± 0.11 ^{ab}	19.28 ± 1.04 ^{bc}
BISA + Cd 150	38.10 ± 2.75 ^{cd}	29.12 ± 3.12 ^d	1.70 ± 0.22 ^{bc}	13.86 ± 1.08 ^{cd}

Data are expressed as the mean ± SEM (n = 6). ^{a–e}Different superscripts within each column (in each parameter) represent significant differences (p < 0.05). C, control; BISA; α -bisabolol; Cd 37.5, Cd 75, Cd150; CdCl₂ was administered at 37.5, 75, and 150 mg/kg feed, respectively, for 4 weeks; MDA, malondialdehyde; SOD, superoxide dismutase; CAT, catalase; GSH, reduced glutathione.



with CdCl₂ at 150 mg/kg diet for 60 days (27). Moreover, Koyu et al. (44) reported that CdCl₂, even in small amount (15 mg/L of drinking water for 30 days) in rats, caused marked pathological alterations in hepatic tissues. In the present duck study, co-administration of BISA with CdCl₂ enhanced BWG, increased survival rate, restored the normal levels of serum hepatic indices and alleviated the histopathological

damage induced by CdCl₂. Our results were consistent with those of Amaral et al. (45) who reported that BISA ameliorated the hepatic injury induced by acetaminophen in mice. Other sesquiterpenoids, e.g., β -caryophyllene and Rutaecarpine, have a protective effect against the hepatic damage caused by carbon tetrachloride and thioacetamide, respectively (46, 47).

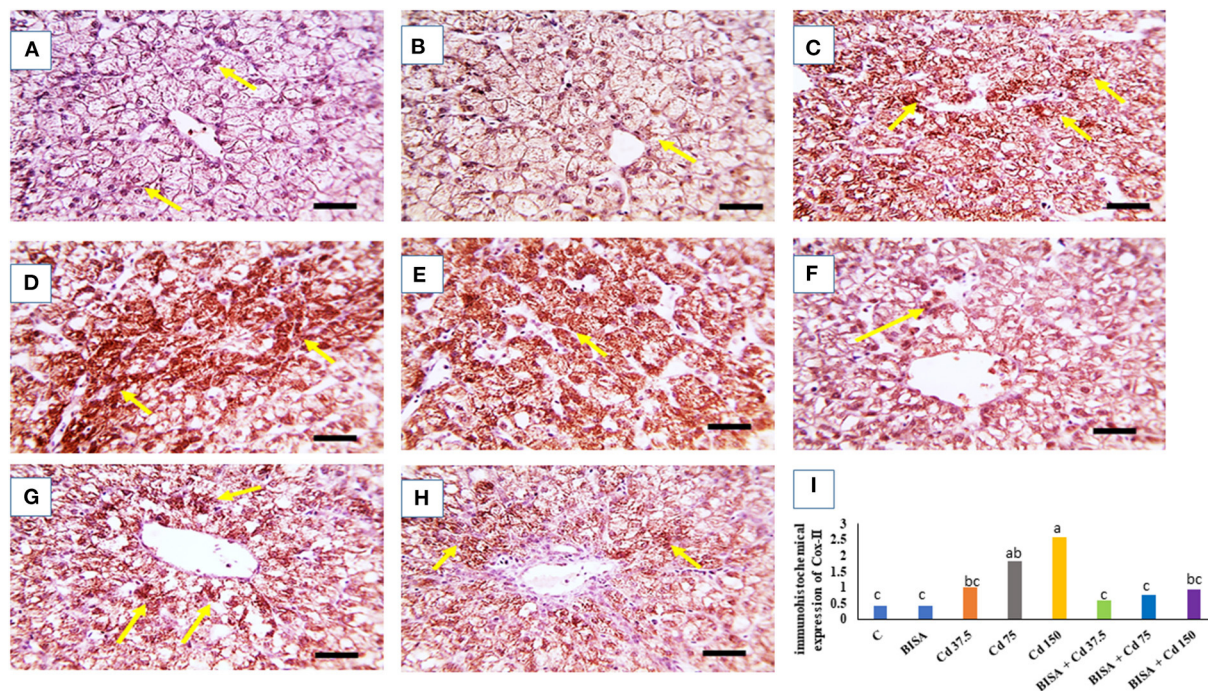


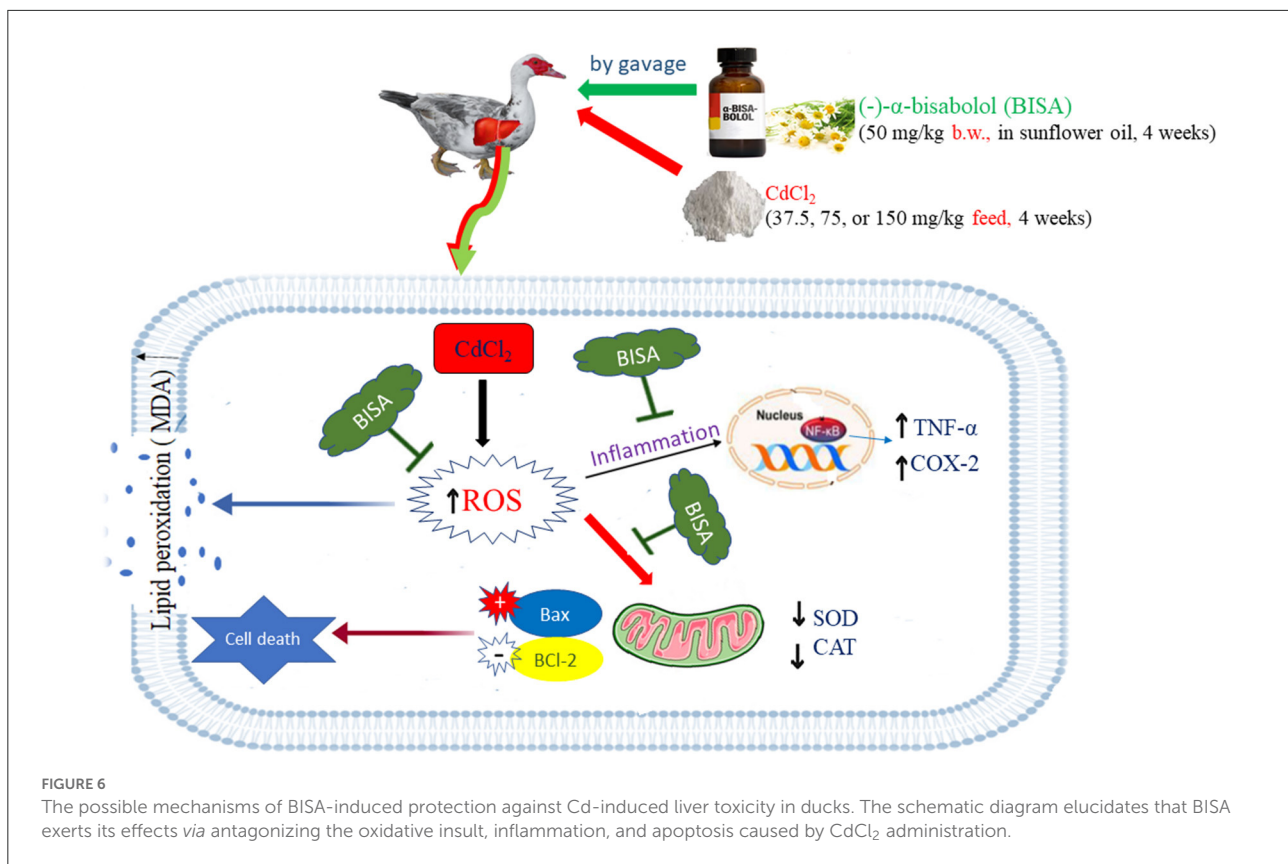
FIGURE 5

Quantitative data of COX-2 immunohistochemical staining intensity in the duck liver. (A) Expresses the control group (C) and (B) represents the bisabolol (BISA) alone group; both panels show very mild COX-2 brown staining in hepatocytes. (C–E) Are for groups receiving CdCl₂ at 37.5, 75, and 150 mg/kg diet, respectively, showing a dose-dependent increase in the brown staining. (F–H) Represent BISA + Cd 37.5, BISA + Cd 75, and BISA + Cd 150 groups, respectively, and display a marked decline of COX-2-staining, compared to the corresponding CdCl₂ alone groups. (I) Shows the quantitative data of COX-2 staining in hepatic tissues for the experimental groups. Quantitative data are expressed as mean ± SEM (*n* = 6). Bars carrying different letters are significantly different from one another (*p* < 0.05). The Image J software (National Institutes of Health, Bethesda, MD, USA) was used to quantify the intensities of immunostaining. Scale bar = 50 μm.

Oxidative stress is the main mechanism underlying the hepatic injury caused by Cd (9). The present study ascertained the capability of Cd to disturb the oxidant-antioxidant balance, evidenced by the increased MDA level, and reduced the antioxidant activities of SOD and CAT and the content of GSH in hepatic tissues of ducks. MDA is the main metabolite of lipid peroxidation, which indicates the extent of oxidative damage (48). While, SOD and CAT represent the first line defense antioxidants which play a central role in scavenging free radicals (49). In addition, a sulfhydryl peptide, is widely distributed in all cellular systems. It participates in the battle against the oxidative insult either by acting as a non-enzymatic antioxidant through direct interaction of its sulfhydryl group with ROS or by acting as a cofactor in the enzymatic detoxification reactions (42). Zhang et al. (50) revealed that Cd has the ability to interact with sulfhydryl (-SH) groups of ROS quenching molecules such as glutathione-SH which ultimately causes indirect elevation of ROS and oxidant-antioxidant imbalance. Our findings were in concordance with those of prior studies (43, 51, 52). In contrast, administration of BISA to CdCl₂-poisoned ducks showed marked reduction in MDA level and elevation in the activities of SOD, GSH and CAT. Our findings suggested that BISA

decrease the liberation of free radicals and restrain oxidative stress. Corroborating with our findings, several authors have reported the antioxidant activity of BISA (15, 19). Additionally, Vinholes et al. (53) attributed the hepatoprotective effect of sesquiterpenoids, including BISA to their lipophilic and polar characteristics which enhance membrane stability and suppress lipid peroxidation. Furthermore, terpenoids enhancing the activity of SOD, consequently increasing the elimination of free radicals (54).

Cd not only upsets the antioxidant system but also induces inflammatory response (55, 56). Inflammation is regarded as a substantial sequel for oxidative stress (57). As Cd promotes oxidative stress and excessive formation of ROS in the liver, nuclear factor-kappa B (NF-κB) separates from its inhibitory kappa B (IκBα) which enhances the generation of proinflammatory cytokines (56). In this context, Cd-induced hepatic damage is accompanied by the increased production of inflammatory mediators (TNF-α, IL-6, IL-1β) (43). The present work showed a remarkable upregulation of mRNA of TNF-α in hepatic tissues of ducks treated with CdCl₂. Moreover, the immunohistochemical screening displayed high COX-2 expression in the liver of CdCl₂-intoxicated ducks. COX-2 is



an enzyme which is activated by proinflammatory cytokines and serves as a principal contributor to prostanoid synthesis as inflammation proceeds (58). In agreement with our findings, Sanjeev et al. (59) demonstrated a marked increase in the expression of COX-2 in hepatic tissues of rats injected with CdCl₂ subcutaneously at 10 mg/kg/day for 30 days. In addition, we found that BISA displayed antiinflammatory effects by lowering the mRNA level of TNF- α and the expression of COX-2 in hepatic tissues of ducks. These findings were parallel to those of Barreto et al. (16) who reported marked antiinflammatory activity of BISA against carrageenan-induced pleurisy through reducing the production of TNF- α and the migration of leukocytes to the peritoneal cavity. Similarly, Kim et al. (60) demonstrated that BISA ameliorated the inflammation caused by lipopolysaccharide in RAW264.7 macrophages *via* decreasing the expression of COX-2 and inducible nitric oxide synthase.

Apoptosis is another adverse consequence of oxidative stress; it is needed for cellular turnover and homeostasis (61). Previous studies have denoted that Cd could promote apoptosis by provoking the mitochondrial pathway (52). Liu et al. (62) reported that Cd caused leakage in the mitochondrial membrane, inducing translocation of cytochrome C and apoptosis-inducing factors into the cytosol, leading to caspase cascade and eventually apoptosis. Cd-induced oxidative insult plays a prominent role in its ability to cause apoptosis (63). In the present study, CdCl₂ intoxication with 3 different dose

regimens resulted in significant upregulation of pro-apoptotic gene Bax and downregulation of anti-apoptotic gene Bcl-2 in the liver of ducks. Bax and Bcl-2 are components of Bcl-2 family, responsible for the regulation of the mitochondria-based apoptotic pathway (64). Our findings were consistent with those of prior studies which demonstrated the occurrence of apoptosis in hepatic tissues of chickens intoxicated with Cd (27, 52). In addition, Habeebu et al. (65) reported a dose-dependent apoptosis in the liver of mice exposed to Cd. Furthermore, Cd has been shown to increase the mRNA level of Bax and reduce the mRNA level of Bcl-2 in chicken testis (55).

In the present study, we found that BISA antagonized Cd-induced apoptosis as evidenced by downregulating Bax and upregulating Bcl-2 genes expression in hepatic tissues of ducks. Similarly, Shanmuganathan et al. (66) demonstrated the anti-apoptotic effect of BISA against amyloid- β -induced neurotoxicity in PC12 cells.

In the present study, we found that oral administration of CdCl₂ for 4 weeks increased the hepatic content of Cd. CdCl₂ supplementation to the diet of birds (ducks, broilers, cocks, and hens) causes an increase of Cd content in the liver (67, 68). In our study, concurrent administration of BISA with CdCl₂ dramatically reduced Cd content of the liver in ducks. This effect is probably due to reduction in the active transport of Cd in the gastrointestinal tract (GIT) mucosa or an increase in the excretion of Cd from the GIT or kidneys. Further studies

are warranted to investigate the mechanism by which BISA decreases the hepatic Cd content.

Conclusion

This study verified the dose-dependent hepatotoxic effect of CdCl₂ at 3 doses (37.5, 75, and 150 mg/kg diet) for 4 weeks in ducks. BISA conferred the protection against hepatotoxicity induced by CdCl₂ through reducing the hepatic content of Cd as well as antagonizing oxidative insults, inflammation, and apoptosis. BISA even decreased Cd-induced mortality. Future studies are warranted to gain deeper insight into the molecular mechanisms underlying the antagonistic effect of BISA on Cd-induced hepatic damage. Nonetheless, BISA exerts a great potential to be used as an antidote in the control of Cd poisoning. The proposed mechanisms of BISA in antagonizing CdCl₂-induced hepatic injury in ducks are presented in Figure 6.

Data availability statement

The original contributions presented in the study are included in the article/Supplementary materials, further inquiries can be directed to the corresponding author.

Ethics statement

The animal study was reviewed and approved by Medical Research Ethics Committee of the Faculty of Veterinary Medicine, Mansoura University, Mansoura, Egypt.

Author contributions

SE: methodology, data curation, and writing the original draft of the manuscript. WH: conceptualization, data curation

References

- Hirano S, Suzuki KT. Exposure, metabolism, and toxicity of rare earths and related compounds. *Environ Health Perspect.* (1996) 104 (Suppl. 1):85–95. doi: 10.1289/ehp.96104s185
- Hossein-Khannazer N, Azizi G, Eslami S, Alhassan Mohammed H, Fayyaz F, Hosseinzadeh R, et al. The effects of cadmium exposure in the induction of inflammation. *Immunopharmacol Immunotoxicol.* (2020) 42:1–8. doi: 10.1080/08923973.2019.1697284
- Wang Z, Sun Y, Yao W, Ba Q, Wang H. Effects of cadmium exposure on the immune system and immunoregulation. *Front Immunol.* (2021) 12:695484. doi: 10.3389/fimmu.2021.695484
- Chen M, Li X, Fan R, Yang J, Jin X, Hamid S, et al. Cadmium induces BNIP3-dependent autophagy in chicken spleen by modulating miR-33-AMPK axis. *Chemosphere.* (2018) 194:396–402. doi: 10.1016/j.chemosphere.2017.12.026

review, and editing the manuscript. All authors have read and approved the final manuscript.

Acknowledgments

The authors thank Dr. Ahmed Erfan for his assistance in gene expression analysis and Mr. Ahmed Abbas for his assistance in duck experiment. Also, we appreciate the assistance of the staff members of the Pathology Unit, Faculty of Veterinary Medicine, Mansoura University, Mansoura, Egypt in histopathological and immunohistochemical examination.

Conflict of interest

The authors declare that the research was conducted in the absence of any commercial or financial relationships that could be construed as a potential conflict of interest.

Publisher's note

All claims expressed in this article are solely those of the authors and do not necessarily represent those of their affiliated organizations, or those of the publisher, the editors and the reviewers. Any product that may be evaluated in this article, or claim that may be made by its manufacturer, is not guaranteed or endorsed by the publisher.

Supplementary material

The Supplementary Material for this article can be found online at: <https://www.frontiersin.org/articles/10.3389/fvets.2022.1024549/full#supplementary-material>

- Limei Z, Xiaoyong L, Tongbin C, Xiulan YAN, Hua XIE, Bin WU, et al. Regional assessment of cadmium pollution in agricultural lands and the potential health risk related to intensive mining activities: a case study in Chenzhou City. *China J Environ Sci.* (2008) 20:696–703. doi: 10.1016/S1001-0742(08)62115-4
- Chomchan R, Siripongyutikorn S, Maliyam P, Saibandith B, Puttarak P. Protective effect of Selenium-enriched rice grass juice against Cadmium-Induced toxicity and DNA damage in HEK293 kidney cells. *Foods.* (2018) 7:81–95. doi: 10.3390/foods7060081
- Cai J, Zhang Y, Yang J, Liu Q, Zhao R, Hamid S, et al. Antagonistic effects of selenium against necroptosis injury via adiponectin-necrotic pathway induced by cadmium in heart of chicken. *RSC Adv.* (2017) 7:44438–46. doi: 10.1039/C7RA07952D
- Branca JJ, Fiorillo C, Carrino D, Paternostro F, Taddei N, Gulisano M, et al. Cadmium-induced oxidative stress: focus on the central nervous system. *Antioxidants.* (2020) 9:492–513. doi: 10.3390/antiox9060492

9. Liu J, Qian SY, Guo Q, Jiang J, Waalkes MP, Mason RP, et al. Cadmium generates reactive oxygen- and carbon-centered radical species in rats: insights from *in vivo* spin-trapping studies. *Free Rad Biol Med.* (2008) 45:475–81. doi: 10.1016/j.freeradbiomed.2008.04.041
10. Stohs SJ, Bagchi D, Hassoun E, Bagchi M. Oxidative mechanisms in the toxicity of chromium and cadmium ions. *J Environmen Pathol Toxicol Oncol.* (2001) 20:77–88. doi: 10.1615/JEnvironPatholToxicolOncol.v20.i2.10
11. Shaikh ZA, Vu TT, Zaman TTK. Oxidative stress as a mechanism of chronic cadmium-induced hepatotoxicity and renal toxicity and protection by antioxidants. *Toxicol Appl Pharmacol.* (1999) 154:256–63. doi: 10.1006/taap.1998.8586
12. Park J, Han F, Lee IS. Biotransformation of (-)- α -Bisabolol by *Absidia coerulea*. *Molecules.* (2022) 27:881. doi: 10.3390/molecules27030881
13. Jakovlev V, Isaac O, Thiemer K, Kunde R. Pharmacological investigations with compounds of chamomile ii. new investigations on the antiphlogistic effects of (-)- α -bisabolol and bisabolol oxides (author's transl). *Planta Med.* (1979) 35:125–40. doi: 10.1055/s-0028-1097194
14. de Sousa Oliveira F, de Freitas TS, da Cruz RP, do Socorro Costa M, Pereira RLS, Quintans-Júnior LJ, et al. Evaluation of the antibacterial and modulatory potential of α -bisabolol, β -cyclodextrin and α -bisabolol/ β -cyclodextrin complex. *Biomed Pharmacother.* (2017) 92:1111–8. doi: 10.1016/j.biopha.2017.06.020
15. Kamatou GP, Viljoen AM. A review of the application and pharmacological properties of α -Bisabolol and α -Bisabolol-rich oils. *J Am Oil Chem Soc.* (2010) 87:1–7. doi: 10.1007/s11746-009-1483-3
16. Barreto RS, Quintans JS, Amarante RK, Nascimento TS, Amarante RS, Barreto AS, et al. Evidence for the involvement of TNF- α and IL-1 β in the antinociceptive and anti-inflammatory activity of *Stachys lavandulifolia* Vahl. (Lamiaceae) essential oil and (-)- α -bisabolol, its main compound, in mice. *J Ethnopharmacol.* (2016) 191:9–18. doi: 10.1016/j.jep.2016.06.022
17. Murata Y, Kokuryo T, Yokoyama Y, Yamaguchi J, Miwa T, Shibuya M, et al. The anticancer effects of novel α -bisabolol derivatives against pancreatic cancer. *Anticancer Res.* (2017) 37:589–98. doi: 10.21873/anticancer.11352
18. Gomes-Carneiro MR, Dias DM, De-Oliveira ACX, Paumgarten FJ. Evaluation of mutagenic and antimutagenic activities of α -bisabolol in the Salmonella/microsome assay. *Mutat Res Genet Toxicol Environ Mutagen.* (2005) 585:105–12. doi: 10.1016/j.mrgentox.2005.04.007
19. Meeran MFN, Laham F, Al-Tae H, Azimullah S, Ojha S. Protective effects of α -bisabolol on altered hemodynamics, lipid peroxidation, and nonenzymatic antioxidants in isoproterenol-induced myocardial infarction: *in vivo* and *in vitro* evidences. *J Biochem Mol Toxicol.* (2018) 32:e22200. doi: 10.1002/jbt.22200
20. Leite GDO, Ecker A, Seeger RL, Krum BN, Lugokenski TH, Fachinetto R, et al. Protective effect of (-)- α -bisabolol on rotenone-induced toxicity in *Drosophila melanogaster*. *Can J Physiol Pharmacol.* (2018) 96:359–65. doi: 10.1139/cjpp-2017-0207
21. Sampaio TL, da Costa MFB, Meneses GC, Arrieta MCV, Chaves Filho AJM, de Moraes GB, et al. Nephroprotective effects of (-)- α -bisabolol against ischemic-reperfusion acute kidney injury. *Phytomedicine.* (2016) 23:1843–52. doi: 10.1016/j.phymed.2016.11.008
22. Lusimbo WS, Leighton FA, Wobeser GA. Histology and ultrastructure of the chorioallantoic membrane of the mallard duck (*Anas platyrhynchos*). *Anat Rec.* (2000) 259:25–34. doi: 10.1002/(SICI)1097-0185(20000501)259:1<25::AID-AR3>3.0.CO;2-Y
23. Moraes LH, Lima MM, Martynhak BJ, Santiago R, Takahashi TT, Ariza D, et al. Characterization of motor, depressive-like and neurochemical alterations induced by a short-term rotenone administration. *Pharmacol Rep.* (2012) 64:1081–90. doi: 10.1016/S1734-1140(12)70905-2
24. Javed H, Meeran MF, Azimullah S, Bader Eddin L, Dwivedi VD, Jha NK, et al. α -Bisabolol, a dietary bioactive phytochemical attenuates dopaminergic neurodegeneration through modulation of oxidative stress, neuroinflammation and apoptosis in rotenone-induced rat model of Parkinson's disease. *Biomolecules.* (2020) 10:1421. doi: 10.3390/biom10101421
25. Fernandes MYD, do Carmo MRS, Fonteles AA, de Sousa Neves JC, da Silva ATA, Pereira JF, et al. (-)- α -bisabolol prevents neuronal damage memory deficits through reduction of proinflammatory markers induced by permanent focal cerebral ischemia in mice. *Eur J Pharmacol.* (2019) 842:270–80. doi: 10.1016/j.ejphar.2018.09.036
26. Subhan F, Khan A, Wahid F, Shehzad A, Jan AU. Determination of optimal toxic concentration and accumulation of cadmium in broiler chicks. *Toxicol Res.* (2011) 27:143–7. doi: 10.5487/TR.2011.27.3.143
27. Li JL, Jiang CY, Li S, Xu SW. Cadmium induced hepatotoxicity in chickens (*Gallus domesticus*) and ameliorative effect by selenium. *Ecotoxicol Environ Safety.* (2013) 96:103–9. doi: 10.1016/j.ecoenv.2013.07.007
28. Bharavi K, Reddy AG, Rao GS, Reddy AR, Rao SR. Reversal of cadmium-induced oxidative stress in chicken by herbal adaptogens *Withania somnifera* and *Ocimum sanctum*. *Toxicol Int.* (2010) 17:59–63. doi: 10.4103/0971-6580.72671
29. Ohkawa H, Ohishi N, Yagi K. Assay for lipid peroxides in animal tissues by thiobarbituric acid reaction. *Anal Biochem.* (1979) 95:351–8. doi: 10.1016/0003-2697(79)90738-3
30. Aebi H. Catalase *in vitro*. *Methods Enzymol.* (1984) 105:121–6. doi: 10.1016/S0076-6879(84)05016-3
31. Minami M, Yoshikawa H. A simplified assay method of superoxide dismutase activity for clinical use. *Clin Chim Acta.* (1979) 92:337–42. doi: 10.1016/0009-8981(79)90211-0
32. Paglia DE, Valentine WN. Studies on the quantitative and qualitative characterization of erythrocyte glutathione peroxidase. *J Lab Clin Med.* (1967) 70:158–69.
33. AOAC. *Official Methods of Analysis of the Association of Official Analytical Chemists.* 15th ed., Vol. 2. Washington, DC: Association of Official Analytical Chemistry (1990).
34. Liu F, Wang Y, Zhou X, Liu M, Jin S, Shan A, et al. Resveratrol relieved acute liver damage in ducks (*Anas platyrhynchos*) induced by AFB1 via modulation of apoptosis and Nrf2 signaling pathways. *Animals.* (2021) 11:3516. doi: 10.3390/ani11123516
35. Yuan JS, Reed A, Chen F, Stewart CN. Statistical analysis of real-time PCR data. *BMC Bioinform.* (2006) 7:1–12. doi: 10.1186/1471-2105-7-85
36. Bancroft JD, Layton C. Connective and mesenchymal tissues with their stains. In: *Bancroft's Theory and Practice of Histological Techniques.* Oxford: Churchill Livingstone; Elsevier (2012). p. 187–214.
37. Gibson-Corley KN, Olivier AK, Meyerholz DK. Principles for valid histopathologic scoring in research. *Vet Pathol.* (2013) 50:1007–15. doi: 10.1177/0300985813485099
38. Lin F, Prichard J. *Handbook of Practical Immunohistochemistry: Frequently Asked Questions.* New York, NY: Springer (2015).
39. Vis AN, Kranse R, Nigg AL, Van der Kwast TH. Quantitative analysis of the decay of immunoreactivity in stored prostate needle biopsy sections. *Am J Clin Pathol.* (2000) 113:369–73. doi: 10.1309/CQWY-E3F6-9KDN-YV36
40. Singh R, Srivastava, AK, Gangwar NK, Giri DK, Singh R, et al. Pathology of sub-chronic cadmium and chlorpyrifos toxicity in broilers. *Indian J Vet Pathol.* (2016) 40:331–6. doi: 10.5958/0973-970X.2016.00076.6
41. Erdogan Z, Erdogan S, Celik S, Unlu A. Effects of ascorbic acid on cadmium-induced oxidative stress and performance of broilers. *Biol Trace Elem Res.* (2005) 104:19–31. doi: 10.1385/BTER:104:1:019
42. Renugadevi J, Prabu SM. Cadmium-induced hepatotoxicity in rats and the protective effect of naringenin. *Exp Toxicol Pathol.* (2010) 62:171–81. doi: 10.1016/j.etp.2009.03.010
43. Li T, Yu H, Song Y, Zhang R, Ge M. Protective effects of *Ganoderma triterpenoids* on cadmium-induced oxidative stress and inflammatory injury in chicken livers. *J Trace Elem Med Biol.* (2019) 52:118–25. doi: 10.1016/j.jtemb.2018.12.010
44. Koyu A, Gokcimen A, Ozguner F, Bayram DS, Kocak A. Evaluation of the effects of cadmium on rat liver. *Mol Cell Biochem.* (2006) 284:81–5. doi: 10.1007/s11010-005-9017-2
45. Amaral VD, Cardia GF, Rocha EM, Ribeiro RD, Comar JF, Martins JN, et al. Hepatoprotective effect of (-)- α -bisabolol in an experimental model of paracetamol-induced injury. *Res J Pharm Biol Chem Sci.* (2021) 12:15–29. doi: 10.33887/rjpbcs/2021.12.3.1
46. Calleja MA, Vieites JM, Montero-Meterdez T, Torres MI, Faus MJ, Gil A, et al. The antioxidant effect of β -caryophyllene protects rat liver from carbon tetrachloride-induced fibrosis by inhibiting hepatic stellate cell activation. *Br J Nutr.* (2013) 109:394–401. doi: 10.1017/S0007114512001298
47. Ahn H, Lee S, Nam KW, Mar W. Inhibitory effect of rutaecarpine on Thioacetamide (TAA)-induced hepatic fibrosis. *Nat Prod Sci.* (2014) 20:262–8.
48. Pathak N, Khandelwal S. Oxidative stress and apoptotic changes in murine splenocytes exposed to cadmium. *Toxicol.* (2006) 220:26–36. doi: 10.1016/j.tox.2005.11.027
49. Pineda J, Herrera A, Antonio MTMT. Comparison between hepatic and renal effects in rats treated with arsenic and/or antioxidants during gestation and lactation. *J Trace Elem Med Biol.* (2013) 27:236–41. doi: 10.1016/j.jtemb.2012.12.006
50. Zhang L, Li Q, Zheng G, Chen Y, Huang M, Zhang L, et al. Protective effect of *Lycium barbarum* polysaccharides against cadmium-induced testicular

toxicity in male mice. *Food Funct.* (2017) 8:2322–30. doi: 10.1039/C6FO01583B

51. Wang Y, Chen H, Chang W, Chen R, Xu S, Tao D. Protective effects of selenium yeast against cadmium-induced necroptosis via inhibition of oxidative stress and MAPK pathway in chicken liver. *Ecotoxicol Environ Safe.* (2020) 206:111329. doi: 10.1016/j.ecoenv.2020.111329

52. Shi J, Chang X, Zou H, Gu J, Yuan Y, Liu X, et al. Protective effects of α -lipoic acid and chlorogenic acid on cadmium-induced liver injury in three-yellow chickens. *Animals.* (2021) 11:1606. doi: 10.3390/ani11061606

53. Vinholes J, Rudnitskaya A, Gonçalves P, Martel F, Coimbra MA, Rocha SM. Hepatoprotection of sesquiterpenoide: a quantitative dtructure-activity relationship (QSAR) approach. *Food Chem.* (2014) 145:78–84. doi: 10.1016/j.foodchem.2013.09.039

54. Nunes RCA, Viana RS, MNeto NB. Atividade enzimática da superóxido dismutase em resposta aos fitorreguladores auxina e citocinina em *Gerbera* sp. *Comun Sci.* (2015) 6:83–89. doi: 10.1515/9780824856137-012

55. Wang H, Zhang R, Song Y, Li T, Ge M. Protective effect of ganoderma triterpenoids on cadmium-induced testicular toxicity in chickens. *Biol Trace Elem Res.* (2019) 187:281–90. doi: 10.1007/s12011-018-1364-4

56. Joardar S, Dewanjee S, Bhowmick S, Dua TK, Das S, Saha A, et al. Rosmarinic acid attenuates cadmium-induced nephrotoxicity via inhibition of oxidative stress, apoptosis, inflammation and fibrosis. *Int J Mol Sci.* (2019) 20:2027. doi: 10.3390/ijms20082027

57. Haddad JJ. Oxygen-sensitive proinflammatory cytokines, apoptosis signaling and redox-responsive transcription factors in development and pathophysiology. *Cytokines Cell Mol Ther.* (2002) 7:1–14. doi: 10.1080/13684730216401

58. Khan AA, Iadarola M, Yang HY, Dionne RA. Expression of COX-1 and COX-2 in a clinical model of acute inflammation. *J Pain.* (2007) 8:349–54. doi: 10.1016/j.jpain.2006.10.004

59. Sanjeev S., Bidanchi RM, Murthy MK, Gurusubramanian G, Roy VK. Influence of ferulic acid consumption in ameliorating the cadmium-induced liver and renal oxidative damage in rats. *Environ Sci Pollu Res.* (2019) 26:20631–53. doi: 10.1007/s11356-019-05420-7

60. Kim S, Jung E, Kim JH, Park Y, Lee J, Park D. Inhibitory effects of (-)- α -bisabolol on LPS-induced inflammatory response in RAW264. 7 macrophages. *Food Chem Toxicol.* (2011) 49:2580–5. doi: 10.1016/j.fct.2011.06.076

61. Kannan K, Jain SK. Oxidative stress and apoptosis. *Pathophysiology.* (2000) 7:153–63. doi: 10.1016/S0928-4680(00)00053-5

62. Liu X, Zhang Y, Wang Y, Yan Y, Wang J, Gu J, et al. Investigation of cadmium-induced apoptosis and the protective effect of N-acetylcysteine in BRL 3A cells. *Mol Med Rep.* (2016) 14:373–9. doi: 10.3892/mmr.2016.5218

63. Chang KC, Hsu CC, Liu SH, Su CC, Yen CC, Lee MJ, et al. Cadmium induces apoptosis in pancreatic β -cells through a mitochondria-dependent pathway: the role of oxidative stress-mediated c-Jun N-terminal kinase activation. *PLoS ONE.* (2013) 8:e54374. doi: 10.1371/journal.pone.0054374

64. Tsujimoto Y, Shimizu S. Bcl-2 family: life-or-death switch. *FEBS Lett.* (2000) 466:6–10. doi: 10.1016/S0014-5793(99)01761-5

65. Habeebu SS, Liu J, Klaassen CD. Cadmium-induced apoptosis in mouse liver. *Toxicol. Appl Pharmacol.* (1998) 149:203–9. doi: 10.1006/taap.1997.8334

66. Shanmuganathan B, Suryanarayanan V, Sathya S, Narenkumar M, Singh SK, Ruckmani K, et al. Anti-amyloidogenic and anti-apoptotic effect of α -bisabolol against A β induced neurotoxicity in PC12 cells. *Eur J Med Chem.* (2018) 143:1196–207. doi: 10.1016/j.ejmech.2017.10.017

67. Lucia M, Andre JM, Gonzalez P, Baudrimont M, Gontier K, Maury-Brachet R, et al. Impact of cadmium on aquatic bird *Cairina moschata*. *Biometals.* (2009) 22:843–53. doi: 10.1007/s10534-009-9232-5

68. Pappas AC, Zoidis E, Georgiou CA, Demiris N, Surai PF, Fegeros K. Influence of organic selenium supplementation on the accumulation of toxic and essential trace elements involved in the antioxidant system of chicken. *Food Addit Contam.* (2011) 28:446–54. doi: 10.1080/19440049.2010.549152

69. NRC. *Nutrient Requirements of Poultry*. Colombia, WA: National Academy Press (1994).