



OPEN ACCESS

EDITED BY

Huiwu Li,
Shanghai Ninth People's Hospital, China

REVIEWED BY

Chung-Hwan Chen,
Kaohsiung Medical University, Taiwan
Osvaldo Mazza,
Bambino Gesù Children's Hospital (IRCCS), Italy

*CORRESPONDENCE

Chen-Kun Liaw
chenkunliaw@tmu.edu.tw;
chenkunliaw@gmail.com

SPECIALTY SECTION

This article was submitted to Orthopedic Surgery, a section of the journal Frontiers in Surgery

RECEIVED 22 July 2022

ACCEPTED 20 September 2022

PUBLISHED 14 October 2022

CITATION

Chen C-K, Wu T-Y, Liao Y-C, Fuh C-S, Chen K-H, Weng P-W, Wang J-Y, Chen C-Y, Huang Y-M, Chen C-P, Chu Y-L, Yeh K-L, Yu C-H, Wu H-K, Lin W-P, Liou T-H, Wu M-S and Liaw C-K (2022) Mathematical model of distal radius orientation. *Front. Surg.* 9:1000404. doi: 10.3389/fsurg.2022.1000404

COPYRIGHT

© 2022 Chen, Wu, Liao, Fuh, Chen, Weng, Wang, Chen, Huang, Chen, Chu, Yeh, Yu, Wu, Lin, Liou, Wu and Liaw. This is an open-access article distributed under the terms of the [Creative Commons Attribution License \(CC BY\)](https://creativecommons.org/licenses/by/4.0/). The use, distribution or reproduction in other forums is permitted, provided the original author(s) and the copyright owner(s) are credited and that the original publication in this journal is cited, in accordance with accepted academic practice. No use, distribution or reproduction is permitted which does not comply with these terms.

Mathematical model of distal radius orientation

Cheng-Kuang Chen^{1,2}, Tai-Yin Wu^{3,4,5}, Yu-Ciao Liao⁶, Chiou-Shann Fuh⁶, Kuan-Hao Chen^{7,8}, Pei-Wei Weng^{7,8,9}, Jr-Yi Wang^{7,8}, Chih-Yu Chen^{7,8,9,10}, Yu-Min Huang^{7,8}, Chung-Pei Chen¹¹, Yo-Lun Chu^{1,2,12}, Kuei-Lin Yeh^{6,13,14}, Ching-Hsiao Yu^{15,16}, Hung-Kang Wu^{15,16,17}, Wei-Peng Lin^{16,18}, Tsan-Hon Liou¹⁹, Mai-Szu Wu²⁰ and Chen-Kun Liaw^{7,8,9,21*}

¹Department of Orthopedics, Shin Kong Wu Ho-Su Memorial Hospital, Taipei, Taiwan, ²Department of Biomedical Engineering, National Taiwan University, Taipei, Taiwan, ³Department of Family Medicine, Zhongxing Branch, Taipei City Hospital, Taipei, Taiwan, ⁴Institute of Epidemiology and Preventive Medicine, National Taiwan University, Taipei, Taiwan, ⁵General Education Center, University of Taipei, Taipei, Taiwan, ⁶Institute of Computer Science and Information Engineering, National Taiwan University, Taipei, Taiwan, ⁷Department of Orthopedics, School of Medicine, College of Medicine, Taipei Medical University, Taipei City, Taiwan, ⁸Department of Orthopedics, Shuang Ho Hospital, Taipei Medical University, New Taipei City, Taiwan, ⁹Graduate Institute of Biomedical Optomechatronics, College of Biomedical Engineering; Research Center of Biomedical Device, Taipei Medical University, Taipei City, Taiwan, ¹⁰International Ph.D. Program in Biomedical Engineering, College of Biomedical Engineering, Taipei Medical University, Taipei, Taiwan, ¹¹Department of Orthopedics, Cathay General Hospital, Taipei, Taiwan, ¹²School of Medicine, College of Medicine, Fu Jen Catholic University, New Taipei City, Taiwan, ¹³Department of Orthopaedics, Ditmanson Medical Foundation Chia-Yi Christian Hospital, Chia-Yi City, Taiwan, ¹⁴Department of Long-Term Care and Management, WuFeng University, Chiayi County, Taiwan, ¹⁵Department of Orthopaedic Surgery, Taoyuan General Hospital, Ministry of Health and Welfare, Taoyuan City, Taiwan, ¹⁶Department of Orthopaedic Surgery, National Taiwan University Hospital, Taipei City, Taiwan, ¹⁷Department of Nursing, Yuanpei University of Medical Technology, Hsinchu City, Taiwan, ¹⁸Department of Orthopedics, Postal Hospital, Taipei, Taiwan, ¹⁹Department of Physical Medicine and Rehabilitation, School of Medicine, College of Medicine, Taipei Medical University, Taipei City, Taiwan, ²⁰Division of Nephrology, School of Medicine, College of Medicine, Taipei Medical University, Taipei City, Taiwan, ²¹TMU Biodesign Center, Taipei Medical University, Taipei, Taiwan

Distal radius orientation is important in evaluating Colles' fracture. In most cases, the wrist was protected by a bandage, splint, or cast. Therefore, it was difficult for the radiology technician to take perfect anteroposterior and lateral view radiographs. In this study, we build a mathematical model and calculate the pronation angle needed to produce dorsal tilt, which is a volar tilt in a perfect lateral view radiograph. The formulas are all incorporated into Excel to facilitate usage.

KEYWORDS

distal radius volar tilt, distal radius inclination, supination, pronation, rotation matrix

Introduction

Reduction and the indications for the operation of Colles' fracture usually require the guidance of x-rays. These x-rays include wrist anteroposterior and lateral views evaluating volar (palmar) tilt and radial inclination (1–4). These two parameters are in fact three-dimensional. We see patients with dorsal tilt in some lateral view radiographs and volar tilt in others frequently.

Figure 1 showed a patient with normal anatomy. However, the lateral view showed dorsal tilt.

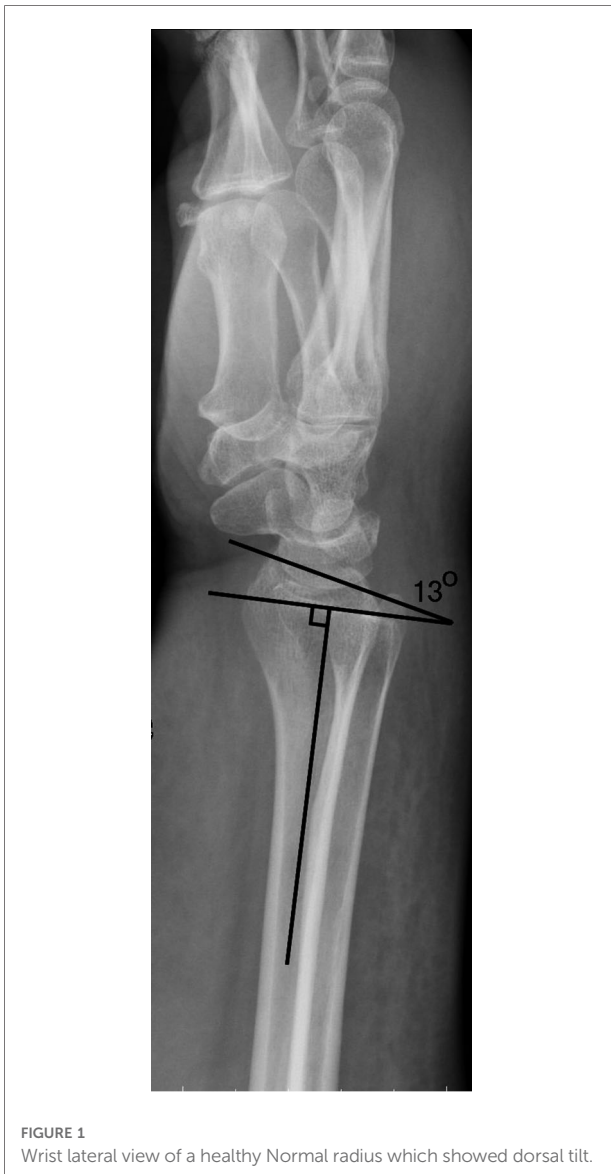

FIGURE 1 Wrist lateral view of a healthy Normal radius which showed dorsal tilt.

These findings raised some questions:

1. What is the mathematical model of distal radius?
2. When does the lateral view show dorsal tilt in normal distal radius?

Methods

The orientation of distal radius cartilage is three-dimensional. We must have a spatial concept when measuring it. Usually, it is presented by volar tilt and radial inclination. Using vector mathematics, we can present its orientation with a normal vector. First, we assume a 3D coordinate system.

The z-axis is aligned by the axis of the radial shaft and directed from the elbow toward the distal radius. The x-axis is directed from the ulnar side toward the radial side. The y-axis

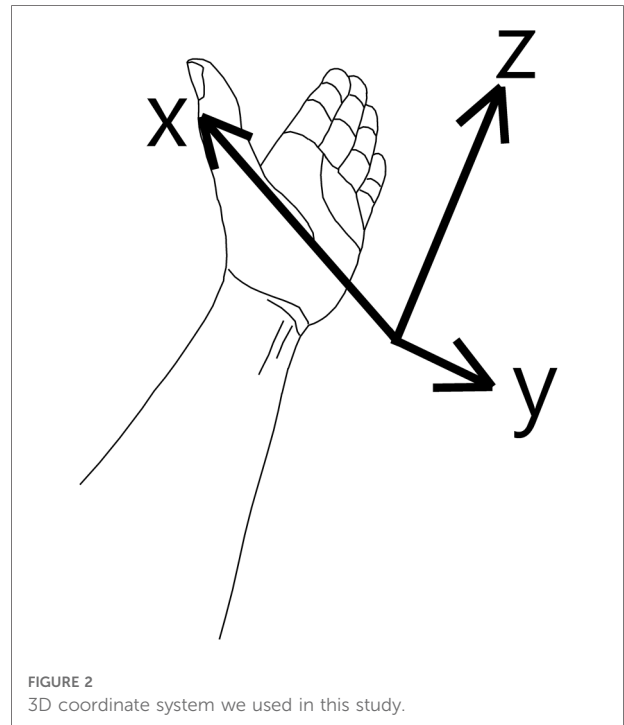


FIGURE 2 3D coordinate system we used in this study.

is from the dorsal toward the volar side (Figure 2). Volar tilt is θ . The inclination is φ .

Now we can get the distal radius orientation vector by trigonometric mathematics with the same principle (5).

Distal radius orientation normal vector (unit vector) = $(-\cos \theta \sin \varphi, \sin \theta \cos \varphi, \cos \theta \cos \varphi)$

In clinical practice, we usually take x-rays with some rotation around the z-axis, either supination or pronation. Thus, we use the rotation matrix to simulate this situation,

$$Rz(a) = \begin{bmatrix} \cos(a) & -\sin(a) & 0 \\ \sin(a) & \cos(a) & 0 \\ 0 & 0 & 1 \end{bmatrix}$$

where “a” = rotation around the z-axis or pronation angle. A positive value means pronation and negative means supination.

Thus, the normal vector after rotation “a” angle around the z-axis becomes the multiplication of the two matrixes,

$$\begin{bmatrix} \cos(a) & -\sin(a) & 0 \\ \sin(a) & \cos(a) & 0 \\ 0 & 0 & 1 \end{bmatrix} \begin{bmatrix} -\cos \theta \sin \varphi \\ \sin \theta \cos \varphi \\ \cos \theta \cos \varphi \end{bmatrix}$$

And the results after multiplication are

$$\begin{aligned} \text{Distal radius orientation normal vector (unit vector)} = \\ (-\cos \theta \sin \varphi \cos a - \sin \theta \cos \varphi \sin a, \\ -\cos \theta \sin \varphi \sin a + \sin \theta \cos \varphi \cos a, \cos \theta \cos \varphi) \end{aligned}$$

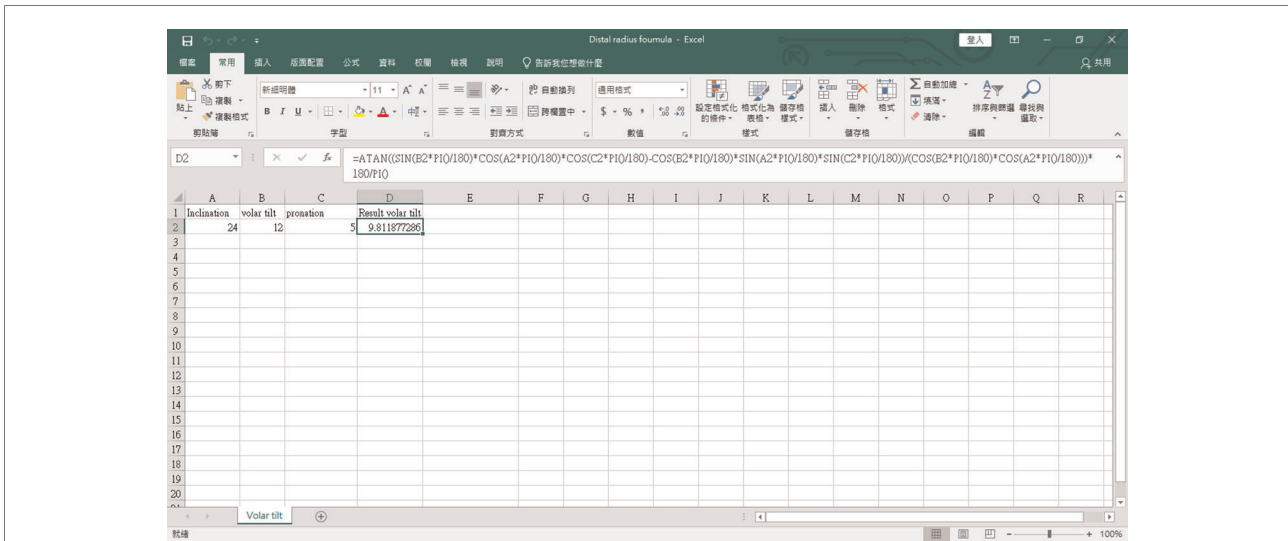


FIGURE 3
The excel program for the mathematical formula. The source code is as follows: “=ATAN((SIN(B2*PI()/180)*COS(A2*PI()/180)*COS(C2*PI()/180)-COS(B2*PI()/180)*SIN(A2*PI()/180)*SIN(C2*PI()/180))/(COS(B2*PI()/180)*COS(A2*PI()/180)))*180/PI()”. Readers can copy and paste the code directly.

After pronating rotation “a” angle, the volar tilt becomes

Volar tilt after pronating rotation “a”

$$= \tan^{-1} (\text{Y component on normal vector} / \text{Z component of the normal vector})$$

$$= \tan^{-1} ((-\cos \theta \sin \varphi \sin a + \sin \theta \cos \varphi \cos a) \cos \theta \cos \varphi).$$

This formula is incorporated into the Excel file (attachment file) (Figure 3.)

Because $\cos \theta \cos \varphi > 0$,

Thus if $(-\cos \theta \sin \varphi \sin a + \sin \theta \cos \varphi \cos a) > 0$, it is volar tilt;

if $(-\cos \theta \sin \varphi \sin a + \sin \theta \cos \varphi \cos a) < 0$, it is dorsal tilt.

Then, we get the following:

If $\tan \theta > \tan \varphi \tan a$, it is volar tilt;

if $\tan \theta < \tan \varphi \tan a$, it is dorsal tilt.

or

if $\tan a < \tan \theta \cot \varphi$, it is volar tilt;

if $\tan a > \tan \theta \cot \varphi$, it is dorsal tilt.

We then get the result as follows:

If pronation (a) $> \tan^{-1} \tan \theta \cot \varphi$, it changed from volar tilt to dorsal tilt. We incorporated it into excel. The excel file is attached.

We also incorporated the formula “pronation = $\tan^{-1} (\tan \theta \cot \varphi)$ ” into the Excel file (supplementary material).

If we input the normal parameters, inclination 24°, and volar tilt 12°, we get the result. It showed 25.5°, which means

if the patient pronates its wrist larger than 25.5°, the x-ray will show dorsal tilt.

Results and discussion

We considered the distal radius articular surface a plane and built a mathematical model of its normal vector. We used this model and calculated the pronation angle, 25.5°, needed to have dorsal tilt in normal patients.

Its clinical importance cannot be overlooked. In practice, Orthopedics doctors can have every radiograph in perfect projection. We should always keep in mind that the radiographs are in fact three-dimensional.

In Figure 1, there are two solid pieces of evidence of pronation. First, the radial styloid is moved toward the volar side. Second, the ulna is moved toward the dorsal side.

In clinical practice, excessive pronation on the lateral radiograph of the wrist usually happened during the postoperative examination while excessive bandage (with splint or cast) confused the radiology technician. The confusing results also perplexed the surgeon. Our results can solve this clinical problem.

Conclusions

We build a mathematical model for evaluating distal radius orientation and we found that the volar tilt will become dorsal

tilt if the pronation is larger than 25.5°. Further study may be needed to determine precision.

Data availability statement

The original contributions presented in the study are included in the article/[Supplementary Material](#), further inquiries can be directed to the corresponding author/s.

Ethics statement

The above study has been approved by expedited review process of the TMU-Joint Institutional Review Board (TMU-JIRB No: N202108038). Written informed consent for participation was not required for this study in accordance with national legislation and institutional requirements.

Author contributions

C-KL, T-YW, and Y-CL conceptualized the study. C-KL, P-WW, J-YW, C-YC, K-HC, and Y-MH helped acquired the funding. Y-CL derived the mathematics. C-SF, C-PC, Y-LC, C-KC, and K-LY wrote the algorithm. C-HY, H-KW, W-PL, T-HL, M-SW, and Y-MH simulated data and tested. C-KC, T-YW, and Y-CL wrote the paper. All authors contributed to the article and approved the submitted version.

References

1. Raittio L, Launonen AP, Hevonkorpi T, Luukkala T, Kukkonen J, Reito A, et al. Two casting methods compared in patients with Colles' fracture: a pragmatic, randomized controlled trial. *PLoS One*. (2020) 15(5):e0232153. doi: 10.1371/journal.pone.0232153
2. Reyes-Aldasoro CC, Ngan KH, Ananda A, d'Avila Garcez A, Appelboom A, Knapp KM. Geometric semi-automatic analysis of radiographs of Colles' fractures. *PLoS One*. (2020) 15(9):e0238926. doi: 10.1371/journal.pone.0238926
3. Yokota H, Yasui M, Hirai S, Hatayama N, Ohshima S, Nakano T, et al. Evaluation of the pressure on the dorsal surface of the distal radius using a

Funding

This work was funded by grants from the Taiwan Ministry of Science and Technology under grant number 109-2314-B-038 -029.

Conflict of interest

The authors declare that the research was conducted in the absence of any commercial or financial relationships that could be construed as a potential conflict of interest.

Publisher's note

All claims expressed in this article are solely those of the authors and do not necessarily represent those of their affiliated organizations, or those of the publisher, the editors and the reviewers. Any product that may be evaluated in this article, or claim that may be made by its manufacturer, is not guaranteed or endorsed by the publisher.

Supplementary material

The Supplementary Material for this article can be found online at: <https://www.frontiersin.org/articles/10.3389/fsurg.2022.1000404/full#supplementary-material>.

cadaveric and computational model: clinical considerations in intersection syndrome and Colles' fracture. *Anat Sci Int*. (2020) 95(1):38–46. doi: 10.1007/s12565-019-00491-5

4. Zenke Y, Furukawa K, Furukawa H, Maekawa K, Tajima T, Yamanaka Y, et al. Radiographic measurements as a predictor of correction loss in conservative treatment of Colles' fracture. *J Uoeh*. (2019) 41(2):139–44. doi: 10.7888/juoeh.41.139

5. Liaw C-K, Wu T-Y, Hou S-M, Yang R-S, Fuh C-S. How to evaluate three dimensional angle error from plain radiographs. *J Arthroplasty*. (2013) 28(10):1788–90. doi: 10.1016/j.arth.2013.05.023