



# Protective Effect of Nalbuphine Combined With Dexmedetomidine on the Lungs of Children With Atelectasis and Foreign Body in the Bronchus During the Perioperative Period

Yuan Wang<sup>1\*</sup>, Hong-Yang Han<sup>2</sup>, Ying-Ping Jia<sup>1</sup>, Li-Yuan Zhao<sup>1</sup>, Ying Li<sup>3</sup>, Bian-Jing Zuo<sup>4</sup> and Jie Zhang<sup>5</sup>

<sup>1</sup>Department of Anesthesiology, Children's Hospital Affiliated with Zhengzhou University, Zhengzhou, China, <sup>2</sup>Department of Radiology, Zhengzhou Central Hospital, Zhengzhou, China, <sup>3</sup>Department of Otolaryngological, Children's Hospital Affiliated with Zhengzhou University, Zhengzhou, China, <sup>4</sup>Department of Ultrasound, Children's Hospital Affiliated with Zhengzhou University, Zhengzhou, China, <sup>5</sup>Department of Anesthesiology, Zhengzhou University First Affiliated Hospital, Zhengzhou, China

## OPEN ACCESS

### Edited by:

Peter Markus Spieth,  
University Hospital Carl Gustav Carus,  
Germany

### Reviewed by:

Mediha Türktan,  
Cukurova University, Turkey  
Kefang Guo,  
Zhongshan Hospital, Fudan  
University, China  
Xinping Zhang,  
Hunan Children's Hospital, China

### \*Correspondence:

Yuan Wang  
wangyuan68954@sina.com

### Specialty section:

This article was submitted to  
Respiratory Physiology and  
Pathophysiology,  
a section of the journal  
Frontiers in Physiology

Received: 26 January 2022

Accepted: 24 March 2022

Published: 05 May 2022

### Citation:

Wang Y, Han H-Y, Jia Y-P, Zhao L-Y,  
Li Y, Zuo B-J and Zhang J (2022)  
Protective Effect of Nalbuphine  
Combined With Dexmedetomidine on  
the Lungs of Children With Atelectasis  
and Foreign Body in the Bronchus  
During the Perioperative Period.  
Front. Physiol. 13:799183.  
doi: 10.3389/fphys.2022.799183

**Objective:** The present study aims to explore the protective effect of nalbuphine combined with dexmedetomidine on the lungs of children with atelectasis who have a foreign body in a bronchus during the perioperative period.

**Methods:** A total of 180 patients whose computed tomography scan showed atelectasis and a foreign body in a bronchus were randomly divided into three groups: group C (conventional anesthesia group), group D (dexmedetomidine group), and group N + D (nalbuphine combined with the dexmedetomidine group). The following indicators were recorded: 1) heart rate (HR) and mean arterial pressure (MAP) prior to induction (T<sub>0</sub>), at bronchoscope placement (T<sub>1</sub>), at intubation after surgery (T<sub>2</sub>), at tube removal (T<sub>3</sub>), 10 min after tube removal (T<sub>4</sub>), 20 min after tube removal (T<sub>5</sub>), and at awaking (T<sub>6</sub>); 2) monocyte toll-like receptors (TLRs) TLR-2, TLR-4, tumor necrosis factor  $\alpha$ , interleukin 6, oxygenation index, and the B-line sum at T<sub>0</sub>, T<sub>3</sub>, 2 h (T<sub>7</sub>), and 24 h (T<sub>8</sub>) after tube removal; and 3) hospital stay after surgery.

**Results:** Compared with group C, in group D and group N + D, 1) the HR and MAP at T<sub>1</sub>~T<sub>6</sub> were lower; 2) the inflammatory factor indicator and B-line sum were lower, and the oxygenation index was higher at T<sub>7</sub> and T<sub>8</sub>; 3) the agitation and cough scores were decreased during tube removal; and 4) the Ramsay sedation score was higher, and ventilator weaning time was shortened at T<sub>4</sub>~T<sub>6</sub> ( $p < 0.05$ ). Compared with group D, in group N + D, 1) the inflammatory factor indicator and B-line sum were lower at T<sub>3</sub>; 2) the oxygenation index was higher ( $p < 0.05$ ). Compared with groups C and D, in group N + D, the length of hospital stay was decreased ( $p < 0.05$ ).

**Conclusion:** In patients with atelectasis and a foreign body in a bronchus during the perioperative period, nalbuphine combined with dexmedetomidine may be capable of reducing the oxidative stress response, improving the oxygenation index, decreasing the pulmonary fluid content, protecting the lung, and facilitating postoperative recovery.

**Keywords:** nalbuphine, dexmedetomidine, atelectasis, foreign body in the bronchus, child, lung protection

## INTRODUCTION

The presence of a foreign body in a bronchus is a common pediatric emergency, and mechanical obstruction by a large foreign body may result in atelectasis. In the process of removing the foreign body, reoxygenation after hypoxia caused by pulmonary re-expansion and stress stimulation in the perioperative period may aggravate the lung injury and affect the prognosis. According to relevant domestic and foreign reports, dexmedetomidine can inhibit sympathetic nerve activity and catecholamine release, reduce the synthesis and release of pro-inflammatory factors [e.g., tumor necrosis factor  $\alpha$  (TNF- $\alpha$ ) and interleukin 6 (IL-6)], inhibit the inflammatory response, improve lung function, and protect the lung (Giovannitti et al., 2015; Zhang, 2018; Quan, 2019). However, the inhibition of reoxygenation after hypoxia during lung re-expansion has not been reported.

Nalbuphine mainly activates  $\kappa$  opioid receptors and produces spinal analgesia (He et al., 2021). Because of its long duration and few adverse reactions, it can be used before operations (Xu et al., 2019) to effectively prevent anesthesia stimulation and central sensitization caused by operation trauma as well as reduce the intraoperative inflammatory response (Li et al., 2016).

Based on the preliminary results of the previous study, (Wang and Jia, 2015), the protective effect of nalbuphine preemptive analgesia combined with intraoperative dexmedetomidine on lung re-expansion in children with atelectasis after foreign body removal was explored. The exploration was conducted through the expression of monocyte toll-like receptors (TLRs), TLR2 and TLR4, in peripheral blood during the perioperative period, the influence of inflammatory factors (e.g., TNF- $\alpha$  and IL-6) and the oxygenation index, and the extravascular pulmonary fluid content assessment with a B-line sum (Picano and Pellikka, 2016).

## MATERIALS AND METHODS

The present prospective, randomized, controlled, and double-blind clinical study was approved by the Medical Ethics Committee of the Children's Hospital Affiliated with Zhengzhou University (2021-K-98). The family members of the children all signed the informed consent form.

## SUBJECT

From March 2, 2020, to March 31, 2021, a total of 180 children with atelectasis and a foreign body in a bronchus diagnosed *via* a computed tomography (CT) scan were enrolled in the present study. The patients underwent removal of the foreign body under rigid bronchoscopy; the patients were instructed to fast for 6 h before the operation and forbidden to drink water 2 h before the operation.

**Inclusion criteria:** children with CT-confirmed atelectasis and a history of foreign body inhalation in the last 2 weeks (foreign bodies: plant seeds such as peanuts or melon seeds).

**Exclusion criteria:** 1) children who experienced a failure to remove the foreign body during the operation or children in

whom a postoperative CT confirmed a failure to completely remove the foreign body; and 2) children with pulmonary consolidation, congenital heart disease, heart failure, respiratory failure, or cyanosis.

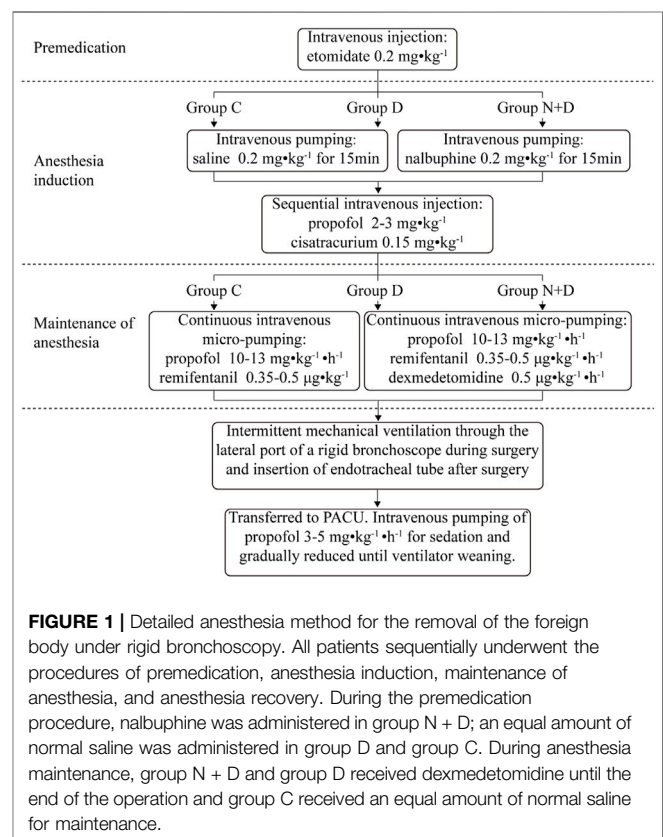
The patients were randomly divided into three groups according to the random number table: group C (the conventional anesthesia group), group D (the dexmedetomidine group), and group N + D (the nalbuphine combined with dexmedetomidine group) ( $n = 60$ , each).

## ANESTHESIA METHOD

All patients sequentially underwent the procedures of premedication, anesthesia induction, anesthesia maintenance, and anesthesia recovery. During the premedication procedure, group N + D received nalbuphine and group D and group C received an equal amount of normal saline. During anesthesia maintenance, group N + D and group D were administered with dexmedetomidine until the end of the operation, and group C was administered with an equal amount of normal saline for maintenance. The detailed procedures were as follows (Figure 1).

### Premedication

All the patients were slowly intravenously administered with etomidate  $0.2 \text{ mg kg}^{-1}$  and conveyed to the operating theatre after falling asleep.



## Anesthesia Induction

Nalbuphine 0.2 mg kg<sup>-1</sup> was diluted to 20 ml with normal saline, and intravenous pumping was completed within 15 min. Intravenous injection of propofol 2–3 mg kg<sup>-1</sup>, cisatracurium 0.15 mg kg<sup>-1</sup>, and remifentanyl 2–3 µg kg<sup>-1</sup> was performed for induction. After the value of Narcotrend decreased to D<sub>2</sub>, a rigid bronchoscope was placed, and a Primus anesthesia machine (Drüger, Germany) was connected for intermittent mechanical ventilation (controlling breathing during the microscopic examination and stopping breathing control during foreign body removal) in the pressure control mode through the side hole of the bronchoscope [FiO<sub>2</sub> 40–60%, flow 3 L min<sup>-1</sup>, RR 30–40 times•min<sup>-1</sup>, V<sub>T</sub> 8–10 ml kg<sup>-1</sup>, SpO<sub>2</sub> ≥ 95%, and PetCO<sub>2</sub> 35–45 mmHg (1 mmHg = 0.133 kPa)].

## Anesthesia Maintenance

The anesthesiologists in the present study were blind to the grouping. After anesthesia induction, 10 ml kg<sup>-1</sup> of compound electrolyte solution containing 1% glucose was injected intravenously into all children. Immediately, continuous intravenous micro-pumping of propofol 10–13 mg kg<sup>-1</sup>•h<sup>-1</sup> was performed during each operation in order to maintain the Narcotrend value at D<sub>2</sub>–E<sub>1</sub> and remifentanyl value at 0.35–0.5 µg kg<sup>-1</sup>•min<sup>-1</sup> until the end of the operation. Intravenous pumping of dexmedetomidine 0.5 µg kg<sup>-1</sup>•h<sup>-1</sup> was conducted until the end of the operation. After the operation, a tracheal tube was inserted, and the patient was transferred to the recovery room.

## Anesthesia Recovery

The Siemens (Maquet SERVO-i) ventilator was connected in the SIMV + PSV mode to control ventilation: a flow of 3 L min<sup>-1</sup>, FiO<sub>2</sub> of 60–40%, initial RR of 20–25 times•min<sup>-1</sup>, and V<sub>T</sub> of 8–10 ml kg<sup>-1</sup>. Intravenous pumping of propofol 3–5 mg kg<sup>-1</sup> was conducted for sedation and gradually reduced until ventilator weaning. The ventilator is adjusted until the following conditions are met: 1) suction support pressure < 10 cm H<sub>2</sub>O; 2) positive end-expiratory pressure (PEEP) < 5 cm H<sub>2</sub>O; and 3) FiO<sub>2</sub> < 50% (Sun et al., 2018).

The ventilator weaning test was conducted according to the spontaneous breathing trial (SBT) standard. In the case of a successful trial, a simple breathing bag was used for ventilation; in the case of an unsuccessful trial, the current ventilation mode was continued for 10 min, and then, SBT was conducted again until ventilator weaning.

After ventilator weaning, propofol pumping was stopped. After the swallowing reflex was recovered, spontaneous respiration was stable, air absorption could be maintained at SpO<sub>2</sub> ≥ 95%, the respiratory tract was fully cleared, and the tube was removed.

## Indicator Monitoring and Recording

1) Respiratory circulation indicators: heart rate (HR), mean arterial pressure (MAP), PetCO<sub>2</sub>, and SpO<sub>2</sub> were monitored during each operation. The HR and MAP were recorded at the following time points: prior to induction (T<sub>0</sub>), at bronchoscope placement (T<sub>1</sub>), at intubation after surgery (T<sub>2</sub>), at tube removal (T<sub>3</sub>), 10 min after tube removal (T<sub>4</sub>), 20 min after tube removal (T<sub>5</sub>), and at awaking (T<sub>6</sub>).

An HR and MAP of <30% of the sober-state HR and MAP were defined as bradycardia and hypotension. Atropine 0.01 mg kg<sup>-1</sup> and ephedrine 0.3 mg kg<sup>-1</sup>, respectively, were injected intravenously.

An HR and MAP of >30% of the sober-state HR and MAP were defined as tachycardia and hypertension. Remifentanyl 0.5–1 µg kg<sup>-1</sup> was injected intravenously, and the factors were recorded as adverse events in the circulatory system.

An SpO<sub>2</sub> of <90% was defined as hypoxemia. In such cases, it was necessary to increase the fraction of inspired oxygen and manually control positive pressure ventilation (*p* ≤ 30 cm H<sub>2</sub>O).

A PetCO<sub>2</sub> of >60 mmHg was defined as hypercapnia. In such cases, it was necessary to adjust respiration parameters and record the PetCO<sub>2</sub> as an adverse event in the respiratory system.

2) Collection and detection of inflammatory factors: a volume of 3 ml peripheral venous blood was collected in T<sub>0</sub>, T<sub>3</sub>, T<sub>7</sub>, and T<sub>8</sub>, respectively. The supernatant was taken after the blood was centrifuged for 20 min at 3,000 r/min, gathered in the EP tube, and kept in a –20°C refrigerator for centralized measurement in order to avoid repeated freezing and thawing.

The TNF-α, IL-6 (kit provided by eBioscience), TLR-2, and TLR-4 (kit manufactured by RayBiotech) were detected with double antibody sandwich ELISA by using the MICRO LAB FAME automatic enzyme immunity analyzer of HAMILTON. The optical density of the sample was obtained by colorimetric analysis, and the optical density values of the test sample were converted to the concentration values (TLR-2 and TLR-4: ng/ml; TNF-α and IL-6 pg/ml) according to the standard curve. The operation process was carried out in strict accordance with the reagent specifications.

3) Oxygenation index: blood samples from radial arteries were taken at T<sub>0</sub>, T<sub>3</sub>, T<sub>7</sub>, and T<sub>8</sub> for blood gas analysis, and the oxygenation index (PaO<sub>2</sub>/FiO<sub>2</sub>) was calculated.

4) Assessment of pulmonary fluid content by ultrasound B-line sum: the Sonosit M-Turbo portable color ultrasound machine was used to divide the lung into anterior, lateral, and posterior areas by using anterior and posterior axillary lines as the boundaries. Next, each lung was divided into upper and lower lung fields using the connection line between the two nipples, dividing the bilateral lung into 12 areas (Liu et al., 2019).

The B-line was measured using a high-frequency line array probe (6.5–7.5 MHz) through the bilateral chest wall in the supine position at T<sub>0</sub>, T<sub>3</sub>, T<sub>7</sub>, and T<sub>8</sub> (Picano and Pellikka, 2016). The B-line sum was counted.

5) Agitation scores: the agitation score at T<sub>3</sub> was recorded (0 points: quietness and cooperativeness; 1 point: mild agitation, body agitation during aspiration of sputum, and intermittent moaning; 2 points: agitation without stimulus, continuous moaning, and a necessity to fix the upper limbs; and 3 points: violent struggling and shouting and the necessity to press limbs by an external force). An agitation score of 0–1 points was considered satisfactory.

6) Sedation scores: the Ramsay sedation score at 10 min (T<sub>4</sub>) and 20 min (T<sub>5</sub>) after tube removal and at awakening (T<sub>6</sub>) was recorded (1 point: anxiety and agitation; 2 points: quietness and cooperativeness; 3 points: response only to command, light touch, and normal sound; 4 points: quick response after gently patting

**TABLE 1 |** Demographics of patients in each group ( $\bar{x} \pm s$ ).

	Group C	Group D	Group N + D	p value
Gender (male/female)	37/22	35/24	38/22	0.931
Age (months)	26 ± 16	25 ± 15	26 ± 15	0.772
Weight (kg)	14.9 ± 6.1	15.3 ± 5.6	14.7 ± 5.8	0.619
Time from onset to admission (days)	8.6 ± 4.2	8.3 ± 4.0	8.4 ± 3.9	0.796
Time from admission to operation (hours)	20.9 ± 11.6	20.2 ± 12.1	20.6 ± 11.9	0.823
Operation time (min)	21.2 ± 5.5	20.7 ± 6.3	22.1 ± 5.9	0.265

**TABLE 2 |** Cycle indicators at different time points in each group ( $\bar{x} \pm s$ ).

Group	Item	T <sub>0</sub>	T <sub>1</sub>	T <sub>2</sub>	T <sub>3</sub>	T <sub>4</sub>	T <sub>5</sub>	T <sub>6</sub>
C	HR (bpm)	116.6 ± 17.3	115.3 ± 16.9	109.2 ± 16.2	129.3 ± 14.9	125.3 ± 14.7	119.3 ± 14.4	127.3 ± 16.8
D		117.3 ± 16.5	94.7 ± 15.4 <sup>a</sup>	94.3 ± 14.8 <sup>a</sup>	93.2 ± 14.1 <sup>aa</sup>	96.3 ± 13.6 <sup>aa</sup>	94.3 ± 13.5 <sup>aa</sup>	98.3 ± 13.7 <sup>aa</sup>
N + D		116.5 ± 14.9	93.4 ± 15.1 <sup>a</sup>	93.2 ± 14.7 <sup>a</sup>	94.7 ± 14.1 <sup>aa</sup>	95.4 ± 13.5 <sup>aa</sup>	94.6 ± 13.6 <sup>aa</sup>	97.3 ± 13.9 <sup>aa</sup>
C	MAP (mmHg)	71.3 ± 4.3	77.7 ± 4.9	73.7 ± 4.7	87.5 ± 4.6	85.5 ± 4.4	84.5 ± 5.3	87.8 ± 4.6
D		70.9 ± 4.7	66.5 ± 5.4 <sup>a</sup>	59.8 ± 5.3 <sup>a</sup>	57.7 ± 4.6 <sup>aa</sup>	56.6 ± 4.4 <sup>aa</sup>	55.6 ± 4.6 <sup>aa</sup>	57.3 ± 4.4 <sup>aa</sup>
N + D		70.5 ± 4.0	65.7 ± 5.3 <sup>a</sup>	59.0 ± 5.0 <sup>a</sup>	56.7 ± 4.5 <sup>aa</sup>	55.7 ± 4.9 <sup>aa</sup>	55.0 ± 4.5 <sup>aa</sup>	56.8 ± 4.0 <sup>aa</sup>

<sup>a</sup>p < 0.05 compared with group C.<sup>b</sup>p < 0.01 compared with group C.**TABLE 3 |** Inflammatory factor, oxygenation index, and B-line sum indicator at different time points in each group ( $\bar{x} \pm s$ ).

Group	Item	T <sub>0</sub>	T <sub>3</sub>	T <sub>7</sub>	T <sub>8</sub>
C	TLR-2 (ng/ml)	0.239 ± 0.128	0.288 ± 0.186	2.193 ± 0.212	2.192 ± 0.138
D		0.232 ± 0.133	0.244 ± 0.181	1.024 ± 0.312 <sup>a</sup>	0.987 ± 0.156 <sup>a</sup>
N + D		0.213 ± 0.142	0.231 ± 0.197	0.945 ± 0.326 <sup>a</sup>	0.258 ± 0.136 <sup>aa,b</sup>
C	TLR-4 (ng/mL)	1.088 ± 0.113	1.155 ± 0.275	3.016 ± 0.339	3.005 ± 0.274
D		1.092 ± 0.133	1.160 ± 0.264	2.002 ± 0.327 <sup>a</sup>	1.824 ± 0.256 <sup>a</sup>
N + D		1.101 ± 0.126	1.183 ± 0.250	1.960 ± 0.369 <sup>a</sup>	1.220 ± 0.283 <sup>aa,b</sup>
C	TNF-α (pg/ml)	15.3 ± 4.3	16.3 ± 3.6	32.6 ± 4.5	36.3 ± 4.7
D		15.4 ± 3.9	16.6 ± 3.4	24.4 ± 4.6 <sup>a</sup>	30.3 ± 5.8 <sup>a</sup>
N + D		15.6 ± 3.7	16.3 ± 3.8	23.3 ± 4.4 <sup>a</sup>	16.6 ± 4.4 <sup>aa,b</sup>
C	IL-6 (pg/ml)	13.3 ± 3.3	14.6 ± 4.2	31.5 ± 8.7	33.3 ± 9.7
D		13.5 ± 3.9	14.8 ± 3.4	25.6 ± 6.4 <sup>a</sup>	23.3 ± 7.8 <sup>a</sup>
N + D		12.9 ± 4.2	13.9 ± 3.6	23.9 ± 7.3 <sup>a</sup>	14.2 ± 8.2 <sup>aa,b</sup>
C	Oxygenation index	395 ± 38	397 ± 29	399 ± 32	408 ± 29
D		402 ± 27	403 ± 33	429 ± 21 <sup>a</sup>	433 ± 22 <sup>a</sup>
N + D		401 ± 25	405 ± 30	429 ± 22 <sup>a</sup>	463 ± 23 <sup>aa,b</sup>
C	B-line sum	2.0 ± 0.9	2.1 ± 1.0	3.9 ± 2.1	4.0 ± 2.0
D		2.1 ± 0.8	2.1 ± 0.9	3.1 ± 2.2 <sup>a</sup>	3.0 ± 1.9 <sup>a</sup>
N + D		2.0 ± 0.8	2.0 ± 0.9	2.9 ± 2.1 <sup>a</sup>	2.3 ± 1.7 <sup>aa,b</sup>

<sup>a</sup>p < 0.05 compared with group C.<sup>aa</sup>p < 0.01 compared with group C.<sup>b</sup>p < 0.05 compared with group D.**TABLE 4 |** Immediate extubation agitation score and Ramsay score at different time points in each group ( $\bar{x} \pm s$ ).

Group	T <sub>3</sub> (agitation score at tube removal)	T <sub>4</sub> (RS score)	T <sub>5</sub> (RS score)	T <sub>6</sub> (RS score)
C	1.6 ± 0.9	3.5 ± 1.1	1.6 ± 1.0	1.5 ± 1.1
D	0.1 ± 0.1 <sup>aa</sup>	4.3 ± 1.0 <sup>a</sup>	3.4 ± 1.1 <sup>a</sup>	2.4 ± 0.7 <sup>a</sup>
N + D	0.0 ± 0.0 <sup>aa</sup>	4.2 ± 0.8 <sup>a</sup>	3.2 ± 0.9 <sup>a</sup>	2.5 ± 0.9 <sup>a</sup>

<sup>a</sup>p < 0.05 compared with group C.<sup>aa</sup>p < 0.01 compared with group C.

**TABLE 5** | Comparison of cough grading at tube removal among groups.

Group	n	Level 1	Level 2	Level 3	Level 4	Level 5
C	59	5	17	23	9	5
D <sup>aa</sup>	59	48	8	2	1	0
N + D <sup>aa</sup>	60	49	7	3	1	0

<sup>aa</sup> $p < 0.01$  compared with group C.

on the eyebrows or upon loud stimulus in the ears; 5 points: slow response after gently patting on the eyebrows or upon loud stimulus in the ears; and 6 points: no response after gently patting on the eyebrows or upon loud stimulus in the ears). A score of 1 point indicated agitation; 2–4 points indicated that sedation was satisfactory; and 5–6 points indicated over-sedation. In patients with a score of  $\geq 2$  points at T<sub>3</sub> or  $< 2$  points after tube removal, propofol 0.5–1 mg kg<sup>-1</sup> was given intravenously, and the cases of drug intervention were recorded.

7) Cough scores: the cough score at T<sub>3</sub> was recorded (Pei et al., 2018) [grade 1: no cough; grade 2: mild cough (1–2 times) and smooth and steady tube removal; grade 3: moderate cough (3–4 times); grade 4: severe cough (5–10 times); and grade 5: agitation and inability to remove the tube].

8) The time from operation completion to ventilator weaning, the time from ventilator weaning to tube removal, and the time from ventilator weaning to awakening (Ramsay sedation score: 4 points) were recorded. The incidence of hypoxemia and airway spasms during the resuscitation period was analyzed, and the postoperative hospital stay was recorded.

## STATISTICAL METHOD

The SPSS 25.0 software was used for data analysis. The measurement data conformed to a normal distribution and were expressed as mean  $\pm$  standard deviation ( $\bar{x} \pm s$ ). One-way ANOVA was used for comparisons between the three groups, while the LSD test was used for two-way comparisons between groups. The  $\chi^2$  test or Fisher's exact test was used for enumeration data analysis. A  $p$  value of  $< 0.05$  was considered statistically significant.

## RESULTS

### Demographics

A total of 180 patients were included in the present study; each patient group comprised 60 patients. In two children, there was a failure to remove the foreign body during the operation; hence, these patients were excluded from the study. There were no statistically significant differences among the groups ( $p > 0.05$ ; Table 1).

### CYCLE INDICATORS AND ADVERSE EVENTS

Compared with group C, the HR and MAP decreased at T<sub>1</sub>–T<sub>2</sub> ( $p < 0.05$ ) and greatly decreased at T<sub>3</sub>–T<sub>6</sub> ( $p < 0.01$ ) in group D

and group N + D. There were no statistically significant differences in HR and MAP between group N + D and group D at any of the time points (Table 2). No cases of hypotension and bradycardia in group C required intervention. There were two cases of bradycardia in group D and group N + D, respectively; however, there was no statistical significance ( $p > 0.05$ ).

There were five cases of hypoxemia in group C during the recovery period; among these, three were relieved after sputum aspiration, and the other two had transient airway spasms and were relieved by intensive sedation and PEEP. The remaining two groups had no adverse events in the respiratory system.

### Inflammatory Factor, Oxygenation Index, and B-Line Sum

Compared with group C, in group D and group N + D, the concentrations of TLR-2, TLR-4, TNF- $\alpha$ , and IL-6, as well as the B-line sum, were low at T<sub>7</sub> and T<sub>8</sub>, and the oxygenation index was high ( $p < 0.05$ ). Compared with group D, in group N + D, the B-line sum and inflammatory factor indicators at T<sub>8</sub> were low, and the oxygenation index was high ( $p < 0.05$ ; Table 3).

### Agitation Score at Tube Removal and the Ramsay Sedation Score

Compared with group C, in group D and group N + D, the agitation score decreased significantly at T<sub>3</sub> ( $p < 0.01$ ), and the score was high at T<sub>4</sub>, T<sub>5</sub>, and T<sub>6</sub> ( $p < 0.05$ ). There were no statistically significant differences in the scores at any of the time points between group N + D and group D (Table 4).

### Cough Score at Tube Removal

Compared with group C, the cough score was greatly decreased in group D and group N + D ( $p < 0.01$ ). There were no statistically significant differences in the scores at any of the time points between group N + D and group D (Table 5).

## POSTOPERATIVE RECOVERY AND REHABILITATION

Compared with group C, in group D and group N + D, the ventilator weaning time was shortened ( $p < 0.05$ ), and the tube removal and awakening times were slightly increased; however, the differences were not statistically significant ( $p > 0.05$ ). The length of postoperative hospital stay was decreased in group N + D compared with the other two groups ( $p < 0.05$ ; Table 6).

## DISCUSSION

Approximately 1,500 children with a tracheal foreign body are admitted to our hospital every year. Among them, children with atelectasis in the perioperative period of foreign body removal are susceptible to lung injury due to hypoxia and reoxidation reaction after pulmonary re-expansion, a stress reaction in the



**TABLE 6** | Comparison of ventilator weaning, laryngeal mask removal, awakening time, and postoperative hospital stay among groups ( $\bar{x} \pm s$ ).

Group	Time of ventilator weaning (min)	Time from ventilator weaning to laryngeal mask removal (min)	Time from ventilator weaning to awakening (min)	Postoperative hospital stay (d)
C	37.9 $\pm$ 3.4	7.9 $\pm$ 3.8	18.9 $\pm$ 5.2	7.3 $\pm$ 0.8
D	25.2 $\pm$ 5.4 <sup>a</sup>	8.3 $\pm$ 5.2	19.2 $\pm$ 4.0	7.1 $\pm$ 0.9
N + D	24.7 $\pm$ 4.8 <sup>a</sup>	8.5 $\pm$ 4.7	19.8 $\pm$ 4.0	3.6 $\pm$ 0.6 <sup>a,b</sup>

<sup>a</sup> $p < 0.05$  compared with group C.

<sup>b</sup> $p < 0.05$  compared with group C.

perioperative anesthesia period, and the release of numerous oxygen free radicals and inflammatory factors.

In recent years, the application of dexmedetomidine, an  $\alpha_2$  adrenergic receptor agonist, for organ protection has been widely used. Dexmedetomidine can activate the  $\alpha_2$  receptors of the central postsynaptic membrane, reduce sympathetic tone, and increase vagal excitability. It can activate the presynaptic  $\alpha_2$  receptors in peripheral sympathetic endings, inhibit the release of norepinephrine, and decrease the concentration of plasma catecholamine (Giovannitti et al., 2015). Furthermore, it can stabilize hemodynamics, relieve oxidative stress caused by surgical trauma, (He et al., 2021), reduce the synthesis and release of pro-inflammatory factors (e.g., TNF- $\alpha$  and IL-6) (Xu et al., 2019), and protect the lung through multiple ways, including anti-sympathia and inhibition of apoptosis, oxidative stress, and inflammatory response (Li et al., 2016).

Dexmedetomidine's effects include analgesia, sedation, and salivation; however, it barely inhibits breathing, (Liu et al., 2021), making it an ideal sedative, and has more obvious advantages for the removal of a foreign body in the bronchus.

According to the literature (Li et al., 2020) and the preliminary experiment (Wang and Jia, 2015), 0.5  $\mu\text{g kg}^{-1}\cdot\text{h}^{-1}$  was pumped intravenously in the present study; the total dose did not exceed 1  $\mu\text{g kg}^{-1}$ , thus remaining within the safety range.

The Cmax could be reached during awakening; this can be effective against agitation during awakening and the cough response during tube removal.

The results of the present study are as follows: there were five cases of hypoxemia in the conventional anesthesia group during awakening; meanwhile, there was no such case in the experimental group. The cycle was more stable in the perioperative period. Bradycardia occurred in only two cases in each group and was quickly corrected.

The following result is consistent with relevant research: intravenous pumping of dexmedetomidine could increase hemodynamics stability in the perioperative anesthesia period and improve postoperative recovery quality (Andersen et al., 2017; Ding et al., 2017). Most adverse reactions of hypotension and bradycardia were transient and easy to correct (Vorobeichik et al., 2017).

The main experimental indicator of the present study was the comparison of TLR-2, TLR-4, TNF- $\alpha$ , and IL-6 before and after the foreign body removal in children with atelectasis; this was conducted to explain the inflammatory mechanism of the non-infected lung injury. Toll-like receptors are "portals" that initiate the inflammatory response, and TLR-2 and TLR-4 are important members of the TLR family; (Bahia et al., 2019); they play an

important role in non-infectious lung injury and can activate the intracellular signal pathway and the nuclear factor NF- $\kappa$ B.

As an oxidative stress-sensitive transcription factor, NF- $\kappa$ B is at the core of inflammatory response regulation. After activation, NF- $\kappa$ B can centrally regulate cytokines and other pro-inflammatory mediators (Wang et al., 2021); regulate the gene expression of a series of inflammatory cytokines; participate in the occurrence and development of pulmonary inflammation; and induce TNF- $\alpha$ , IL-1, IL-6, IL-8, and secondary inflammatory factors to form a "cytokine cascade reaction," thus initiating lung inflammation.

Compared with the conventional anesthesia group, the two experimental groups for which dexmedetomidine was added had a higher oxygenation index, shorter postoperative ventilator weaning time, and fewer inflammatory factors. These results fully prove the protective effect of dexmedetomidine.

The B-line, also called the "comet tail sign," is a number of strong parallel echo lines that are gradually adducted and weakened from the lung wall interface to the edge of the screen under pulmonary ultrasound (Ciumanghel et al., 2017). A relative or significant increase in extravascular lung water will lead to an increase in the B-line (Picano and Pellikka, 2016).

In the present study, groups with dexmedetomidine had a lower ultrasound B-line sum than groups without dexmedetomidine, indicating a less extravascular pulmonary fluid content. Due to the influence of the fluid balance on the B-line, the sufficiency of the evidence of dexmedetomidine decreasing the B-line sum depends on the results of the fluid balance monitoring, especially the result of the fluid intake. However, data on fluid balance were not collected in the present study. As there is currently no relevant research on the effect of dexmedetomidine on fluid balance, the fluid balance will be monitored during the future study to prove the effect.

Nalbuphine hydrochloride is a lipophilic semi-synthetic opioid that can bond to  $\kappa$ ,  $\delta$ , and  $\mu$  receptors in order to show strong  $\kappa$  receptor excitation and  $\mu$  receptor antagonism; it is comparable to morphine in terms of analgesic effect (Ramstead et al., 2016). Nalbuphine becomes effective 2–3 min after intravenous administration; it has a plasma half-life of 5 h and effectiveness of 3–6 h. It can be used before surgery for anesthesia with a long duration and few adverse reactions (Gonçalves de Freitas et al., 2016; Xu et al., 2019).

Studies show that the preoperative use of nalbuphine can inhibit the patient inflammatory response as well as effectively inhibit surgical trauma (Jiang, 2018). A dose of 0.2  $\text{mg kg}^{-1}$  nalbuphine in children without respiratory depression (Wang, 2017) in combination with  $\mu$  receptors can partially reverse or block opiate-induced respiratory depression.

In this study, the use of 0.2 mg kg<sup>-1</sup> nalbuphine before operation enhanced the effect and delayed the time of the inflammatory response without prolonging the time of ventilator weaning and awakening. As a result, the inflammatory response factor was low and the oxygenation index was high at 2–24 h after the operation. In addition, the extravascular pulmonary fluid content was reduced and the length of hospital stay was shortened. This may be due to the fact that early use can more effectively prevent central sensitization caused by anesthetic stimulation and surgical trauma as well as inhibit the synthesis and release of TNF- $\alpha$  and IL-6 than those in late use (Gonçalves de Freitas et al., 2016).

It has been reported that retaining spontaneous respiration is mostly used for removing a foreign body from a bronchus. In such cases, muscle relaxants can be used to control breathing.

In the present study, total intravenous anesthesia and the muscle relaxant cisatracurium were used to ensure anesthesia depth and complete muscle relaxation for foreign body removal. Ventilation was used intermittently (ventilation was interrupted only transiently during foreign body removal) to meet the oxygen supply and reduce adverse reactions caused by anesthesia. There was no breath-holding or airway spasm during the operations. These results are consistent with the relevant literature (Cai et al., 2017).

Remifentanyl, a short-acting opioid analgesic, shows stable hemodynamics and no accumulation; this is conducive to rapid postoperative recovery. In the recovery period, the SIMV + PSV mode of the ventilator is gradually weaned to ensure oxygenation as well as reduce cough, man–machine counteraction, and respiratory muscle acting (Cao and Chen, 2018).

The present study has several limitations: there were deficiencies in the sample size, observation indicators, and groupings. In the future, more samples and observation indicators, as well as accurate grouping, will be taken into consideration for an in-depth comparative study.

In conclusion, in children with atelectasis, nalbuphine combined with dexmedetomidine may reduce the release of inflammatory factors during the removal of a foreign body from a bronchus in the perioperative anesthesia period, inhibit oxidative stress reaction, improve the oxygenation index, and protect the lung; it may also lower agitation during awakening and the cough reaction during tube removal. In addition, the circulatory function is stable, and the awakening time is not prolonged, thus accelerating postoperative recovery.

## REFERENCES

- Andersen, J. H., Grevstad, U., Siegel, H., Dahl, J. B., Mathiesen, O., and Jæger, P. (2017). Does Dexmedetomidine Have a Perineural Mechanism of Action When Used as an Adjuvant to Ropivacaine? *Anesthesiology* 126 (1), 66–73. doi:10.1097/ALN.0000000000001429
- Bahia, W., Soltani, I., Haddad, A., Radhouani, A., Mahdhi, A., Ferchichi, S., et al. (2019). Links Between SNPs in TLR-2 and TLR-4 and Idiopathic Recurrent Pregnancy Loss. *Br. J. Biomed. Sci.* 77, 64–68. doi:10.1080/09674845.2019.1687151
- Cai, J. J., Lv, H., Liu, G. L., Chen, L. L., Fang, X., and Zheng, T. H. (2017). Application of Dexmedetomidine in Emergency Anesthesia for Removal of

## DATA AVAILABILITY STATEMENT

The original contributions presented in the study are included in the article/Supplementary Material, further inquiries can be directed to the corresponding author.

## ETHICS STATEMENT

The studies involving human participants were reviewed and approved by Medical Ethics Committee of Children's Hospital Affiliated with Zhengzhou University (2021-K-98). Written informed consent to participate in this study was provided by the participants' legal guardian/next of kin.

## AUTHOR'S CONTRIBUTIONS

Conception and design of the research: YW. Acquisition of data: YL, B-JZ, and L-YZ. Analysis and interpretation of the data: YW and JZ. Statistical analysis: H-YH and L-YZ. Obtaining funds: Y-PJ. Writing of the manuscript: YW. Critical revision of the manuscript for intellectual content: YW. All authors read and approved the final draft.

## FUNDING

This work was supported by the Scientific Research Project: Henan Province Medical Science and Technology Breakthrough Project (No: 201403254), Henan Province Medical Science and Technology Breakthrough Joint Project (No: 2018020653), Zhengzhou City Medical Science and Technology Breakthrough Project (No: 20150171), and Henan Province medical science and technology breakthrough project. Key projects jointly built by provinces and ministries (NO. SBGJ202102210).

## ACKNOWLEDGMENTS

The authors would like to acknowledge the hard and dedicated work of all the staff that implemented the intervention and evaluation components of the study.

Tracheal Foreign Bodies in Infants. *J. Clin. Pediatr. Surg.* 16 (4), 368–372. doi:10.3969/j.issn.1671-6353.2017.04.013

- Cao, C. W., and Chen, Q. L. (2018). Clinical Study of Mechanical Ventilation on Ventilator Related Diaphragm Dysfunction after Operation of Acute Craniocerebral Injury. *J. Clin. Pulm. Med.* 23 (4), 710–714. doi:10.3969/j.issn.1009-6663.2018.04.035
- Ciumanghel, A., Siropol, I., Blaj, M., Siropol, D., Gavrilovici, C., and Covic, A. (2017). B-lines Score on Lung Ultrasound as a Direct Measure of Respiratory Dysfunction in ICU Patients with Acute Kidney Injury. *Int. Urol. Nephrol.* 50, 113–119. doi:10.1007/s11255-017-1730-8
- Ding, W., Li, W., Zeng, X., Li, J., Jiang, J., Guo, C., et al. (2017). Effect of Adding Dexmedetomidine to Ropivacaine on Ultrasound-Guided Dual Transversus Abdominis Plane Block after Gastrectomy. *J. Gastrointest. Surg.* 21 (6), 936–946. doi:10.1007/s11605-017-3402-5

- Giovannitti, J. A., Jr, Thoms, S. M., and Crawford, J. J. (2015). Alpha-2 Adrenergic Receptor Agonists: A Review of Current Clinical Applications. *Anesth. Prog.* 62 (1), 31–38. doi:10.2344/0003-3006-62.1.31
- Gonçalves de Freitas, A. T. A., Lemonic, L., De faveri, J., Pereira, S., and Bedoya Henao, M. D. (2016). Preemptive Analgesia with Acupuncture Monitored by C-Fos Expression in Rats [J]. *J. Acupuncture Meridian Stud.* 9, 16. doi:10.106/j.jams.2015.08.002
- He, K., Ji, W., Zhao, H., Wei, Y., Yang, S., and Wen, Q. (2021). Pharmacokinetic Comparison of Nalbuphine with Single Injection and Patient-Controlled Analgesia Mimic Method in Healthy Chinese Volunteers. *J. Clin. Pharm. Ther.* 46 (4), 1166–1172. doi:10.1111/jcpt.13421
- Jiang, Q. (2018). Effect of Nalbuphine Hydrochloride Injection Preemptive Analgesia on Elderly Patients Serum IL-10, TNF- and IL-6. *China Contin. Med. Educ.* 10 (4), 48–50. doi:10.3969/j.issn.1674-9308.2018.04.026
- Li, N., Ouyang, B. S., Liu, L., Lin, C. S., Xing, D. D., and Liu, J. (2016). Dexmedetomidine Protected COPD-Induced Lung Injury by Regulating miRNA-146a. *Bll* 117 (9), 539–542. doi:10.4149/bll\_2016\_106
- Li, S., Liu, T., Xia, J., Jia, J., and Li, W. (2020). Effect of Dexmedetomidine on Prevention of Postoperative Nausea and Vomiting in Pediatric Strabismus Surgery: A Randomized Controlled Study. *BMC Ophthalmol.* 20 (1), 86. doi:10.1186/s12886-020-01359-3
- Liu, H. Z., Ma, X., and Luo, Y. (2021). Application of Dexmedetomidine in Functional Neurosurgery during the Perioperative Period. *Int. J. Anesthesiology Resuscitation* 42 (3), 283–287. doi:10.3760/cma.j.cn321761-20200527-00239
- Liu, j., Feng, X., Hu, C. B., and Qiu, R. X. (2019). Guidelines for Ultrasonic Diagnosis of Neonatal Lung Diseases. *Chin. J. Contemp. Pediatr.* 21 (02), 105–113. doi:10.7499/j.issn.1008-8830.2019.02.001
- Pei, F. G., Han, J. H., and Liu, Y. G. (2018). Effects of Dexmedetomidine Combined with Oxycodone on Agitation and Stress Response in Elderly Patients Undergoing Gastrointestinal Surgery. *Eval. Anal. Drug Use Chin. Hospitals* 18 (7), 915–917. doi:10.14009/j.issn.1672-2124.2018.07.019
- Picano, E., and Pellikka, P. A. (2016). Ultrasound of Extravascular Lung Water: A New Standard for Pulmonary Congestion. *Eur. Heart J.* 37 (10), 2097–2104. doi:10.1016/j.repc.2016.09.00310.1093/eurheartj/ehw164
- Quan, Y. S. (2019). To Investigate the Protective Effect of Dexmedetomidine on Lung Injury Induced by One Lung Ventilation. *Chin. Pract. Med.* 14 (34), 120–121. doi:10.14163/j.cnki.11-5547/r.2019.34.064
- Ramstead, A. G., Robison, A., Blackwell, A., Jerome, M., Freedman, B., Lubick, K. J., et al. (2016). Roles of Toll-Like Receptor 2 (TLR2), TLR4, and MyD88 During Pulmonary Coxiella Burnetii Infection. *Infect. Immun.* 84 (4), 940–949. doi:10.1128/IAI.00898-15
- Sun, H. N., Han, Z. H., and Chen, X. X. (2018). Application of Neurally Adjusted Ventilation Assist on Patients with Acute Exacerbation of Chronic Obstructive Pulmonary Disease. *Int. J. Respiration* 38 (2), 101–108. doi:10.3760/cma.j.issn.1673-436X.2018.02.005
- Vorobeichik, L., Brull, R., and Abdallah, F. W. (2017). Evidence Basis for Using Perineural Dexmedetomidine to Enhance the Quality of Brachial Plexus Nerve Blocks: A Systematic Review and Meta-Analysis of Randomized Controlled Trials. *Br. J. Anaesth.* 118 (2), 167–181. doi:10.1093/bja/aew411
- Wang, J. Y., Li, S. W., and Wu, Y. K. (2021). Nobiletin Alleviates OLT-Induced Liver Ischemia-Reperfusion by Inhibiting Activation of Kupffer Cell through AKT/GSK3 $\beta$ /NF- $\kappa$ B Pathway in Rats. *Chin. J. Immunol.* 37 (9), 1047–1052. doi:10.3969/j.issn.1000-484X.2021.09.005
- Wang, L. (2017). *Clinical Observation of Naborphine in Preventing Agitation During Recovery from General Anesthesia in Children with Strabismus Correction*. Zhengzhou: Zhengzhou University, 1–62.
- Wang, Y., and Jia, Y. P. (2015). Effect of Dexmedetomidine on Agitation and Cough after Bronchial Foreign Body Surgery. *Chin. J. Exp. Surg.* 32 (8), 1918. doi:10.3760/cma.j.issn.1001-9030.2015.08.050
- Xu, Q., Zhang, Y., Li, H., Mao, X. Z., Dai, R. P., and Zhang, Y. L. (2019). Effect of Pre-Administration of Nabuphine Hydrochloride PCIA on Preoperative Pain and Quality of Life in Patients with Fracture. *J. Clin. Anesthesiology* 35 (3), 253–255. doi:10.12089/jca.2019.03.010
- Zhang, P. (2018). Protective Effect of Dexmedetomidine on Lung Injury in Patients with Traumatic Wet Lung Under Mechanical Ventilation. *J. Clin. Pulm. Med.* 23 (11), 2065–2069. doi:10.3969/j.issn.1009-6663.2018.11.032

**Conflict of Interest:** The authors declare that the research was conducted in the absence of any commercial or financial relationships that could be construed as a potential conflict of interest.

**Publisher's Note:** All claims expressed in this article are solely those of the authors and do not necessarily represent those of their affiliated organizations, or those of the publisher, the editors, and the reviewers. Any product that may be evaluated in this article, or claim that may be made by its manufacturer, is not guaranteed or endorsed by the publisher.

Copyright © 2022 Wang, Han, Jia, Zhao, Li, Zuo and Zhang. This is an open-access article distributed under the terms of the Creative Commons Attribution License (CC BY). The use, distribution or reproduction in other forums is permitted, provided the original author(s) and the copyright owner(s) are credited and that the original publication in this journal is cited, in accordance with accepted academic practice. No use, distribution or reproduction is permitted which does not comply with these terms.