



Multimodal Analgesia With Long-Acting Dinalbuphine Sebacate Plus Transversus Abdominis Plane Block for Perioperative Pain Management in Bariatric Surgery: A Case Report

Shih-Yuan Liu¹, Yi-Hong Ho² and Chih-Shung Wong^{1,2,3*}

¹School of Medicine, Fu-Jen Catholic University, New Taipei, Taiwan, ²Department of Anesthesiology, Cathay General Hospital, Taipei, Taiwan, ³Graduate Institute of Medical Science, National Defense Medical, Taipei, Taiwan

OPEN ACCESS

Edited by:

Francisco Lopez-Munoz,
Camilo José Cela University, Spain

Reviewed by:

Arsen Uvelin,
Clinical Center of Vojvodina, Serbia
Ramya Arjunan,
Sri Ramakrishna Hospital, India
Dilek Erdoğan Arı,
Fatih Sultan Mehmet Education and
Research Hospital, Turkey

*Correspondence:

Chih-Shung Wong
w82556@gmail.com

Specialty section:

This article was submitted to
Neuropharmacology,
a section of the journal
Frontiers in Pharmacology

Received: 22 March 2021

Accepted: 12 May 2021

Published: 28 May 2021

Citation:

Liu S-Y, Ho Y-H and Wong C-S (2021)
Multimodal Analgesia With Long-
Acting Dinalbuphine Sebacate Plus
Transversus Abdominis Plane Block for
Perioperative Pain Management in
Bariatric Surgery: A Case Report.
Front. Pharmacol. 12:683782.
doi: 10.3389/fphar.2021.683782

Laparoscopic bariatric surgery is increasingly performed in morbidly obese patients. However, post-surgical pain is common and is usually managed with classical opioids such as morphine and fentanyl. Further, morbidly obese patients are predisposed to opioid-related side effects, especially post-operative nausea and vomiting (PONV), and respiratory depression. Obstructive sleep apnea in morbidly obese patients even predisposes them to respiratory depression. Thus, reducing opioid consumption is important. Multimodal analgesia (MMA) provides optimal perioperative analgesia while minimizing opioid consumption. Studies have shown that MMA strategy can provide sufficient pain relief in bariatric surgery with enhanced recovery. There are very few reports on the use of dinalbuphine sebacate (DS), a newly introduced non-controlled opioid medication with long-lasting analgesic effects. DS has a different mechanism of action from that of morphine or fentanyl and is non-addictive, with minimal side effects. It has been successfully used in laparoscopic cholecystectomy in our previous study. We present a case of a new MMA protocol with DS on a 46-year-old morbidly obese female patient who underwent laparoscopic sleeve gastrectomy. The MMA protocol included ultrasound-guided intramuscular DS injection plus transversus abdominis plane (TAP) block and other analgesics; it achieved good perioperative analgesia with opioid-sparing effect and enhanced patient's recovery with no pain in the following 4 months.

Keywords: bariatric surgery, long-acting dinalbuphine sebacate (naldebain®), TAP, opioid-sparing, MMA

INTRODUCTION

Bariatric surgery has become a common practice in recent years due to the prevalence of morbid obesity. Currently, the surgery is covered by national health insurance in Taiwan. The laparoscopic approach is frequently preferred due to its minimal invasiveness and less postoperative pain (Weingarten et al., 2011; Alvarez et al., 2014; Ng et al., 2017). However, 41% of patients reported severe pain (7 of 10 in VAS score) in the first 48 h after laparoscopic bariatric surgery (Weingarten et al., 2011). For post-surgical pain, classical systemic opioids such as morphine and

fentanyl are still the therapeutic mainstay (Wu et al., 2002; Macrae, 2008; Huang et al., 2018). Obese patients, however, are susceptible to opioid-related side effects, especially postoperative nausea and vomiting (PONV), and respiratory depression (Weingarten et al., 2011; Alvarez et al., 2014; Ng et al., 2017). Further, obstructive sleep apnea is common in morbidly obese patients, which even predisposes them to respiratory depression (Weingarten et al., 2011). Thus, the consumption of classical opioids should be kept at a minimal level. Multimodal analgesia (MMA), which aims to reduce opioid use, has been shown to provide satisfactory perioperative pain relief with an opioid-sparing effect (Alvarez et al., 2014; Ng et al., 2017). With adequate perioperative pain control, the patient's recovery is enhanced, and potential complications become preventable. For example, with early mobilization, and early discharge, the risk of thrombosis is reduced (Alvarez et al., 2014). Many studies applied multimodal analgesia (MMA) in bariatric surgery and showed good outcomes, but few included dinalbuphine sebacate (DS, Naldebain®) (Alvarez et al., 2014; Ng et al., 2017). Developed based on distinctive non-controlled opioid DS, an extended-release form of nalbuphine, provides long-term (up to 7 days) moderate pain control with no addiction potential and fewer adverse effects. To reduce opioid-related adverse effects and the risk of long-term dependence and abuse, replacing morphine with DS may be an ideal strategy. We particularly implemented DS in our MMA protocol for perioperative pain management in bariatric surgery. On top of that, we adopted the transversus abdominis plane (TAP) block, which is preferred for its low risk of complications, and successful immediate nerve blockade for abdominal surgery pain management. The MMA protocol included ultrasound-guided intramuscular DS injection plus TAP block and other analgesics to achieve good postoperative analgesia with an opioid-sparing effect.

CASE REPORT

A 46-year-old female patient was diagnosed with morbid obesity (BMI: 43.7 kg/m², Height: 157.5 cm, and Body Weight: 108.4 kg) and treated with insulin and oral hypoglycemic agent for type 2 diabetes mellitus. She was arranged for laparoscopic gastrectomy by sleeve technique (with intra-abdominal pressure of 12 cm H₂O by CO₂ insufflation). In preoperative anesthesia assessment, there were no clinically significant findings in routine laboratory examination, electrocardiogram, and chest X-ray. The American Society of Anesthesiologists (ASA) was graded as Class III. No premedication was prescribed and no medical history contradicted with nalbuphine. Vital signs were normal and monitored during the operation. General anesthesia was induced by glycopyrrolate 0.2 mg, 2% lidocaine 50 mg, propofol 200 mg, fentanyl 250 µg. Rocuronium 60 mg was used to facilitate endotracheal intubation with a 7.5 mm inner diameter. Ketamine 50 mg (Remérand et al., 2009; Brinck et al., 2018) and dexamethasone 10 mg (Wang et al., 2011; DREAMS Trial Collaborators and West Midlands Research Collaborative, 2017; Brown et al., 2018) were also given for preemptive analgesia

and postoperative nausea and vomiting (PONV) prevention respectively. After the anesthesia induction setup, the patient was placed in a supine position and received one dose of long-acting dinalbuphine sebacate (150 mg DS/2ml, Naldebain® ER Injection, Lumosa Therapeutics Co. Ltd., Taiwan) by ultrasound-guided intramuscular injection at the left upper arm. Anesthesia was maintained by desflurane during the operation. The patient was kept hemodynamically stable throughout the operation.

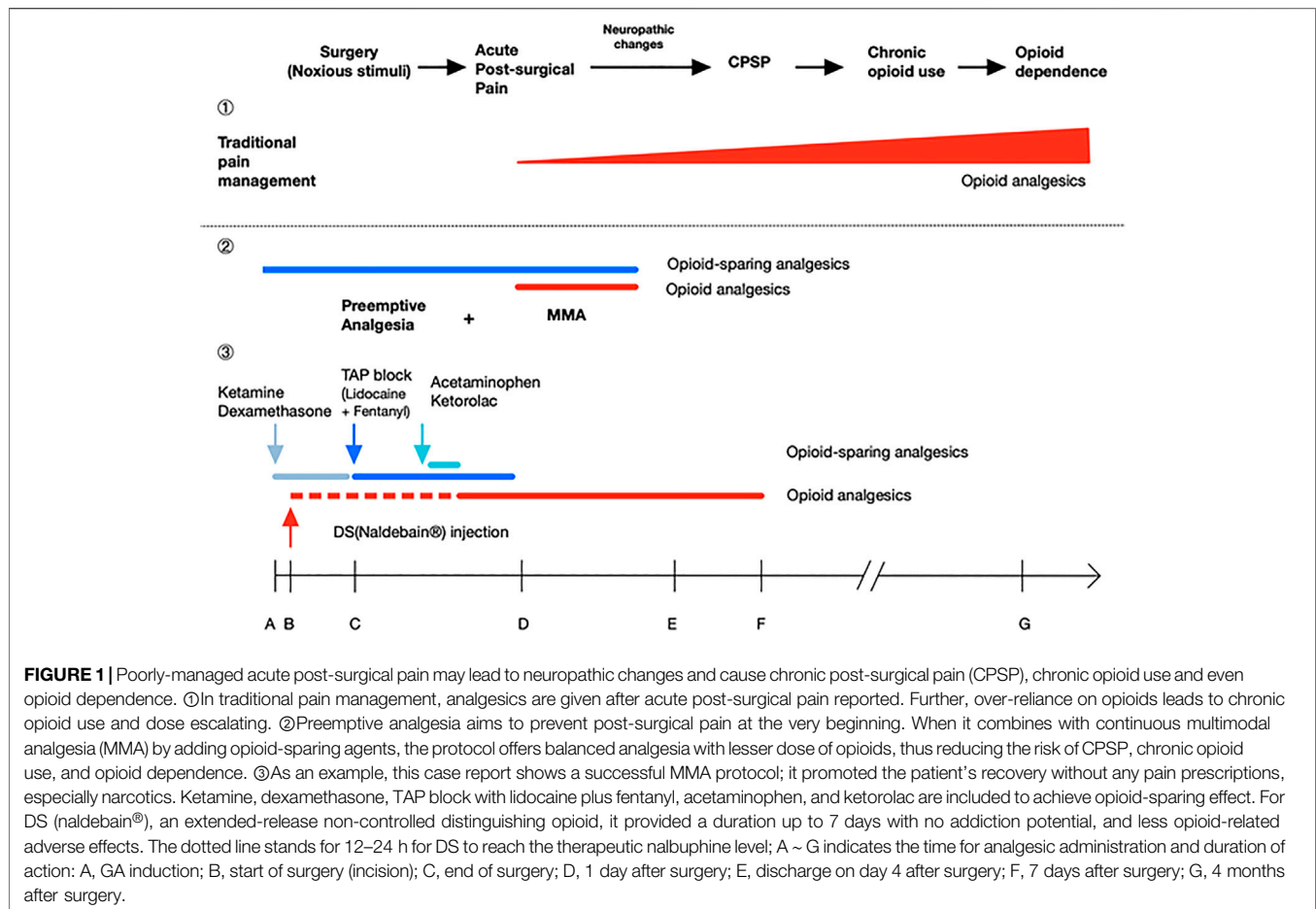
After the last closing suture was finished, an ultrasound-guided transversus abdominis plane (TAP) block was followed. The patient was placed in a supine position. The convex probe was utilized from the xyphoid process obliquely and laterally along the costal margin. Three muscle layers of transversus abdominis, internal oblique, and external oblique can be distinctly identified by the transducer. The injection site was chosen at the mid-axillary line between the iliac crest and costal margin. It was visualized between the internal oblique and transversus abdominis, and confirmed by hydro-dissection with 5 ml of normal saline, followed by 20 ml 0.5% lidocaine and adjunct fentanyl 100 µg. A total dose of 250 µg fentanyl was administered i.v during the maintenance of the whole procedure and the whole operation lasted less than 2 h. Sugammadex 200 mg was given for residual muscle relaxant reversal and the endotracheal tube was removed smoothly after the patient regained her spontaneous breathing with TOF >0.9, and then the patient was transferred to the postoperative anesthesia care unit (PACU).

Acetaminophen 1 gm and ketorolac 30 mg were given immediately on arrival at the PACU. No pain and PONV were reported during one-hour of PACU stay. Then, the patient was sent to the general ward with a stable condition for further postoperative care. At 3 h after surgery, mild wound pain was noted with 2 out of 10 in the visual analog score. On post-operation day 3, the patient tolerated oral water intake. During the following hospital stay, the patient recovered well, and no further analgesics were given at the ward. The patient was discharged on day 4 after surgery.

From discharge to the first follow-up visit (6 days after surgery), satisfying pain relief (VAS score was below 3) was reported and no analgesics were taken. In the four-month follow-up visit, no analgesic was prescribed and no post-surgical complication was reported. This case report was reviewed and approved by Cathay General Hospital IRB (CGH-IRB No.CGH-P110009) with the patient's consent.

DISCUSSIONS

For the MMA protocol, in this case, we included extended-released DS intramuscular injection before the operation, ultrasound-guided TAP at the end of the surgery, and other pain medications: ketamine, dexamethasone, acetaminophen, and ketorolac for opioid-sparing effect (Alvarez et al., 2014; Remérand et al., 2009; Brinck et al., 2018; Wang et al., 2011; DREAMS Trial Collaborators and West Midlands Research Collaborative, 2017; Tolska et al., 2019). We observed sufficient pain relief without the requirement of other pain



medications after discharge. **Figure 1.** shows the theoretical effect of the MMA on post-surgical recovery, chronic post-surgical pain (CPSP) development, and the later chronic opioid use; as long as successful MMA protocol can be implemented using this case as an example. Ketamine and dexamethasone were given intravenously together with anesthesia induction. Ketamine, an NMDA receptor antagonist, provides an opioid-sparing effect to reduce postoperative opioid consumption, prolongs postoperative analgesia while also slightly reducing the incidence of PONV (Remérand et al., 2009; Alvarez et al., 2014; Ng et al., 2017; Brinck et al., 2018; Tolska et al., 2019). Dexamethasone is recommended as the first-line drug for PONV prevention with no adverse effects and also plays a role in MMA (Wang et al., 2011; Alvarez et al., 2014; DREAMS Trial Collaborators and West Midlands Research Collaborative, 2017), while PONV is the major side effect of volatile general anesthesia and opioid use.

Ultrasound-guided intramuscular long-acting DS was given immediately after general anesthesia induction. DS is an extended-release prodrug of nalbuphine which acts as a partial agonist at the κ -opioid receptor and a weak antagonist at the μ -opioid receptor; it is slightly less potent than morphine. Compared to morphine, DS produces less dependence, less sedation, and less respiratory depression (Yeh et al., 2017; Lee

et al., 2020). DS (Naldebain® Injection, Lumosa Therapeutics, Taiwan) was introduced in Taiwan in 2017; it, *via* intramuscular injection, delivers and maintains an effective nalbuphine analgesic blood level for approximately 7 days (Huang et al., 2020). Our previous study showed DS provided satisfying postoperative pain relief for laparoscopic cholecystectomy (Lee et al., 2020). The postoperative pain scores of laparoscopic bariatric surgery are variable from 6 to 8 out of 10 (Gerbershagen et al., 2013; Brummett et al., 2017).

The recommended injecting time of DS is 12–24 h before surgery to attain peak plasma concentration, providing preemptive analgesia, and continuous postoperative pain control for another 5–6 days. However, injection site pain is the most reported complication, and the incidence rate was up to 61% (Wang et al., 2011). In this case, the patient was admitted just before surgery on the day of the operation. As expected, the time for DS to take effect was not sufficient as it needs 12–24 h to reach peak analgesic effect concentration. To resolve this problem, we conducted an ultrasound-guided TAP block for immediate pain control before DS reached the therapeutic blood level; this lidocaine regimen maybe not enough for the maintenance of analgesia over 12 h, however, the presence of 100 μ g of fentanyl adjunct may enhance, and prolong the duration of TAP blocking effect. In this case, no gap was

observed with satisfactory analgesia after emergence from general anesthesia. On top of that, the adipose layer of this patient was so thick (more than 5 cm). It was hard to inject DS into the gluteal muscle following the manufacturer's insert recommended; accidental DS injection into the adipose layer might cause the oil-based DS formulation to fail to release into the blood vessel and even cause a painful lipid pack in the subcutaneous or adipose tissue as reported injection pain. To avoid the aforementioned incident and correctly inject DS into muscle, we injected DS into the left upper arm by ultrasound guidance.

At the end of the surgery before anesthesia emergence, TAP block was conducted with lidocaine (0.5% 20 ml) plus fentanyl (100 µg), to provide immediate postoperative analgesia before the DS can reach effective blood concentration (Kearns and Young, 2011; Sammons and Ritchey, 2015). TAP block is an abdominal wall field block targeting the ventral rami of the T7 ~ L1 spinal nerves. By acting peripherally, it completely prevents noxious stimuli from reaching the central nervous system. Several studies demonstrated that TAP blocks yielded adequate analgesia and could reduce opioid consumption in the first 24 h after abdominal surgery (Kearns and Young, 2011; Sammons and Ritchey, 2015). For the future application of MMA with TAP block, however, a larger volume of longer-lasting local anesthetic (levobupivacaine or ropivacaine) would certainly provide a better spread effect, and ensure more effective pain control.

Ketorolac 30 mg and acetaminophen 1 gm were given on arrival of PACU. As known, non-selective cyclooxygenase inhibitor ketorolac has been demonstrated to provide good efficacy in postoperative analgesia. Its mean plasma half-life is approximately 5.5 h and can reach maximum effect by 1 or 2 h by oral, for intravenous injection, it produces an immediate pain relief at PAUC with a duration of 4–6 h (Gillis and Brogden, 1997). In a study by Cassinelli et al., 2008, ketorolac has been shown to decrease visual analog pain score if administered immediately postoperatively. It is recommended as a component of multimodal analgesia in obese patients with opioid-sparing effects (Alvarez et al., 2014). As for acetaminophen, N-acetyl-para-aminophenol, it can centrally inhibit prostaglandin synthesis by inhibiting both COX-1 and COX-2 enzymes activity with no sedative effect, and is also shown to possess a significant opioid-sparing effect (White et al., 2007); it has been widely utilized in postoperative analgesia, as a part of MMA in ERAS protocol in our hospital, due to its rapid onset for immediate pain control (Brown et al., 2018). Both ketorolac and acetaminophen are standard rescue

analgesics at our PACU, which provide opioid-sparing effect and satisfactory pain relief.

CONCLUSIONS

Classical opioid use such as morphine or fentanyl should be reduced in surgery, especially in obese patients for avoiding PONV and respiratory depression. MMA strategy is widely used in anesthesia practice and perioperative analgesia to minimize opioid consumption with opioid-sparing effect, particularly in bariatric surgery. DS (naldebain®) is a newly-introduced non-controlled opioid medication with a long duration and no addiction potential. We demonstrated a successful MMA protocol with DS on this obese patient undergoing laparoscopic sleeve gastrectomy; it included ultrasound-guided intramuscular DS (150 mg, not a body weight-related dose) injection plus TAP block and other analgesics (ketorolac and acetaminophen). From this case, we suggest the slow release of nalbuphine, DS, may play an important role in perioperative MMA. A large-scale clinical trial is needed to show its role in the MMA regimen.

DATA AVAILABILITY STATEMENT

The datasets presented in this article are not readily available because No dataset. Requests to access the datasets should be directed to C-SW, w82556@gmail.com

ETHICS STATEMENT

The studies involving human participants were reviewed and approved by Cathay General Hospital IRB. The patients/participants provided their written informed consent to participate in this study.

AUTHOR CONTRIBUTIONS

S-YL is for the case medical record review and manuscript writing. Y-HH helps to review and comment on the case report writing and English writing check. C-SW guides S-YL on the case report writing and discussion and for the final manuscript review.

REFERENCES

- Alvarez, A., Singh, P. M., and Sinha, A. C. (2014). Postoperative Analgesia in Morbid Obesity. *Obes. Surg.* 24, 652–659. doi:10.1007/s11695-014-1185-2
- Brinck, E. C., Tiippana, E., Heesen, M., Bell, R. F., Straube, S., Moore, R. A., et al. (2018). Perioperative Intravenous Ketamine for Acute Postoperative Pain in Adults. *Cochrane Database Syst. Rev.* 12, Cd012033.
- Brown, E. N., Pavone, K. J., and Naranjo, M. (2018). Multimodal General Anesthesia. *Anesth. Analgesia* 127, 1246–1258. doi:10.1213/ane.0000000000003668
- Brummett, C. M., Waljee, J. F., Goesling, J., Moser, S., Lin, P., Englesbe, M. J., et al. (2017). New Persistent Opioid Use After Minor and Major Surgical Procedures in US Adults. *JAMA Surg.* 152, e170504. doi:10.1001/jamasurg.2017.0504
- Cassinelli, E. H., Dean, C. L., Garcia, R. M., Furey, C. G., and Bohlman, H. H. (2008). Ketorolac Use for Postoperative Pain Management Following Lumbar Decompression Surgery: A Prospective, Randomized, Double-Blinded, Placebo-Controlled Trial. *Spine (Phila Pa 1976)* 33, 1313–1317. doi:10.1097/BRS.0b013e31817329bd
- DREAMS Trial Collaborators and West Midlands Research Collaborative (2017). Dexamethasone versus Standard Treatment for Postoperative Nausea and Vomiting in Gastrointestinal Surgery: Randomised Controlled Trial (DREAMS Trial). *Bmj* 357, j1455. doi:10.1136/bmj.j1455
- Gerbershagen, H. J., Aduckathil, S., van Wijck, A. J. M., Peelen, L. M., Kalkman, C. J., and Meissner, W. (2013). Pain Intensity on the First

- Day After Surgery. *Anesthesiology* 118, 934–944. doi:10.1097/aln.0b013e31828866b3
- Gillis, J. C., and Brogden, R. N. (1997). Ketorolac. *Drugs* 53, 139–188. doi:10.2165/00003495-199753010-00012
- Huang, C. C., Sun, W. Z., and Wong, C. S. (2018). Prevention of Chronic Postsurgical Pain: The Effect of Preventive and Multimodal Analgesia. *Asian J. Anesthesiol* 56, 74–82. doi:10.6859/aja.201809_56(3).0002
- Huang, W.-H., Huang, N.-C., Lin, J.-A., and Wong, C.-S. (2020). Multimodal Analgesia for Shoulder Rotator Cuff Surgery Pain: The Role of Naldebain® and Ultrasound-Guided Peripheral Nerve Blocks Combination. *J. Med. Sci.* 40, 279–283.
- Kearns, R. J., and Young, S. J. (2011). Transversus Abdominis Plane Blocks; a National Survey of Techniques Used by UK Obstetric Anaesthetists. *Int. J. Obstet. Anesth.* 20, 103–104. doi:10.1016/j.ijoa.2010.08.005
- Lee, S.-O., Huang, L.-P., and Wong, C.-S. (2020). Preoperative Administration of Extended-Release Dinalbuphine Sebacate Compares with Morphine for Post-Laparoscopic Cholecystectomy Pain Management: A Randomized Study. *Jpr* 13, 2247–2253. doi:10.2147/jpr.s263315
- Macrae, W. A. (2008). Chronic post-surgical Pain: 10 Years on. *Br. J. Anaesth.* 101, 77–86. doi:10.1093/bja/aen099
- Ng, J. J., Leong, W. Q., Tan, C. S., Poon, K. H., Lomanto, D., So, J. B. Y., et al. (2017). A Multimodal Analgesic Protocol Reduces Opioid-Related Adverse Events and Improves Patient Outcomes in Laparoscopic Sleeve Gastrectomy. *Obes. Surg.* 27, 3075–3081. doi:10.1007/s11695-017-2790-7
- Remérand, F., Le Tendre, C., Baud, A., Couvret, C., Pourrat, X., Favard, L., et al. (2009). The Early and Delayed Analgesic Effects of Ketamine after Total Hip Arthroplasty: A Prospective, Randomized, Controlled, Double-Blind Study. *Anesth. Analgesia* 109, 1963–1971. doi:10.1213/ane.0b013e3181bdc8a0
- Sammons, G., and Ritchey, W. (2015). Use of Transversus Abdominis Plane (TAP) Blocks for Pain Management in Elderly Surgical Patients. *AORN J.* 102, 493–497. doi:10.1016/j.aorn.2015.09.003
- Tolska, H. K., Hamunen, K., Takala, A., and Kontinen, V. K. (2019). Systematic Review of Analgesics and Dexamethasone for Post-Tonsillectomy Pain in Adults. *Br. J. Anaesth.* 123, e397–e411. doi:10.1016/j.bja.2019.04.063
- Wang, F.-Y., Shen, Y.-C., Chen, M.-K., Chau, S.-W., Ku, C.-L., Feng, Y.-T., et al. (2011). Equal Volumes of Undiluted Nalbuphine and Lidocaine and normal Diluted Saline Prevents Nalbuphine-Induced Injection Pain. *Acta Anaesthesiologica Taiwanica* 49, 125–129. doi:10.1016/j.aat.2011.11.009
- Weingarten, T. N., Sprung, J., Flores, A., Oviedo Baena, A. M., Schroeder, D. R., and Warner, D. O. (2011). Opioid Requirements after Laparoscopic Bariatric Surgery. *Obes. Surg.* 21, 1407–1412. doi:10.1007/s11695-010-0217-9
- White, P. F., Kehlet, H., Neal, J. M., Schrickler, T., Carr, D. B., and Carli, F.S.S. Group (2007). The Role of the Anesthesiologist in Fast-Track Surgery: From Multimodal Analgesia to Perioperative Medical Care. *Anesth. Analgesia* 104, 1380–1396. doi:10.1213/01.ane.0000263034.96885.e1
- Wu, C. L., Berenholtz, S. M., Pronovost, P. J., and Fleisher, L. A. (2002). Systematic Review and Analysis of Postdischarge Symptoms after Outpatient Surgery. *Anesthesiology* 96, 994–1003. doi:10.1097/00000542-200204000-00030
- Yeh, C.-Y., Jao, S.-W., Chen, J.-S., Fan, C.-W., Chen, H.-H., Hsieh, P.-S., et al. (2017). Sebacyl Dinalbuphine Ester Extended-Release Injection for Long-Acting Analgesia. *Clin. J. Pain* 33, 429–434. doi:10.1097/ajp.0000000000000417

Conflict of Interest: The authors declare that the research was conducted in the absence of any commercial or financial relationships that could be construed as a potential conflict of interest.

Copyright © 2021 Liu, Ho and Wong. This is an open-access article distributed under the terms of the Creative Commons Attribution License (CC BY). The use, distribution or reproduction in other forums is permitted, provided the original author(s) and the copyright owner(s) are credited and that the original publication in this journal is cited, in accordance with accepted academic practice. No use, distribution or reproduction is permitted which does not comply with these terms.