



## OPEN ACCESS

## EDITED BY

Hem Chandra Jha,  
Indian Institute of Technology Indore, India

## REVIEWED BY

M. Badawy Abdel-Naser,  
New York University, United States  
Walter Belda,  
University of São Paulo, Brazil  
Marcela Saeb Lima,  
National Institute of Medical Sciences and  
Nutrition Salvador Zubirán, Mexico

## \*CORRESPONDENCE

Yang Liu

✉ shannon13579@163.com

RECEIVED 03 July 2024

ACCEPTED 02 September 2024

PUBLISHED 24 September 2024

## CITATION

Liu Z, Cao W and Liu Y (2024)  
Malignant acanthosis nigricans  
with oral manifestations in a  
young female: a case report  
and literature review.  
*Front. Oncol.* 14:1459148.  
doi: 10.3389/fonc.2024.1459148

## COPYRIGHT

© 2024 Liu, Cao and Liu. This is an open-access article distributed under the terms of the [Creative Commons Attribution License \(CC BY\)](https://creativecommons.org/licenses/by/4.0/). The use, distribution or reproduction in other forums is permitted, provided the original author(s) and the copyright owner(s) are credited and that the original publication in this journal is cited, in accordance with accepted academic practice. No use, distribution or reproduction is permitted which does not comply with these terms.

# Malignant acanthosis nigricans with oral manifestations in a young female: a case report and literature review

Zijian Liu<sup>1,2</sup>, Wuling Cao<sup>2</sup> and Yang Liu<sup>2\*</sup>

<sup>1</sup>Department of Periodontics, Stomatological Hospital of Xiamen Medical College & Xiamen Key Laboratory of Stomatological Disease Diagnosis and Treatment, Xiamen, China, <sup>2</sup>Department of Oral Medicine, Peking University School and Hospital of Stomatology & National Center for Stomatology & National Clinical Research Center for Oral Diseases & National Engineering Research Center of Oral Biomaterials and Digital Medical Devices, Beijing, China

**Introduction:** Almost all cases of malignant acanthosis nigricans with oral manifestations occurred in older age groups. Here, we report a case of malignant acanthosis nigricans in a young female presented with chief complaints of oral mucosal hyperplasia, who had previously been diagnosed with allergies.

**Case presentation:** A 30-year-old female developed oral hyperplasia and rash following seafood consumption, with subsequent resolution of the rash but persistent oral lesions and the appearance of pigmentation on her hands, neck, and axillae. Clinical examination revealed papillomatosis, hyperemia, and velvety hyperplasia in the oral cavity. Biopsy results confirmed papillary hyperplasia. Despite the patient's belief in good health, she was advised to undergo further systemic examinations. Elevated serum tumor markers and histologic analysis of an endoscopic biopsy confirmed gastric cancer with duodenal infiltration, leading to the diagnosis of malignant acanthosis nigricans. Unfortunately, the patient passed away due to heart failure during chemotherapy treatment.

**Conclusions:** The majority of patients with malignant acanthosis nigricans present with oral lesions before the underlying malignancy is detected, emphasizing the importance of timely comprehensive systemic examination. Furthermore, our case suggests that age may not be a restrictive factor for the development of malignant acanthosis nigricans, and the presence of a rash can potentially obscure the cutaneous manifestations associated with this condition.

## KEYWORDS

malignant acanthosis nigricans, malignancy, papillomatosis, velvety hyperplasia, gastric cancer, case report

## 1 Introduction

Acanthosis nigricans is a rare mucocutaneous disorder characterized by skin hyperpigmentation and thickening in specific regions, such as the neck, axillae, and groin (1). Additionally, some patients exhibit filiform growths on the oral mucosa (2), which bear resemblance to lesions induced by human papillomavirus.

There were several different classifications for acanthosis nigricans, with malignant acanthosis nigricans included in each of them (3–5). Malignant acanthosis nigricans is considered a paraneoplastic syndrome, associated with cancers of the stomach, ovary, bladder, breast, liver, and kidney (6). Mucous membrane involvement is indicative of the malignant form.

Here, we report a case of a patient presenting with filiform papillomas on oral mucosa who was ultimately diagnosed with malignant acanthosis nigricans. While malignant acanthosis nigricans has mainly been reported in older populations (7), the patient in this case was only 30 years old. She had confidence in her physical health and denied all relevant systemic symptoms at her initial visit.

## 2 Case report

A 30-year-old woman presented to the Oral Medicine Department of Peking University School and Hospital of Stomatology with a complaint of 4-month hyperplasia in the mouth. She recalled that the oral manifestation and skin eruptions occurred after consuming seafood and had previously been diagnosed with atopic dermatitis at other institutions. The rash resolved after treatment, whereas pigmentation appeared on the hands, neck, and axillae. However, there was no improvement in the oral lesions. The patient underwent laboratory tests (blood routine, blood biochemistry, erythrocyte sedimentation rate, ANA spectrum, and T-cell subtype), and the results were all within normal ranges. The patient denied weight loss, a history of cancer, drug use, diabetes, unconventional sexual contact, venereal disease, and other endocrine disorders.

Oral examination results identified papillomatosis on the lips, hard palate mucosa, and gingiva with apparent hyperemia. Velvety hyperplasia was observed on the buccal mucosa and the dorsum of the tongue. Dermatological examination showed hyperpigmentation on the neck, axillae, and hands (Figure 1). Biopsies were performed on the lower lip and axillae, revealing papillary hyperplasia (Supplementary Figure S1).

The patient underwent a systemic examination for underlying malignancy. Enhanced computed tomography results showed gastric wall thickening in the angle and enlarged lymph nodes in the lesser curvature, suggesting a possibility of gastric cancer (Supplementary Figure S2). Gastroscopy examination results showed ulcers and papillary hyperplasia on the gastric wall and esophagus (Figures 2A, B). Histologic analysis of endoscopic biopsy confirmed gastric carcinoma with duodenal infiltration (Figures 2C, D). Immunohistochemistry results showed cytokeratin-7 (CK7) (+++), cytokeratin-20 (CK20) (+++), mucin-5 (MUC5) (+++), and caudal type homeobox 2 (CDX2) (+++), indicating primary gastric adenocarcinoma (poorly differentiated). Levels of serum tumor

markers, including carcinoembryonic antigen (11.25 ng/mL, normal range: <5.0 ng/mL), carbohydrate antigen 19-9 (>1,000 U/mL, normal range: <37.0 U/mL), carbohydrate antigen 125 (165.30 U/mL, normal range: <35.0 U/mL), carbohydrate antigen 72-4 (57.87 U/mL, normal range: <6.9 U/mL), and tissue polypeptide antigen (2236.00 U/L, normal range: <120 U/L), were significantly elevated.

The diagnosis of malignant acanthosis nigricans was established. The patient received chemotherapy for the metastatic gastric carcinoma. Unfortunately, the patient died of heart failure during the treatment period. The timeline of the patient's condition, medical visits, and outcome is presented in Figure 3.

## 3 Discussion

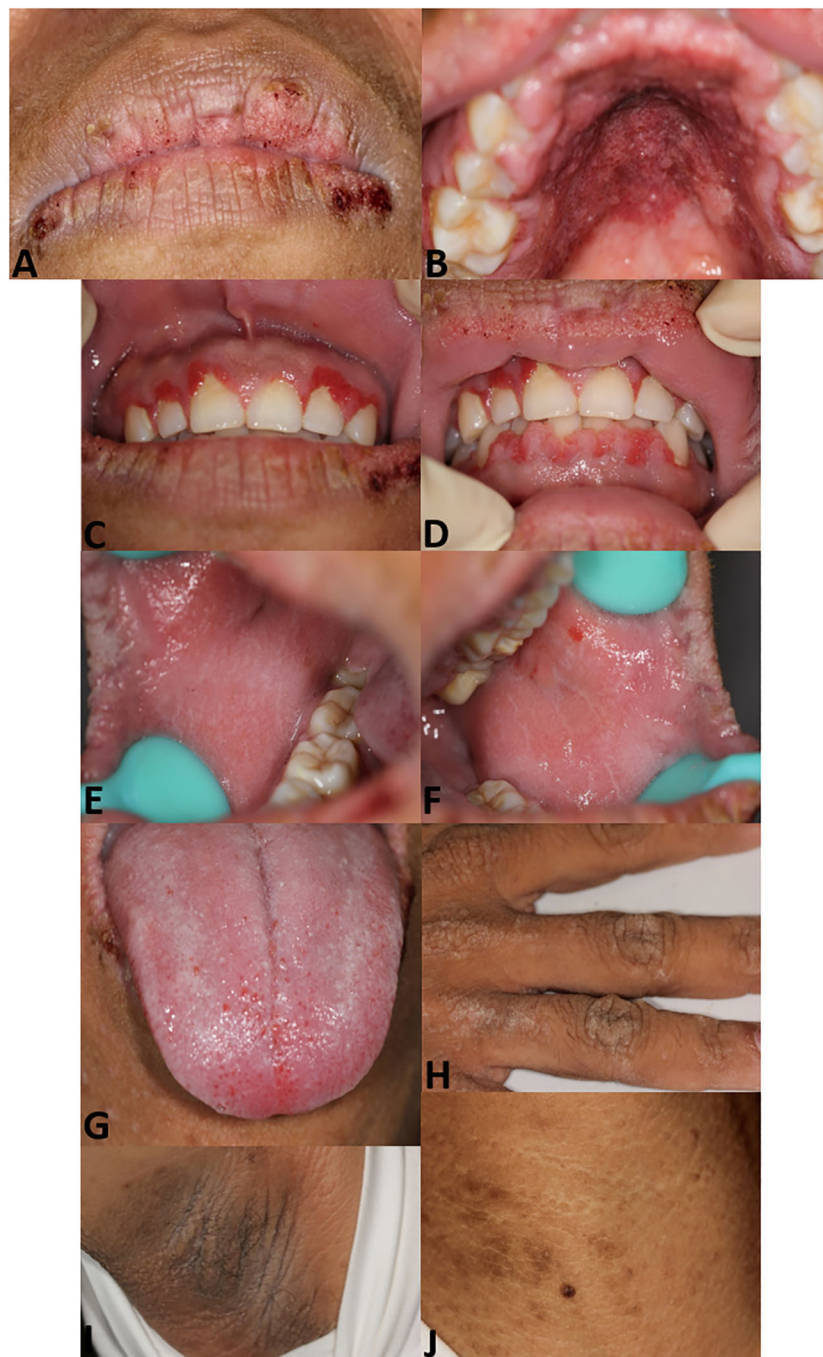
Malignant acanthosis nigricans in young populations is rare. In this report, we present a case of malignant acanthosis nigricans with multiple papillomatous and velvety oral lesions in a young female. Upon systemic examination, gastric cancer was detected. To the best of our knowledge, this is the first reported case of a young individual with malignant acanthosis nigricans presenting primarily with oral manifestations.

The differential diagnosis of acanthosis nigricans on oral mucosa holds particular importance for patient prognosis. Similar oral changes may occur in inflammatory papillary hyperplasia and HPV infection. Inflammatory papillary hyperplasia primarily presents as multiple small fibrous papillary growths, usually caused by wearing dentures and candidiasis, visible mainly on the denture-bearing hard palate (8). HPV-13 and HPV-32 infection can lead to multifocal, verrucous papules of the lips, buccal mucosa, and tongue (9), whereas HPV-6 and HPV-11 infections manifest as nodular or stalky masses with papillary surfaces (10). HPV tests help exclude these diseases.

Some skin disorders and syndromes also present with oral papillary lesions. Cowden syndrome (11) and ectrodactyly–ectodermal dysplasia–clefting syndrome (12) showed no evidence of skin hyperpigmentation. Linear epidermal nevus (13) and sebaceous nevus syndrome (14) can present both oral and cutaneous lesions resembling our case. The main point of differential diagnosis is that verrucous papules or pigmentation in these diseases appear in a linear configuration along skin tension lines. Focal dermal hypoplasia (15) is characterized by developmental disorders in multiple tissues and organs. Compared to this case, the above syndrome exhibits relatively small-range oral lesions, limited areas of skin lesions, and lighter pigmentation, with a tendency for family history. Specific genetic tests help make a correct diagnosis.

Extensive areas of papillary growth in oral mucosa and skin pigmentation in folds suggested that the patient might have acanthosis nigricans. Given that the benign and malignant forms of acanthosis nigricans can hardly be distinguished by mucocutaneous examination alone (2), we advised a thorough examination despite the young patient's lack of discomfort, pain, or weight loss. This led to the discovery of gastric adenocarcinoma.

It is worth mentioning that Krawczyk (16) previously reported a case of papular rash with excessive keratosis, skin discoloration, and



**FIGURE 1**

Patient images. Papillomatosis with scab on lips (A). Papillomatosis on hard palate mucosa with hyperemia (B). Papillomatosis on gingiva (C, D). Velvety hyperplasia on right (E) and left buccal mucosa (F). Velvety verrucous hyperplasia on the dorsum of the tongue and swelling of lingual papilla (G). Hyperpigmentation on the hand (H), axillae (I), and neck (J).

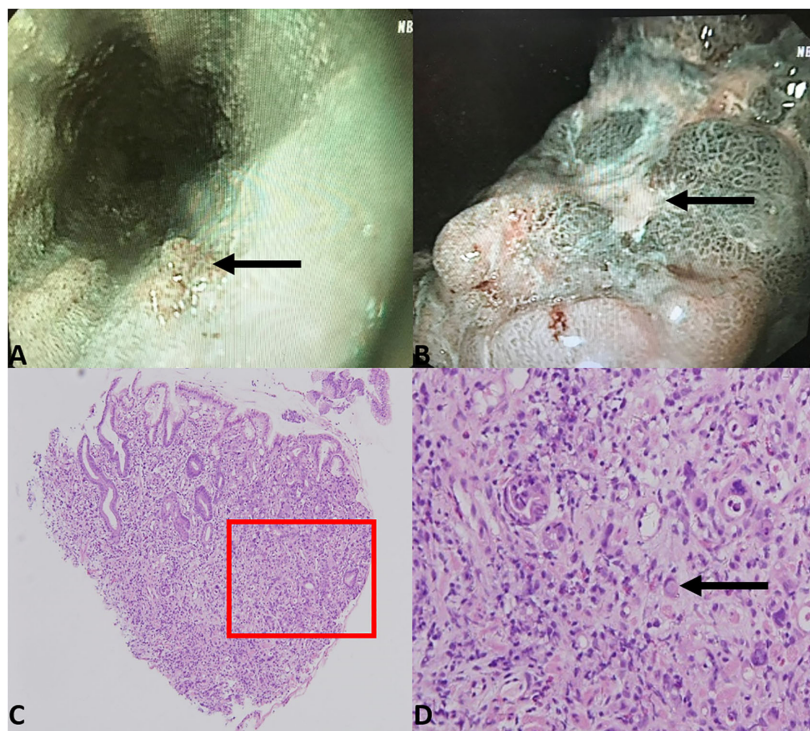
pruritus occurring simultaneously. Our patient also presented with a rash and was diagnosed with “allergy”. The presence of rash with excessive keratosis, oral papillary growth, and other manifestations should be carefully evaluated by clinicians to avoid overlooking the symptoms of malignant acanthosis nigricans.

Ramirez-Amador documented 12 cases of malignant acanthosis nigricans with oral manifestations prior to 1999 (17). Our literature review identified 23 additional cases since then. Nearly all reported cases

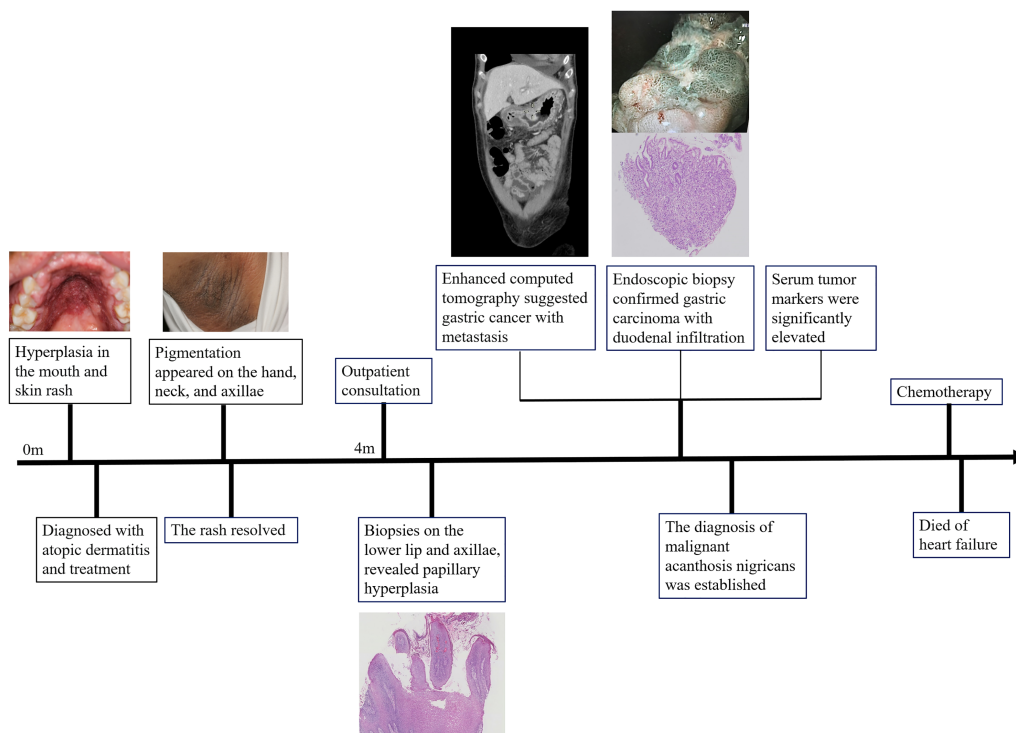
involved patients older than 40 years. Papillomatosis emerged as the most prevalent oral manifestation, observed in 72.2% of cases, primarily affecting the lips. Among these malignancies, 42% were gastric cancers. Notably, 59.1% of patients exhibited oral lesions preceding the diagnosis of the malignancy. We present the cases in [Table 1](#) and summarize them in [Supplementary Figure S3](#).

In conclusion, a significant percentage of malignant acanthosis nigricans patients exhibited oral lesions prior to the detection of the





**FIGURE 2** Gastroscopy examination results showed papillary hyperplasia of the lower part of the esophagus (A) and rugged gastric angle posterior wall with ulcer (B). Biopsy of the gastric angle revealed atypical tumor cells infiltrating the lamina propria of the gastric mucosa, with Lauren classification indicating a mixed type (C) 40x magnification). Localized signet ring cell carcinoma was observed (D) 200x magnification).



**FIGURE 3** Timeline.

TABLE 1 Malignant acanthosis nigricans with oral manifestation literature search (1999–2024).

Reference	Age, years	Sex	Duration, months	Chief complaint	Oral mucosa		Cutaneous		Oral manifestation before/after cutaneous	Underlying malignancy	Diagnosis before/after malignancy detected
					Manifestation	Site	Manifestation	Site			
	30	F	4	Allergy	Papillomatosis and velvety hyperplasia	Lips, buccal mucosa, gingiva, hard palate mucosa, and tongue	Hyperpigmentation	Neck, axillae, and hands	Before	Gastric adenocarcinoma	Before
Liu et al., 2024 (18)	67	F			Velvety and papillary lesions	Upper lip, buccal mucosa, gingiva, and hard palate	Pigmentation	Around the mouth, neck, hands, and around the armpits		Ovarian cancer	Before
Al-Zahawi et al., 2024 (19)	58	F			Thickening	Lips and oral mucosa	Hyperpigmented and velvety thickening	Nose, neck, axilla, groins, palms, and soles		Gastric adenocarcinoma	After
Fayne et al., 2023 (20)	87	F	4	Verrucous papules	Verrucous papules coalescing into plaques	Upper lip, buccal mucosa, hard palate, tongue, and posterior aspect of the oropharynx	Verrucous papules coalescing into plaques	Left eyelid margin	After	Urothelial carcinoma	After
Yun et al., 2022 (21)	41	M	4		Hyperpigmentation	Lips	Hyperpigmented and pruritic plaques	Neck, axillae, and hands	After	Pancreatic neuroendocrine tumor	After
Zhang et al., 2021 (7)	71	F	4	Burning sensation	Hypertrophic lesions and papillomatosis	Buccal mucosa, gingiva, and tongue	Hyperpigmentation, thickened skin, and mild pruritus	Face, hands, feet, fold areas, and axillary and inguinal regions	After	Urinary bladder cancer	After
Rizwan et al., 2019 (22)	62	M	8		Velvety verrucous plaques	Lips, buccal mucosa, and hard palate	Hyperpigmentation, papular lesions, and velvety and hyperkeratotic plaques	Scalp, face, neck, lower abdomen, limbs, palms, and instep of soles		Hepatic ductal undifferentiated malignant neoplasm	After
Yu et al., 2017 (6)	74	M	7		Florid papillomatosis	Buccal mucosa	Hyperkeratotic plaques	Face, dorsal skin of fingers, and heels	Before	Gastric cardia tubular adenocarcinoma	Before
Wang et al., 2017 (23)	41	M			Verrucous lesions	Lips, buccal mucosa, and tongue	Hyperpigmented and thickened areas	Axillae and hands		Gastric adenocarcinoma	After
Karakas et al., 2016 (24)	55	M	3	Oral mucosal ulcers	Multiple mucosal oral ulcers		Hyperpigmented and velvety skin lesions	Lower and upper extremities, face, palms, axillary, inguinal, and anal regions		Squamous cell lung cancer	Before

(Continued)

TABLE 1 Continued

Reference	Age, years	Sex	Duration, months	Chief complaint	Oral mucosa	Site	Cutaneous	Site	Oral manifestation before/after cutaneous	Underlying malignancy	Diagnosis before/after malignancy detected
					Manifestation		Manifestation				
Lee et al., 2015 (25)	70	F		Warty growths, oral discomfort, and difficulty eating	Papillomatosis	Lips, palate, and tongue	Verrucous or velvety pigmented plaques	Axillae, posterior neck, periumbilical region, and groin		Renal urothelial carcinoma	
Chu et al., 2014 (5)	59	F	3	Tumefaction lips	Scab and tumefaction	Lips	Hyperkeratotic and hyperpigmented skin, and velvety patchy lesions	Face, elbows, pudendum, groins, and axilla		Abdomen and pelvis metastases carcinoma	Before
Abu-Safieh et al., 2011 (26)	29	F	1		Blood oozing	Lips	Thickened, hyperpigmented, and warty skin	Axillae		Gastric adenocarcinoma	Before
Mignogna et al., 2009 (27)	74	F			Diffuse micropapillary lesions, “cerebriform” aspect	Inner upper lips, right cheek, and hard palate	Velvety rugose appearance	Palms and palmar surface of the fingers		Diffuse large B-cell lymphoma	Before
Krawczyk et al., 2009 (16)	44		2		Excessive keratosis and discoloration	Tongue	Excessive keratosis, skin discoloration, and pruritus	Trunk and axilla area	After	Gastrointestinal adenocarcinoma	After
Canjuga et al., 2008 (28)	78	F			Papillomatous growth	Lips, buccal mucosa, and hard palate	Verrucous changes and tiny pigmented macules	Right ear auricle		Bladder papillary transitional cell carcinoma	After
Schnopp et al., 2007 (29)	44	F	15		Papillomatosis, thickened and furrowed changes	Lips, buccal mucosa, and tongue	Darkening skin, small and velvety plaques	Neck	After	Gastric adenocarcinoma	Before
McGinness et al., 2006 (30)	81	F		Burning and soreness	Verrucous papillomatous papules and plaques	Lips, buccal mucosa, and tongue	Accentuation	Palms	Before	Pancreatic adenocarcinoma	Before
Pentenero et al., 2004 (31)	53	M		Sore palate	Thickened mucosa with a velvety and papillomatous surface	Lips, buccal mucosa and palate	Velvety rugose appearance, hyperkeratotic verrucous, pigmented, and brownish papules	Palms, back, and axillae		Gastric adenocarcinoma	After

(Continued)

TABLE 1 Continued

Reference	Age, years	Sex	Duration, months	Chief complaint	Oral mucosa	Cutaneous	Oral manifestation before/after cutaneous	Underlying malignancy	Diagnosis before/after malignancy detected	
					Manifestation					Site
Cairo et al., 2001 (32)	73	M		Burning sensation and pain	Papillomatosis	Vestibular mucosa, gingiva, palate, and dorsum of the tongue	Hyperpigmented and thickened skin	Neck, axillae, and the internal surface of the thighs	Lung carcinoma	Before
Scully et al., 2001 (33)	69	F	9	Painless gingival lesions	Swelling, increased stippling, and diffuse thickening	Lower labial mucosa, gingival, and palate but not the edentulous areas	Slightly keratotic, warty lesions, and florid seborrheic warts	Palms, soles, axillae, and proximal limbs	Cholangiocarcinoma	
Yeh et al., 2000 (34)	69	M	6		Papillomatous involvement		Thickened and hyperpigmented skin, papillomatous involvement, and seborrheic keratoses	Face, nape of the neck, axillae, groins, limbs, and trunk	Gastric adenocarcinoma	Before
Bottoni et al., 2000 (35)	80	M	12		Papillomatous and verrucous lesions	Lips and oral mucosa	Diffuse brownish hyperpigmentation, velvety thickening, and warty lesions	Neck, axillae groins, and limbs	Non-small cell lung carcinoma	Before
Ramirez et al., 1999 (17)	55	F	12	Sore palate	Painless extensive papillomatosis	Upper vermillion and lip mucosa, buccal mucosa, gingiva, palate, and dorsum of the tongue	Hair loss	Axillary, palpebral, and scalp	Gallbladder adenocarcinoma	Before

underlying malignancy. Therefore, clinicians, especially oral healthcare professionals, should remain vigilant. Detailed differential diagnosis is necessary, and a comprehensive systemic examination is required to facilitate early diagnosis of malignancies and improve patient prognosis. Furthermore, in contrast to previous cases, our patient was only 30 years old and considered herself to be in a healthy condition. This suggests that age may not be a restrictive factor for malignant acanthosis nigricans. On the other hand, the rash may coexist with skin and mucosal lesions, warranting that differentiation from allergies and clinical observations of mucosal manifestations after the regression of the rash are important.

## Data availability statement

The original contributions presented in the study are included in the article/Supplementary Material. Further inquiries can be directed to the corresponding author.

## Ethics statement

Written informed consent was obtained from the individual(s) for the publication of any potentially identifiable images or data included in this article.

## Author contributions

ZL: Data curation, Formal analysis, Funding acquisition, Investigation, Writing – original draft. WC: Data curation, Investigation, Writing – original draft. YL: Conceptualization, Funding acquisition, Supervision, Validation, Writing – review & editing.

## References

- Das A, Datta D, Kassir M, Wollina U, Galadari H, Lotti T, et al. Acanthosis nigricans: A review. *J Cosmet Dermatol.* (2020) 19:1857–65. doi: 10.1111/jocd.13544
- Kutlubay Z, Engin B, Bairamov O, Tüzün Y. Acanthosis nigricans: A fold (intertriginous) dermatosis. *Clin Dermatol.* (2015) 33:466–70. doi: 10.1016/j.clindermatol.2015.04.010
- Sinha S, Schwartz RA. Juvenile acanthosis nigricans. *J Am Acad Dermatol.* (2007) 57:502–8. doi: 10.1016/j.jaad.2006.08.016
- Eberling CL, Javor E, Gorden P, Turner ML, Cowen EW. Insulin resistance, acanthosis nigricans, and hypertriglyceridemia. *J Am Acad Dermatol.* (2005) 52:341–4. doi: 10.1016/j.jaad.2004.10.867
- Chu HW, Li JM, Chen GF, Ma JY. Oral Malignant acanthosis nigricans associated with endometrial adenocarcinoma. *Int J Oral Sci.* (2014) 6:247–9. doi: 10.1038/ijos.2014.1
- Yu Q, Li XL, Ji G, Wang Y, Gong Y, Xu H, et al. Malignant acanthosis nigricans: an early diagnostic clue for gastric adenocarcinoma. *World J Surg Oncol.* (2017) 15:208. doi: 10.1186/s12957-017-1274-5
- Zhang R, Jiang M, Lei W, Wang A. Malignant acanthosis nigricans with recurrent bladder cancer: A case report and review of literature. *Oncol Targets Ther.* (2021) 14:951–7. doi: 10.2147/ott.S290124
- Gual-Vaqués P, Jané-Salas E, Egado-Moreno S, Ayuso-Montero R, Mari-Roig A, López-López J. Inflammatory papillary hyperplasia: A systematic review. *Med Oral Patol Oral Cir Bucal.* (2017) 22:e36–42. doi: 10.4317/medoral.21405
- Said AK, Leao JC, Fedele S, Porter SR. Focal epithelial hyperplasia - an update. *J Oral Pathol Med.* (2013) 42:435–42. doi: 10.1111/jop.12009
- Lacey CJ, Woodhall SC, Wikstrom A, Ross J. 2012 European guideline for the management of anogenital warts. *J Eur Acad Dermatol Venereol.* (2013) 27:e263–70. doi: 10.1111/j.1468-3083.2012.04493.x
- Elo JA, Sun HH, Laudenbach JM, Singh HM. Multiple oral mucosal hamartomas in a 34-year old female. *Head Neck Pathol.* (2017) 11:393–8. doi: 10.1007/s12105-016-0777-7
- Mansur AT, Aydingöz IE, Kocaayan N. A case of EEC syndrome with peri/intraoral papillomatosis and widespread freckling. *J Dermatol.* (2006) 33:225–6. doi: 10.1111/j.1346-8138.2006.00052.x
- Haberland-Carrodeguas C, Allen CM, Lovas JG, Hicks J, Flaitz CM, Carlos R, et al. Review of linear epidermal nevus with oral mucosal involvement—series of five new cases. *Oral Dis.* (2008) 14:131–7. doi: 10.1111/j.1601-0825.2006.01355.x
- Warnke PH, Russo PA, Schimmelpenninck GW, Happle R, Härle F, Hauschild A, et al. Linear intraoral lesions in the sebaceous nevus syndrome. *J Am Acad Dermatol.* (2005) 52:62–4. doi: 10.1016/j.jaad.2004.05.046

## Funding

The author(s) declare financial support was received for the research, authorship, and/or publication of this article. This work was supported by the Fujian Provincial Health Technology Project (2022QNB027) and Program for New Clinical Techniques and Therapies of Peking University School and Hospital of Stomatology (PKUSSNCT-23A05). The funders had no role in the study design, data collection and analysis, and decision on publication or manuscript preparation.

## Conflict of interest

The authors declare that the research was conducted in the absence of any commercial or financial relationships that could be construed as a potential conflict of interest.

## Publisher's note

All claims expressed in this article are solely those of the authors and do not necessarily represent those of their affiliated organizations, or those of the publisher, the editors and the reviewers. Any product that may be evaluated in this article, or claim that may be made by its manufacturer, is not guaranteed or endorsed by the publisher.

## Supplementary material

The Supplementary Material for this article can be found online at: <https://www.frontiersin.org/articles/10.3389/fonc.2024.1459148/full#supplementary-material>



15. Wright JT, Puranik CP, Farrington F. Oral phenotype and variation in focal dermal hypoplasia. *Am J Med Genet C Semin Med Genet.* (2016) 172c:52–8. doi: 10.1002/ajmg.c.31478
16. Krawczyk M, Mykała-Cieśla J, Kołodziej-Jaskuła A. Acanthosis nigricans as a paraneoplastic syndrome. Case reports and review of literature. *Pol Arch Med Wewn.* (2009) 119:180–3. doi: 10.20452/pamw.642
17. Ramirez-Amador V, Esquivel-Pedraza L, Caballero-Mendoza E, Berumen-Campos J, Orozco-Topete R, Angeles-Angeles A. Oral manifestations as a hallmark of Malignant acanthosis nigricans. *J Oral Pathol Med.* (1999) 28:278–81. doi: 10.1111/j.1600-0714.1999.tb02039.x
18. Liu Y, Wu X, Chen S, Meng W. Oral Malignant acanthosis nigricans: an early diagnostic sign for ovarian carcinoma: A case report. *Clin Cosmet Investig Dermatol.* (2024) 17:359–63. doi: 10.2147/ccid.S447977
19. Al-Zahawi S, Sadeghi Y, Azhari V, Mahmoudi H, Daneshpazhooh M. Bullous pemphigoid, Malignant acanthosis nigricans, and erysipeloid carcinoma in a woman with gastric adenocarcinoma. *Clin Case Rep.* (2024) 12:e8351. doi: 10.1002/ccr.3.8351
20. Fayne R, Mervak JE. Correlated improvement of mucosal Malignant acanthosis nigricans and metastatic urothelial carcinoma with oncologic therapy. *JAAD Case Rep.* (2023) 37:35–7. doi: 10.1016/j.jidcr.2023.05.003
21. Yun JSW, McCormack C, Goh M, Chiang C. Acanthosis nigricans in a patient with metastatic insulinoma post peptide receptor radionuclide therapy. *Endocrinol Diabetes Metab Case Rep.* (2022) 2022. doi: 10.1530/edm-21-0150
22. Rizwan M, Iftikhar N, Sarfraz T, Ullah O. Malignant acanthosis nigricans: an indicator of internal Malignancy. *J Coll Physicians Surg Pak.* (2019) 29:888–90. doi: 10.29271/jcpsp.2019.09.888
23. Wang L, Long H, Wen H, Liu Z, Ling T. Image Gallery: Generalized mucosal and cutaneous papillomatosis, a unique sign of Malignant acanthosis nigricans. *Br J Dermatol.* (2017) 176:e99. doi: 10.1111/bjd.15396
24. Karakas Y, Esin E, Lacin S, Ceyhan K, Heper AO, Yalcin S. A case of acanthosis nigricans as a paraneoplastic syndrome with squamous cell lung cancer. *Onco Targets Ther.* (2016) 9:4815–20. doi: 10.2147/ott.S95020
25. Lee HC, Ker KJ, Chong WS. Oral Malignant acanthosis nigricans and tripe palms associated with renal urothelial carcinoma. *JAMA Dermatol.* (2015) 151:1381–3. doi: 10.1001/jamadermatol.2015.2139
26. Abu-Safieh Y, Khelfa S. Acanthosis nigricans: A presentation of gastric adenocarcinoma. *Arab J Gastroenterol.* (2011) 12:156–7. doi: 10.1016/j.ajg.2011.04.001
27. Mignogna MD, Fortuna G, Falletti J, Leuci S. Gastric diffuse large B-cell lymphoma (DLBCL) exhibiting oral acanthosis nigricans and tripe palms. *Dig Liver Dis.* (2009) 41:766–8. doi: 10.1016/j.dld.2009.02.049
28. Canjuga I, Mravak-Stipetić M, Kopic V, Galic J. Oral acanthosis nigricans: case report and comparison with literature reports. *Acta Dermatovenerol Croat.* (2008) 16:91–5.
29. Schnopp C, Baumstark J. Images in clinical medicine. *Oral acanthosis nigricans* *N Engl J Med.* (2007) 357:e10. doi: 10.1056/NEJMicm062917
30. McGinness J, Greer K. Malignant acanthosis nigricans and tripe palms associated with pancreatic adenocarcinoma. *Cutis.* (2006) 78:37–40.
31. Pentenero M, Carozzo M, Pagano M, Gandolfo S. Oral acanthosis nigricans, tripe palms and sign of Leser-Trélat in a patient with gastric adenocarcinoma. *Int J Dermatol.* (2004) 43:530–2. doi: 10.1111/j.1365-4632.2004.02159.x
32. Cairo F, Rubino I, Rotundo R, Prato GP, Ficarra G. Oral Acanthosis nigricans as a marker of internal Malignancy. A case report. *J Periodontol.* (2001) 72:1271–5. doi: 10.1902/jop.2000.72.9.1271
33. Scully C, Barrett WA, Gilkes J, Rees M, Sarnar M, Southcott RJ. Oral acanthosis nigricans, the sign of Leser-Trélat and cholangiocarcinoma. *Br J Dermatol.* (2001) 145:506–7. doi: 10.1046/j.1365-2133.2001.04393.x
34. Yeh JS, Munn SE, Plunkett TA, Harper PG, Hopster DJ, du Vivier AW. Coexistence of acanthosis nigricans and the sign of Leser-Trélat in a patient with gastric adenocarcinoma: a case report and literature review. *J Am Acad Dermatol.* (2000) 42:357–62. doi: 10.1016/s0190-9622(00)90112-9
35. Bottoni U, Dianzani C, Pranteda G, Innocenzi D, De Giacomo P, Balzani A, et al. Florid cutaneous and mucosal papillomatosis with acanthosis nigricans revealing a primary lung cancer. *J Eur Acad Dermatol Venereol.* (2000) 14:205–8. doi: 10.1046/j.1468-3083.2000.00051.x