



OPEN ACCESS

EDITED BY

Hiroyuki Tomita,
Gifu University, Japan

REVIEWED BY

Juan Piñeiro-Maceira,
Rio de Janeiro State University, Brazil
Pio Zeppa,
University of Salerno, Italy

*CORRESPONDENCE

Guojie Wang
wanggj5@mail.sysu.edu.cn
Jie Zhang
zhangjie201806@sina.com

[†]These authors have contributed
equally to this work

SPECIALTY SECTION

This article was submitted to
Cancer Imaging and
Image-directed Interventions,
a section of the journal
Frontiers in Oncology

RECEIVED 28 July 2022

ACCEPTED 13 October 2022

PUBLISHED 27 October 2022

CITATION

Wang G, Zhou X, Luo J, Hu Q and
Zhang J (2022) Case report: Malignant
proliferating trichilemmal tumor
of the thumb.
Front. Oncol. 12:1005206.
doi: 10.3389/fonc.2022.1005206

COPYRIGHT

© 2022 Wang, Zhou, Luo, Hu and
Zhang. This is an open-access article
distributed under the terms of the
Creative Commons Attribution License
(CC BY). The use, distribution or
reproduction in other forums is
permitted, provided the original
author(s) and the copyright owner(s)
are credited and that the original
publication in this journal is cited, in
accordance with accepted academic
practice. No use, distribution or
reproduction is permitted which does
not comply with these terms.

Case report: Malignant proliferating trichilemmal tumor of the thumb

Guojie Wang^{1*†}, Xuan Zhou^{2†}, Junqi Luo¹, Qiye Hu³
and Jie Zhang^{4*}

¹Department of Radiology, Fifth Affiliated Hospital of Sun Yat-sen University, Zhuhai, China,

²Department of Pathology, Fifth Affiliated Hospital of Sun Yat-sen University, Zhuhai, China,

³Department of Nuclear Medicine, Fifth Affiliated Hospital of Sun Yat-sen University, Zhuhai, China,

⁴Department of Radiology, Zhuhai People's Hospital, Zhuhai, China

Proliferating trichilemmal tumor is a very rare benign tumor that has the potential to transition into a malignant tumor. PTT most commonly affects the scalps of women above 60 years old and is frequently misdiagnosed due to its rarity. Herein, we present a case of a 68-year-old man with a malignant proliferating trichilemmal tumor on his right thumb. X-ray image showed a soft tissue mass on his thumb accompanied by bone destruction, while ¹⁸F-FDG PET revealed a hypermetabolic mass in the first index with axillary lymph node metastasis.

KEYWORDS

malignant proliferating trichilemmal tumor, finger, PET/CT, 18-FDG, pathology

Introduction

Proliferating trichilemmal tumor (PTT) is a benign neoplasia originating from the outer root sheath of hair follicles. PTT generally affects older women in the head and neck region and is often misdiagnosed (1, 2). Previous studies have linked trauma and/or inflammation to PTT (3). PTT are benign tumors that can become cancerous, termed malignant proliferating trichilemmal tumor (MPTT) (1, 3). Here, we present an unusual case of MPTT that was detected on the thumb of an elderly man.

Case report

A 68-year-old man was diagnosed with a soft tissue mass at the distal end of his right thumb that had been present for 6 months but was overlooked due to the mild symptoms. Two months prior to admission, the lesion showed rapid growth accompanied by persistent

dull pain. Physical examination revealed swelling at the distal segment of the thumb, local skin flushing, and slight tenderness.

X-ray imaging identified a mass at the distal part of the thumb with bone destruction (Figure 1). In addition, ^{18}F -FDG PET/CT examination revealed a significantly high metabolic activity in the thumb and right axillary lymph nodes (Figure 2).

Eventually, we surgically excised the lesion, which was approximately 5.5 cm \times 3.5 cm \times 3.0 cm in size. Light microscopy revealed that there are many clumps composed of epithelial cells under the skin. The clumps are lobulated, the outer cells are arranged in a palisade shape, and there is trichilemmal keratinization in the

center. Between outer cells and central trichilemmal keratinization, there are no granular layers. There are obvious cytological atypia and nuclear pleomorphism in the outer cells (Figure 3). Immunohistochemistry results were positive for P63, P40, CK14, and EMA, while the tumor cells were negative for CD34.

Taken together, the above findings support the diagnosis of MPTT. A needle biopsy performed on the right axillary lymph node confirmed the presence of metastatic MPTT. Adjuvant chemotherapy was planned after surgery, and the patient was discharged. After surgical resection, he was followed for 6 months, and there was no report of recurrence.

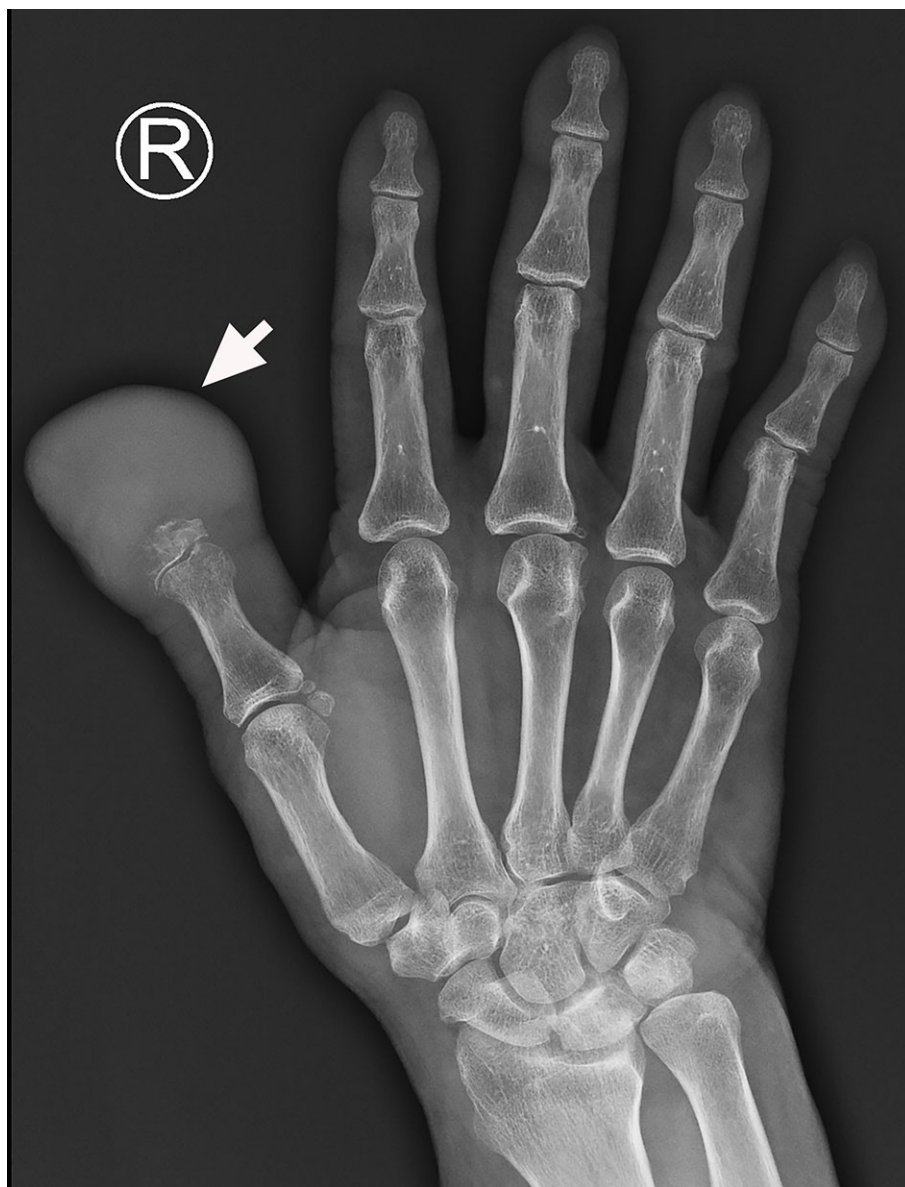

FIGURE 1
The X-ray image shows a mass at the distal end of the right thumb with marked phalanx destruction (arrow).

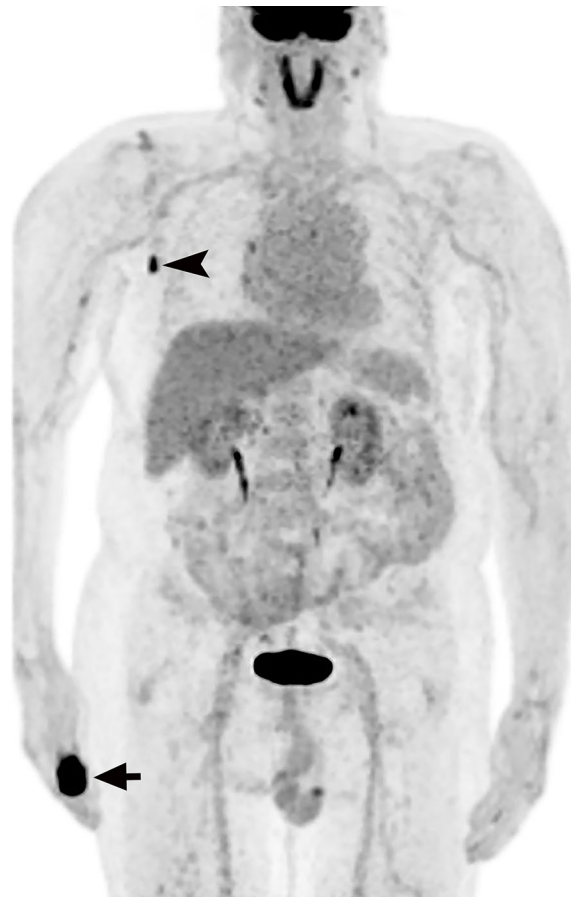


FIGURE 2
 ^{18}F -FDG PET reveals intense areas of ^{18}F -FDG uptake in the right thumb (arrow) and axillary lymph nodes (arrowhead).

Discussion

PTT are rare conditions that mainly occur in women above 60 years of age. Approximately 90% of cases occur on the scalp, with the remaining 10% located in regions such as the back, wrist, nose, and pudenda, to name a few (1). Even less common is PTT of the finger, which has been reported in the literature in only four cases. All four lesions were located in the subungual region (4–7). The researchers hypothesized that the subungual PTT was derived from the nail matrix, which could keratinize to a trichilemmal organization (5). PTT may also result from follicular units containing nail bed epithelium remaining in nails (8).

To the best of our knowledge, MPTT metastases have only been studied with ^{18}F -FDG PET in two patients previously (9, 10). In one case, ^{18}F -FDG PET was used to assess lymph node metastases caused by recurrent scalp MPTT (10). The other case

underwent ^{18}F -FDG PET/CT to investigate lymph node metastases of a shoulder MPTT (9). MPTT intensified glucose avidity was present in all cases, suggesting that ^{18}F -FDG PET may be useful in the workup of MPTT patients, especially in cases where the tumor's malignancy potential is not clear.

The pathology of PTT is characterized by trichilemmal keratinization without granular layers. Trichilemmal Cysts, PTT, and MPTT are tumors with differentiation of hair follicles, which have a continuous pedigree from benign to malignant, one end of the tumor is a cystic tumor with a clear boundary, and the other end has malignant characteristics. When the tumor grows rapidly, has invasive growth and distant metastasis, and has a large number of nuclear pleomorphisms and obvious cytological atypia, MPTT should be considered. CD34 is a marker of outer hair root sheath differentiation and is negative in MPTT, which is also the point of differentiation between PTT and MPTT. Desmoplastic trichilemmomas are

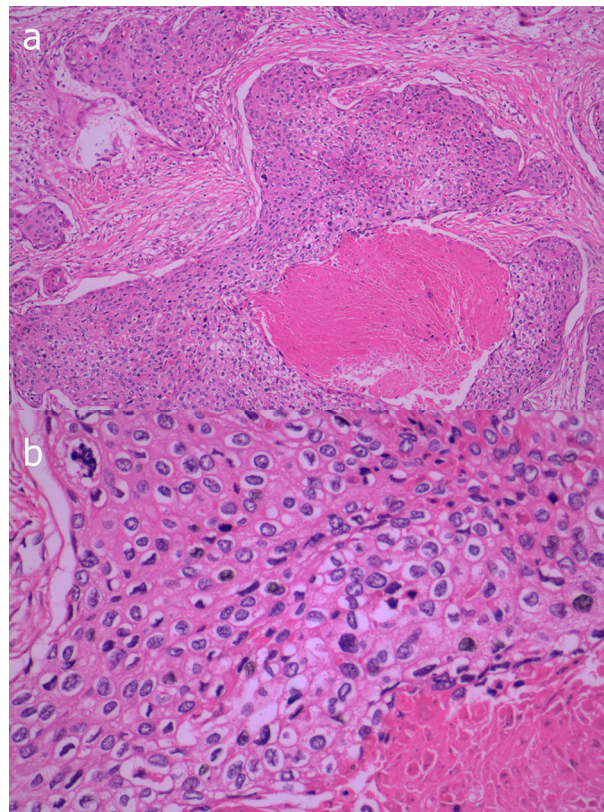


FIGURE 3

Photomicrograph shows many clumps composed of epithelial cells under the skin, the clumps are lobulated and the marginal cells are distributed in a palisade shape, with obvious keratinization in the center, but lacking a granular layer (A, HEx100). In the outer cells, there are obvious cytological atypia and nuclear pleomorphism (B, HEx400).

mostly found on the face, and similar to the trichilemmal tumor, it is characterized by subcutaneous tumor lobules and trichilemmal keratinization, and CD34 is positive. Furthermore, desmoplastic trichilemmomas have strips of epithelial cells growing at the edges (11). Trichilemmal keratinization is not seen in squamous cell carcinoma. Based on this, PTT can be differentiated from squamous cell carcinoma.

In conclusion, this is a rare case of MPTT in the thumb, and ^{18}F -FDG PET was useful in confirming axillary lymph node involvement in this rare neoplasia.

Data availability statement

The raw data supporting the conclusions of this article will be made available by the authors, without undue reservation.

Ethics statement

Written informed consent was obtained from the individual(s) for the publication of any potentially identifiable images or data included in this article.

Author contributions

GW, XZ, and JZ: manuscript writing. XZ: pathological review. GW, XZ, JL, QH, and JZ: manuscript revision. All authors contributed to the article and approved the submitted version.

Funding

This work was supported by the Science and Technology Program of Zhuhai (2220004000244) and the Medical Scientific Research Foundation of Guangdong Province(A2021449).

Conflict of interest

The authors declare that the research was conducted in the absence of any commercial or financial relationships that could be construed as a potential conflict of interest.

Publisher's note

All claims expressed in this article are solely those of the authors and do not necessarily represent those of their affiliated

organizations, or those of the publisher, the editors and the reviewers. Any product that may be evaluated in this article, or claim that may be made by its manufacturer, is not guaranteed or endorsed by the publisher.

References

1. Satyaprakash AK, Sheehan DJ, Sangüeza OP. Proliferating trichilemmal tumors: a review of the literature. *Dermatol Surg* (2007) 33(9):1102–8. doi: 10.1097/00042728-200709000-00011
2. Fieleke DR, Goldstein GD. Malignant proliferating trichilemmal tumor treated with mohs surgery: proposed protocol for diagnostic work-up and treatment. *Dermatol Surg* (2015) 41(2):292–4. doi: 10.1097/DSS.0000000000000269
3. Valerio E, Parro FHS, Macedo MP, et al. Proliferating trichilemmal cyst with clinical, radiological, macroscopic, and microscopic correlation. *Bras Dermatol* (2019) 94(4):452–4. doi: 10.1590/abd1806-4841.20198199
4. Melikoglu C, Eren F, Keklik B, et al. Trichilemmal cyst of the third fingertip: a case report. *Handb Surg* (2014) 19(1):131–3. doi: 10.1142/S0218810414720113
5. Kwon KE, Kim SJ, Kim JH, et al. Imaging sonographic findings of in a case of proliferating trichilemmal tumor of a finger: A case report. *J Clin Ultrasound* (2018) 46(3):215–7. doi: 10.1002/jcu.22500
6. El Hassani Y, Beaulieu JY, Tschanz E, et al. Localisation inhabituelle pulpaire d'un kyste trichilemmal proliférant [Proliferating trichilemmal tumor of the pulp of a finger: case report and review of the literature]. *Chir Main* (2013) 32(2):117–9. doi: 10.1016/j.main.2013.02.002
7. Ikegami T, Kameyama M, Orikasa H, et al. Trichilemmal cyst in the pulp of the index finger: a case report. *Handb Surg* (2003) 8(2):253–5. doi: 10.1142/S0218810403001765
8. Câmara de Oliveira M, Barcaui CB, Barcaui EO, et al. Melanonychia associated with subungual follicular inclusions: report of three cases. *Bras Dermatol* (2020) 95(2):217–20. doi: 10.1016/j.abd.2019.03.009
9. Leyendecker P, de Cambourg G, Mahé A, et al. 18F-FDG PET/CT findings in a patient with a proliferating trichilemmal cyst. *Clin Nucl Med* (2015) 40(7):598–9. doi: 10.1097/RLU.0000000000000742
10. Jung J, Cho SB, Yun M, et al. Metastatic malignant proliferating trichilemmal tumor detected by positron emission tomography. *Dermatol Surg* (2003) 29(8):872–4. doi: 10.1046/j.1524-4725.2003.29237.x
11. Afshar M, Lee RA, Jiang SI. Desmoplastic trichilemmoma—a report of successful treatment with mohs micrographic surgery and a review and update of the literature. *Dermatol Surg* (2012) 38(11):1867–71. doi: 10.1111/j.1524-4725.2012.02514.x