



# Corrigendum: Overexpression Cathepsin D Contributes to Perineural Invasion of Salivary Adenoid Cystic Carcinoma

Mei Zhang<sup>1,2,3</sup>, Jia-shun Wu<sup>1,2,3</sup>, Xiao Yang<sup>1,2,3</sup>, Xin Pang<sup>1,2,3</sup>, Li Li<sup>4</sup>, Sha-sha Wang<sup>1,2,3</sup>, Jing-biao Wu<sup>1,2,3</sup>, Ya-jie Tang<sup>5</sup>, Xin-hua Liang<sup>1,2,3</sup>, Min Zheng<sup>4\*</sup> and Ya-ling Tang<sup>1,2,3\*</sup>

## OPEN ACCESS

### Edited and reviewed by:

Christian Simon,  
Centre Hospitalier Universitaire  
Vaudois (CHUV), Switzerland

### \*Correspondence:

Min Zheng  
zmscedu@163.com  
Ya-ling Tang  
tangyaling@scu.edu.cn

### Specialty section:

This article was submitted to  
Head and Neck Cancer,  
a section of the journal  
Frontiers in Oncology

Received: 20 May 2021

Accepted: 02 June 2021

Published: 23 June 2021

### Citation:

Zhang M, Wu J-s, Yang X,  
Pang X, Li L, Wang S-s, Wu J-b,  
Tang Y-j, Liang X-h, Zheng M and  
Tang Y-l (2021) Corrigendum:  
Overexpression Cathepsin D  
Contributes to Perineural Invasion of  
Salivary Adenoid Cystic Carcinoma.  
*Front. Oncol.* 11:693392.  
doi: 10.3389/fonc.2021.693392

<sup>1</sup> State Key Laboratory of Oral Diseases, West China Hospital of Stomatology, Sichuan University, Chengdu, China,

<sup>2</sup> National Clinical Research Center for Oral Diseases, West China Hospital of Stomatology, Sichuan University, Chengdu, China, <sup>3</sup> Department of Oral and Maxillofacial Surgery, West China Hospital of Stomatology, Sichuan University, Chengdu, China, <sup>4</sup> Department of Stomatology, Zhoushan Hospital, Wenzhou Medical University, Zhoushan, China,

<sup>5</sup> Key Laboratory of Fermentation Engineering (Ministry of Education), Hubei Provincial Cooperative Innovation Center of Industrial Fermentation, Hubei Key Laboratory of Industrial Microbiology, Hubei University of Technology, Wuhan, China

**Keywords:** cathepsin D (CTSD), salivary adenoid cystic carcinoma (SACC), perineural invasion (PNI), invasion frontier, cytoskeletal organization

## A Corrigendum on

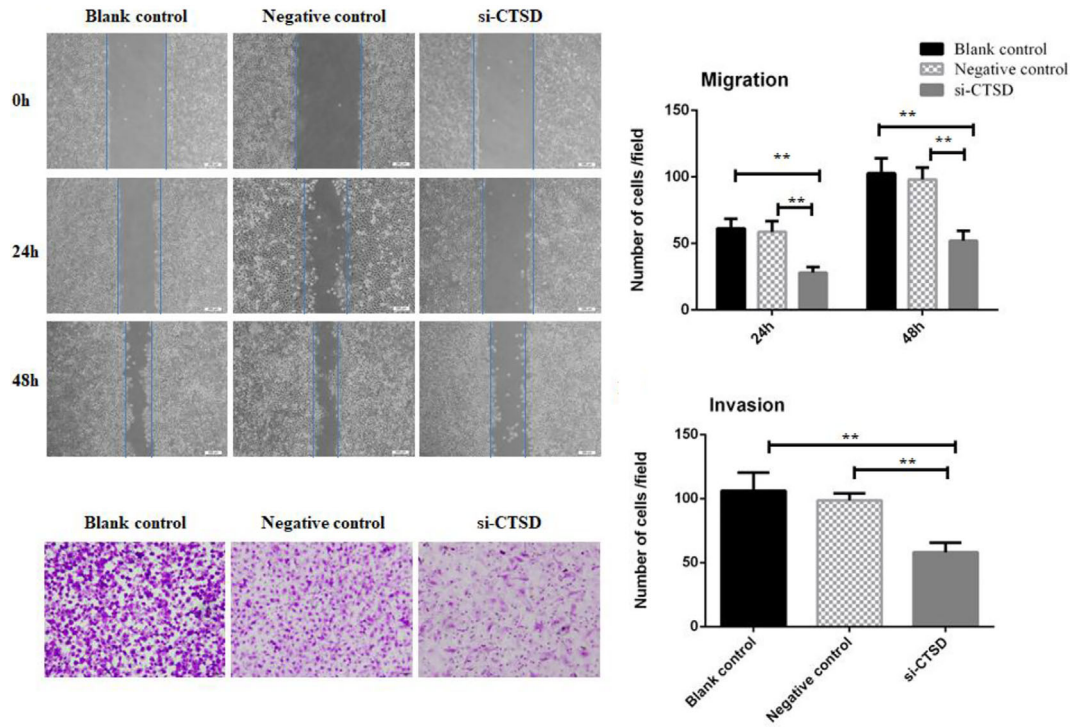
### Overexpression Cathepsin D Contributes to Perineural Invasion of Salivary Adenoid Cystic Carcinoma

By Zhang M, Wu J, Yang X, Pang X, Li L, Wang S, Wu J, Tang Y, Liang X, Zheng M and Tang Y (2018). *Front. Oncol.* 8:492. doi: 10.3389/fonc.2018.00492

In the original article, there was a mistake in **Figure 4** as published. In **Figures 4A, C**, we put the wrong picture due to carelessness. The correct **Figure 4** appears below.

The authors apologize for this error and state that this does not change the scientific conclusions of the article in any way. The original article has been updated.

Copyright © 2021 Zhang, Wu, Yang, Pang, Li, Wang, Wu, Tang, Liang, Zheng and Tang. This is an open-access article distributed under the terms of the Creative Commons Attribution License (CC BY). The use, distribution or reproduction in other forums is permitted, provided the original author(s) and the copyright owner(s) are credited and that the original publication in this journal is cited, in accordance with accepted academic practice. No use, distribution or reproduction is permitted which does not comply with these terms.



**FIGURE 4** | Effect of CTSD on migration and invasion of SACC-LM cells. **(A, B)** Scratch wound healing assay showed that CTSD knockdown inhibited the migratory ability of SACC-LM cells, (200 $\times$ ). **(C, D)** Transwell invasion assay showed that CTSD knockdown inhibited the invasive ability of SACC-LM cells, (200 $\times$ ) (\*\* $p < 0.01$ ).