

Management of cytotoxic chemotherapy-induced hand-foot syndrome

Johannes J.M. Kwakman,¹ Yannick S. Elshot,² Cornelis J.A. Punt,¹ Miriam Koopman³

¹Department of Medical Oncology, Amsterdam UMC, University of Amsterdam, Amsterdam; ²Department of Dermatology, Amsterdam UMC, University of Amsterdam, Amsterdam; ³Department of Medical Oncology, University Medical Center Utrecht, Utrecht University, Utrecht, the Netherlands

Abstract

Improvements in systemic cancer treatments have resulted in more patients surviving for prolonged periods of time on treatment. This has made treatment-related toxicity and quality of life concerns increasingly relevant. Hand-foot syndrome (HFS) is a common skin reaction to systemic therapy that should be anticipated with chemotherapeutic treatments such as pegylated liposomal doxorubicin, docetaxel, and fluoropyrimidines. In this review we discuss current knowledge of the diagnosis, incidence, pathogenesis, and management of hand-foot syndrome (HFS). Although HFS is not life threatening, it can cause significant discomfort and impairment of function, especially in elderly patients, and may seriously impact quality of life. The incidence of HFS is depend-

ent on the chemotherapeutic drug used, the treatment schedule, and the median duration of treatment. Effective measures for prevention and treatment of HFS include systemic and topical treatments, dose reductions, and switching to other drugs in the same class that are associated with lower rates of HFS. These approaches allow patients to continue cancer treatment while reducing negative impacts on quality of life. Awareness and early recognition are important to ensure timely treatment and avoidance of dose reductions or treatment discontinuation. We provide useful recommendations to guide the management of HFS in clinical practice.

Introduction

In the last two decades, considerable advances have been made in anti-cancer treatment. With the availability of an increasing number of systemic treatment options, and with more patients surviving for prolonged periods of time on treatment, treatment-related toxicities have become increasingly relevant. A commonly observed toxicity is hand-foot syndrome (HFS).

HFS, also known as palmar-plantar erythrodysesthesia syndrome, acral erythema, Burgdorf's syndrome, and more recently grouped with the so-called toxic erythema of chemotherapy syndromes, is a relatively common skin reaction to chemotherapy. It is initially characterized by palmoplantar numbness, tingling, or burning pain. These symptoms usually coincide with sharply demarcated erythema with or without edema, cracking, or desquamation. In advanced stages, blistering and ulceration may occur. The lateral parts and distal fat pads of the palms tend to be affected before the soles of the feet. In individuals with skin of color (Fitzpatrick skin types V-VI), HFS may present as macular hyperpigmentation instead of erythema. Symptoms may vary from relatively painless to severely painful.^{1,2} Also, the loss of fingerprint quality due to HFS may pose patients who travel internationally to significant difficulties.³

The drugs that are most commonly associated with HFS are pegylated liposomal doxorubicin (PLD), docetaxel, and fluoropyrimidines such as intravenous 5-fluorouracil (5-FU), capecitabine, and S-1. Clinical symptoms recur with repeated exposure and diminish after the drug is discontinued. Drugs that are administered on a continuous dosing schedule, such as continuous infusion 5-FU, or drugs which maintain high serum levels, such as capecitabine (an oral 5-FU prodrug) and PLD, are associated with increased risk of HFS compared to bolus or non-encapsulated forms of the same drug.⁴ Although HFS is not considered life threatening, it can be painful and interfere with daily activities, thereby seriously compromising quality of life (QoL).⁵

In this review, the differential diagnosis, grading systems, reported incidence of different drugs and schedules, pathogenesis, and current management strategies of HFS will be discussed.

Correspondence: Johannes J.M. Kwakman, Amsterdam UMC, University of Amsterdam, Department of Medical Oncology, room F4-224; P.O. Box 22660, 1100 DD Amsterdam, the Netherlands. Tel.: +31636155930. E-mail: j.j.kwakman@amc.uva.nl

Key words: Hand-foot syndrome; quality of life; fluoropyrimidines; doxorubicin; docetaxel.

Acknowledgements: Medical writing and editorial support for the preparation of the manuscript was provided by Dr. Wilko Coers, PhD, and Sandy Field, PhD, of Meducom BV, funded by Nordic Pharma BV, Netherlands.

Contributions: J.J.M.K. designed the overall study. J.J.K. and Y.S.E. collected and assembled the data. All authors contributed to the interpretation of data and writing of the manuscript. All authors gave their approval of the manuscript.

Conflict of interests: Prof dr CJA Punt and prof dr M Koopman received research grants from the Dutch Colorectal Cancer Group and Servier outside the submitted work; dr JJM Kwakman received personal fees from Nordic Pharma for the conduct of this review, and research grants and lecture fees from Servier and Nordic Pharma outside the submitted work; dr YS Elshot received personal fees from Nordic Pharma for the conduct of this review. Nordic Pharma had no role in the design or writing of the review.

Received for publication: 22 July 2019.
Accepted for publication: 19 April 2020.

This work is licensed under a Creative Commons Attribution NonCommercial 4.0 License (CC BY-NC 4.0).

©Copyright: the Author(s), 2020
Licensee PAGEPress, Italy
Oncology Reviews 2020; 14:442
doi:10.4081/oncol.2020.442

Differential diagnosis of hand-foot syndrome

When HFS is suspected, a number of differential diagnoses should be considered. These include allergic drug eruptions, contact dermatitis and eczema, vasculitis, erythema multiforme, erythromelalgia, and acral bleomycin toxicity. Graft-versus-host disease should be considered in the context of bone marrow transplantation, and infectious causes must be ruled out in immunosuppressed patients. PATEO syndrome, characterized by periarticular thenar erythema with onycholysis, should be differentiated from HFS upon treatment with docetaxel.⁶ When one or more chemotherapeutics are combined, for example a fluoropyrimidine and oxaliplatin, symptoms of HFS and sensory peripheral neuropathy may overlap, thereby complicating the diagnosis.

It is also important to differentiate HFS from hand-foot skin reaction (HFSR), a skin reaction to treatment that occurs in about 30% of patients on multikinase inhibitors such as sorafenib, sunitinib, axitinib, pazopanib, and regorafenib, and the BRAF inhibitors vemurafenib and dabrafenib.⁷ HFSR is characterized by painful, yellowish, hyperkeratotic plaques in high-pressure or high-friction areas such as the heels, fingertips, areas over the joints, and in the interdigital web spaces. HFSR plaques are often accompanied by numbness, tingling, and burning sensations. Unlike HFS, HFSR appears on the feet before the palms of the hands. Also, the two skin reactions have different histological features.^{7,8}

Grading of hand-foot syndrome

Grading the severity of HFS accurately is important as it guides clinical decision making in terms of applying dose delays, dose reductions, and other forms of therapeutic management. The World Health Organization (WHO) and the National Cancer Institute (NCI) classification systems are commonly used grading systems.^{2,4} The WHO system applies 4 grades of severity while the NCI system has 3 grades. Due to the fact that HFS appears to manifest differently in patients with skin of color, Saif *et al.* have proposed a third grading system that recommends different grading criteria for these patients (Table 1).¹

Effects on activities of daily living (ADL) are incorporated into the NCI grading system for HFS, underlining the potential impact of the syndrome on QoL. Sibaud *et al.* have developed and validated a 14-item questionnaire, the HFS-14, to more clearly assess the impact of HFS on patient QoL. The questionnaire has the potential to identify differences in QoL impact in patients with

the same grade of HFS. This tool may help to guide management and supportive care for patients on chemotherapy, potentially improving adherence and outcomes as well as measurement of HFS treatment efficacy.⁹ In a recent survey conducted among members of the Dutch Colorectal Cancer Group (DCCG), which included responses from 53 medical oncologists, the majority of respondents reported that grade 2 (85%) and 3 HFS (97%) have a significant impact on patient QoL.¹⁰ This highlights the importance of including QoL in the grading of HFS.

Incidence of hand-foot syndrome

The reported incidence of HFS varies depending on the chemotherapeutic drug, the treatment schedule, and the median duration of treatment. We present a concise overview of the reported incidence of HFS per chemotherapeutic agent.

Fluoropyrimidines

Fluoropyrimidines are used for the treatment of many solid tumor types, including colorectal, gastric, pancreatic, esophageal, breast, and head and neck cancer. Intravenous 5-FU, capecitabine, and S-1 have shown comparable efficacy results in various tumor types,^{11,12} but the toxicity profiles of the 3 agents are distinct, especially for HFS. The incidence of any grade HFS for intravenous 5-FU in phase 3 trials varies between 2.6% and 18%,¹³⁻¹⁷ while capecitabine is associated with rates of any grade HFS between 22% and 77%.^{15,18-22} Lastly, S-1 has a reported incidence ranging from 5.4% to 45%.^{17,21,23-25} Capecitabine is associated with the highest incidence of grade 3 HFS, reported in up to 28% of patients.¹⁸ The phase 3 SALTO study directly compared capecitabine and S-1, with the addition of bevacizumab in both arms as treatment option, as first-line treatment in metastatic colorectal cancer patients, with the incidence of HFS as primary endpoint. The incidence of any grade HFS was 73% and 45% for capecitabine and S-1, respectively. For grade 3 HFS, the incidence was 21% for capecitabine and 4% for S-1.²³ Since HFS was the primary endpoint in SALTO and the patient-assessed incidence was comparable to the investigator-assessed incidence, this probably accurately represents the incidence in clinical practice. Notably, the addition of bevacizumab to capecitabine-based treatment appears to increase the incidence and severity of HFS for reasons that are still unknown.^{18,23}

In the DCCG survey of medical oncologists who treat patients with colorectal cancer, 80% of respondents estimated that between 25% and 75% of their patients develop HFS while on a 5-fluo-

Table 1. Grading systems for hand-foot syndrome.

Grade	WHO	NCI	Grading for patients of color on capecitabine therapy
1	Dysesthesia/paresthesia, tingling in hands and feet.	Minimal skin changes or dermatitis (redness, swelling, hyperkeratosis) without pain.	Hyperpigmentation of palms and soles.
2	Discomfort in walking and/or in holding objects, painless swelling, redness.	Skin changes (peeling, blisters, bleeding, fissures, swelling, hyperkeratosis) with pain, limiting instrumental ADL.	Thickening of skin of palms and soles, with pain and loss of function.
3	Painful swelling and redness in palms and soles, and around fingernails and toenails.	Severe skin changes (peeling, blisters, bleeding, fissures, swelling, hyperkeratosis) with pain. Limiting self-care ADL.	Ulceration, dermatitis, or scaling.
4	Scaling, ulceration, blistering, severe pain.		

ADL, activities of daily living.

ouracil-based treatment and that capecitabine is the treatment they most commonly associate with HFS.¹⁰

Pegylated liposomal doxorubicin

PLD was designed for the treatment of Kaposi sarcoma and is also used in the treatment of breast and ovarian cancer. In metastatic breast cancer, the reported incidence of any grade HFS is as high as 48%.²⁶ In relapsed ovarian cancer, Pujade-Lauraine *et al.* reported an incidence of 39% for PLD in combination with carboplatin.²⁷ Several studies have shown that the incidence can be reduced by starting PLD at a lower dose, without compromising efficacy.^{28,29}

Docetaxel

Docetaxel is a taxane used for the treatment of breast, gastric, prostate, non-small cell lung, and head and neck cancer. The incidence of HFS upon treatment with docetaxel is not well-documented. Many case reports have been published, but larger clinical trials often do not report the incidence of HFS. Tagawa *et al.* investigated the safety of a number of generic docetaxel products and reported an incidence of any grade HFS ranging from 40% to 53%.³⁰

General treatment trends associated with hand-foot syndrome occurrence

It should be noted that HFS occurrence and severity is dependent upon multiple factors. First of all, the occurrence of HFS is dose-related and a higher cumulative dose is associated with a higher likelihood of developing HFS.²³ In metastatic colorectal cancer, recent data favor maintenance treatment with capecitabine and bevacizumab instead of a stop-and-go approach.³¹ Hence, patients are likely to be exposed to capecitabine, and thus its side-effects, for longer periods of time. Secondly, a combination of chemotherapeutics may worsen HFS-related symptoms. For example, peripheral neuropathy caused by a platinum compound may aggravate the sensibility complaints caused by HFS and vice versa. Finally, proactive management of HFS may help to prevent the syndrome from worsening into higher grades. This is reflected in data from the recent DCCG survey in which some clinicians report that they only see grade 1 or 2 HFS in their patients undergoing fluoropyrimidine treatment because preventive measures are applied to avoid higher grade events.¹⁰

Pathogenesis

The pathogenesis of HFS is poorly understood and it is hypothesized to be different for each class of drug. While the histology of HFSR shows a well-defined band of acantholytic dyskeratotic keratinocytes, histological assessment of HFS-affected areas shows a non-specific pattern that resembles that seen in other cytotoxic reactions. HFS exhibits a range of toxic skin damage varying from non-specific scattered keratinocyte necrosis with basal vacuolar degeneration to full necrosis of the epidermal layer and (sub)epidermal blistering. Inflammation at the dermo-epidermal junction with papillary dermal edema, blood vessel dilation, and a lymphocytic infiltrate have also been reported in addition to eccrine squamous syringometaplasia.³²⁻³⁴

The unique physiology of the palms and soles may provide some insight into why the effects of these drugs are focused on these areas. The palms and soles are highly vascular and have higher rates of division of skin cells than other skin areas, high concentrations of eccrine glands, and unique temperature modulation.³²⁻³⁴

In the case of PLD, the drug has been shown to surround both deep and superficial eccrine ducts and to permeate the stratum

corneum of the palms and soles upon infusion.³² The hydrophilic coating of the liposomes appears to cause drug accumulation in the eccrine ducts that are highly concentrated in the palms and soles. Experiments in animal models have suggested that interactions between doxorubicin and copper ions in the skin could generate reactive oxygen species in affected areas leading to keratinocyte apoptosis through activation of chemokine signaling pathways.³³

The mechanism for fluoropyrimidine-induced HFS appears to be related to the accumulation of 5-FU metabolites in the skin.³⁴ For capecitabine, it is hypothesized that high skin concentrations of one of the enzymes that break it down to the active 5-FU, thymidine phosphorylase, causes high localized toxic concentrations of 5-FU to be generated. Consistent with this idea, thymidine phosphorylase has been found to be more highly concentrated in the palms than in other skin areas. For both 5-FU and capecitabine, breakdown of 5-FU through the action of dihydropyrimidine dehydrogenase (DPD) has been implicated. However, while patients with DPD deficiency experience much more fluorouracil toxicity, particularly gastrointestinal and hematologic, they do not have higher rates of HFS.³⁵ On the other hand, S-1, which contains a DPD inhibitor and thus produces fewer metabolites, is associated with lower rates of HFS.³⁶ For capecitabine, it has been hypothesized that the drug and its breakdown products either directly or indirectly activate cyclooxygenase-2 (COX-2) inflammatory pathways to cause white blood cell infiltration, dilated blood vessels, and edema in tissues affected by HFS.³⁴

Management

Management of HFS in cancer treatment involves a combination of prevention, patient education, symptom amelioration, and dose intensity management. The most effective way to manage HFS once it has emerged is dose intensity modification in the form of a dose delay or dose reduction, or even treatment discontinuation, an unfortunate and undesirable occurrence during cancer treatment. Alternatively, patients can be switched to a better tolerated regimen.

Patient education and prevention of hand-foot syndrome

Prior to treatment with a chemotherapeutic agent that may cause HFS, preexisting skin conditions of the hands and feet should be treated and patients should be educated about preventive measures to reduce stress on skin areas. These measures include reducing skin friction by wearing loose-fitting clothes and shoes, avoidance of heat, the use of emollients and creams (while avoiding excessive rubbing of hands and feet), and rapid attention to any skin erosions that may predispose to infection. The implementation of a structured patient education program prior to treatment may increase the ability of patients to identify and manage HFS on their own.³⁷

Regional cooling using ice packs, ice water immersion, or frozen gloves or socks to cool hands and feet during treatment administration has demonstrated mixed success in reducing rates of HFS in cancer patients treated with infusional PLD or docetaxel. These methods are not applicable for drugs administered orally or by continuous infusion.³⁸⁻⁴⁰ A small prospective study including 53 patients with gynecologic cancers treated with PLD in combination with carboplatin showed a lower rate of any grade HFS in patients treated with ice packs on extremities during PLD infusion compared to no regional cooling (7% versus 36%; P=0.01).³⁹ Another study demonstrated reductions in nail toxicity but not skin

toxicity with the use of frozen gloves and socks in patients who received infusional docetaxel for various cancers.⁴⁰

The use of pyridoxine (vitamin B6) has been recommended for prevention of HFS due to the similarity of HFS symptoms to those of pyridoxine deficiency (acrodynia). However, the results of randomized trials on prophylaxis of HFS are conflicting. A meta-analysis including 890 patients treated with PLD, vincristine, capecitabine, cyclophosphamide, or 5-FU for breast, gastrointestinal, hematologic, or endometrial cancer that evaluated the efficacy of pyridoxine supplements compared to no treatment or placebo for the prevention of HFS did not demonstrate a significant reduction in the incidence of HFS (relative risk [RR]: 0.95, 95% confidence interval [CI] 0.87-1.05).⁴¹ A systematic review by Chen *et al.* including 607 patients from 5 randomized controlled trials treated with pyridoxine or placebo showed no significant difference between the two treatment groups for the incidence of HFS (RR: 0.96, 95% CI 0.86-1.06). Notably, a daily dose of 400 mg instead of 200 mg was associated with a preventive effect on developing grade 2 or higher HFS (RR: 0.55, 95% CI: 0.33–0.92).⁴² A more recent placebo-controlled trial that randomized 210 patients treated with capecitabine monotherapy did not observe a lower incidence of HFS for patients treated with pyridoxine (31.4%) compared to placebo (37.1%; $P=0.38$).⁴³

The prophylactic use of urea-based cream has shown to reduce the incidence of any grade HFSR compared to best supportive care (56% *versus* 74%; $P<0.001$) in 871 patients with hepatocellular carcinoma treated with sorafenib.⁴⁴ Unfortunately, randomized controlled trials assessing the effect of urea-based cream on the prevention on HFS have smaller sample sizes and results are not uniform. Wolf *et al.* randomized 137 patients with breast, colon or lung cancer between urea/lactic acid cream or placebo during the first three weeks of treatment with capecitabine. The incidence of grade 2 or 3 HFS, the primary endpoint, was not significantly different between groups (13.6% *versus* 10.2%, respectively; $P=0.77$).⁴⁵ In contrast, Hofheinz *et al.* compared the prophylactic use of urea cream or a medical ointment called Mapisal, which contains a variety of antioxidants and oil extracts, during the first six weeks of capecitabine treatment among 152 randomized patients with breast ($n=64$), colon ($n=82$) or esophagogastric cancer ($n=6$).⁴⁶ The incidence of any grade HFS was 39.5% in the Mapisal group and 22.4% in the urea cream group (odds ratio 2.37;

$P=0.02$). These results were contrary to the authors expectations, but may indicate that the application of urea-based cream is an effective strategy to prevent HFS.⁴⁶

Consistent with the theory that capecitabine and its metabolites induce COX-2-mediated inflammation, COX-2 inhibition was shown to be effective for the prevention of HFS.^{34,47,48} A systematic review of ten studies reported that administration of the COX-2 inhibitor celecoxib in combination with capecitabine can reduce the risk of HFS by about 50%.⁴⁹ However, more robust data are needed from large, double-blind trials to confirm its efficacy. Also, potential side effects including cardiovascular risks and upper gastrointestinal bleeding should be taken into account.^{50,51}

Symptom amelioration

The treatment of choice for symptomatic treatment of HFS is dependent upon the severity of symptoms and impacts on QoL. Systemic treatment options include COX-2 inhibitors, vitamin E, steroids (oral dexamethasone), and analgesics.^{48,52,53} Unfortunately, previous studies generally had small sample sizes with limited statistical power. Similarly, only a few randomized trials supporting the benefit of topical treatments are available. Current strategies may include emollients, topical corticosteroids, keratolytics, and sildenafil.⁵⁴⁻⁵⁶

In clinical practice, respondents to the DCCG survey reported that they recommend emollients, loose clothing and shoes, and refer their patients to the oncology nurse for guidance on prevention and treatment of HFS.¹⁰ In Table 2 we provide recommendations for preventive and symptomatic treatment of HFS based on available evidence and expert opinion.

Dose intensity management

Although treatment interruption or dose modification is the most effective strategy to reduce chemotherapy-induced HFS-related symptoms, particularly for moderate-to-severe grade HFS, it is an undesirable outcome that may affect efficacy outcomes. In a real-world study of 86 patients with metastatic colorectal cancer treated with capecitabine monotherapy, a dose reduction was applied in 22 patients (26%) and treatment was discontinued in 15 patients (17%) due to HFS.⁵⁷ In the SALTO trial, 10% of 81 patients treated with capecitabine discontinued treatment due to

Table 2. Preventive and symptomatic treatment options for hand-foot syndrome.

Preventative measures
Avoid mechanical stress/trauma (i.e. friction, pressure, tight footwear)
Avoid exposure to high temperatures around administration (e.g. bathing with hot water, vigorous exercise, wearing tight clothing and shoes)
Maintenance of good hygiene with regular visits to the podiatrist in case of corns and calluses
Referral to dermatologist for treatment of pre-existing dermatologic conditions
Moisturizing with urea-based cream three times per day (avoid excessive rubbing)
Local hypothermia (regional cooling) at time of administration (only for short-term infusions of PLD and docetaxel)
Symptomatic treatment
Pain: analgesics or topical anesthetics (lidocaine patches)
Inflammation: topical high-potency corticosteroids
Hyperkeratosis: topical keratolytics
Erosions: petroleum/lanolin-based ointments
NCI-CTC grade 2 or higher: oral celecoxib*
Other ^o : oral vitamin B6 (Pyridoxine) 400 mg, oral vitamin E, topical 99% dimethylsulfoxide (DSMU), topical sildenafil, oral corticosteroids

PLD, pegylated liposomal doxorubicin; NCI-CTC, National Cancer Institute criteria for classification. *Potential side effects include cardiovascular risks and upper gastrointestinal bleeding. ^oLimited or conflicting data.

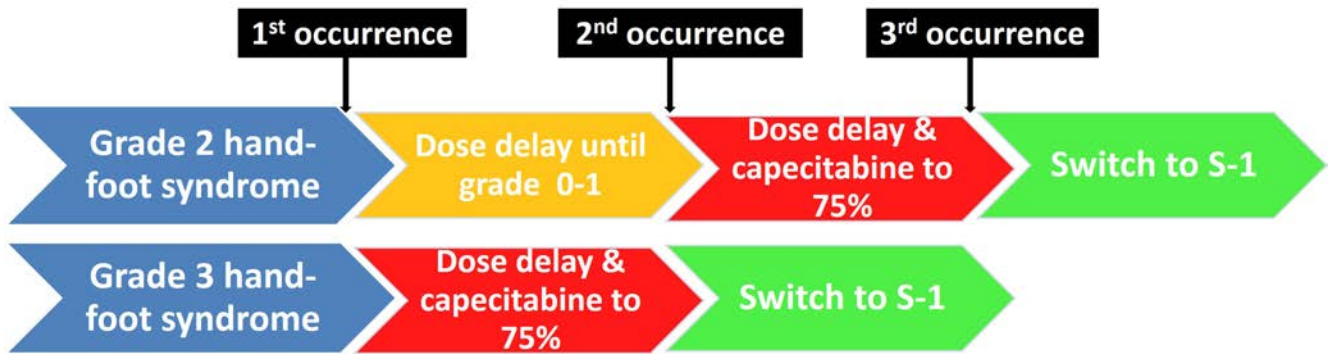


Figure 1. Flowchart for treatment management of capecitabine-induced hand-foot syndrome.

HFS.²³ In 254 breast cancer patients, PLD was discontinued due to HFS in 7% of patients.²⁶ A general approach for dose intensity management upon the first appearance of grade 2 or 3 HFS is treatment interruption until the event resolves or decreases in grade 1. Following grade 3 HFS, a dose reduction should be applied. Subsequent appearances of grade 2 or 3 HFS should be followed by treatment interruptions and dose reductions, and ultimately treatment discontinuation if severe HFS reoccurs at 50% of the recommended drug dose.

A more attractive strategy is to switch patients to a drug with a similar mechanism of action, comparable efficacy, and a lower incidence of HFS. For example, a retrospective study of 52 patients assessed the tolerability of S-1 in patients with grade 2 or 3 HFS due to capecitabine.⁵⁸ Upon switch to S-1, 94% of patients experienced a lower grade of HFS, with a complete resolution of HFS-related symptoms in 56% of patients. Based on the findings in this study, we recommend adhering to the treatment strategy as displayed in Figure 1 for clinical practice. Alternatively, patients with moderate to severe capecitabine-induced HFS can be switched to intravenous 5-fluorouracil, which is also associated with a lower incidence of HFS.²⁰ However, clinical data on this treatment approach are scarce.

In the DCCG survey, there was no broad consensus among medical oncologists regarding dose intensity management in colorectal cancer patients with fluoropyrimidine-induced grade 2 or 3 HFS. Approximately a third of the responders immediately apply a dose delay upon the first occurrence of grade 2 HFS. Also, 50% of the oncologists do not switch to another fluoropyrimidine when patients no longer tolerate treatment due to HFS.¹⁰

Conclusions

HFS occurs often, albeit sometimes only after repeated courses of treatment, and should be anticipated with specific chemotherapeutic drugs such as PLD, docetaxel, and fluoropyrimidines. HFS can have a serious impact on QoL and thus a patient's ability to continue or complete treatment. Awareness and early recognition are important to ensure timely treatment and avoidance of dose reductions or treatment discontinuation. Effective measures exist for prevention and treatment of HFS including systemic and topical treatments, dose reductions, and switching to other drugs in the same class that have lower rates of HFS. These approaches allow patients to continue cancer treatment while reducing negative impacts on QoL.

1. Saif MW, Elfiky AA. Identifying and treating fluoropyrimidine-associated hand-and-foot syndrome in white and non-white patients. *J Support Oncol* 2007;7:337-43.
2. CTCAE v5 November 27, 2017. Common Terminology Criteria for Adverse Events. National Cancer Institute. Available from: https://ctep.cancer.gov/protocolDevelopment/electronic_applications/ctc.htm#ctc_50.
3. Van Doorn L, Veelenturf S, Binkhorst L, et al. Capecitabine and the Risk of Fingerprint Loss. *JAMA Oncol* 2017;3:122-3.
4. Nagore E, Insa A, Sanmartin O. Antineoplastic therapy-induced palmar plantar erythrodysesthesia ('hand-foot') syndrome: incidence, recognition and management. *Am J Clin Dermatol* 2000;1:225-34.
5. Lassere Y, Hoff P. Management of hand-foot syndrome in patients treated with capecitabine (Xeloda). *Eur J Oncol Nurs* 2004;8 Suppl 1:S31-40.
6. Childress J, Lokich J. Cutaneous hand and foot toxicity associated with cancer chemotherapy. *Am J Clin Oncol* 2003;26:435-6.
7. Nikolaou V, Syrigos K, Saif MW. Incidence and implications of chemotherapy related hand-foot syndrome. *Expert Opin Drug Saf* 2016;15:1625-33.
8. Miller KK, Gorcey L, McLellan BN. Chemotherapy-induced hand-foot syndrome and nail changes: a review of clinical presentation, etiology, pathogenesis, and management. *J Am Acad Dermatol* 2014;71:787-94.
9. Sibaud V, Dalenc F, Chevreau C, et al. HFS-14, a specific quality of life scale developed for patients suffering from hand-foot syndrome. *Oncologist* 2011;16:1469-78.
10. Vermeer K. Incidence of hand-foot syndrome in colorectal cancer is underestimated. Results of Dutch Colorectal Cancer Group questionnaire exemplified. *Medische Oncologie* 2019;1:56-7. [Article in Dutch].
11. Kwakman JJ, Punt CJ. Oral drugs in the treatment of metastatic colorectal cancer. *Expert Opin Pharmacother* 2016;17:1351-61.
12. Ter Veer E, Haj Mohammad N, van Valkenhoef G, et al. The Efficacy and Safety of First-line Chemotherapy in Advanced Esophagogastric Cancer: A Network Meta-analysis. *J Natl Cancer Inst* 2016;108.
13. Ajani JA, Rodriguez W, Bodoky G, et al. Multicenter phase III comparison of cisplatin/S-1 with cisplatin/infusional fluorouracil in advanced gastric or gastroesophageal adenocarcinoma study: the FLAGS trial. *J Clin Oncol* 2010;28:1547-53.

14. Van Cutsem E, Hoff PM, Harper P, et al. Oral capecitabine vs intravenous 5-fluorouracil and leucovorin: integrated efficacy data and novel analyses from two large, randomised, phase III trials. *Br J Cancer* 2004;90:1190-7.
15. Twelves CJ. Xeloda in Adjuvant Colon Cancer Therapy (X-ACT) trial: overview of efficacy, safety, and cost-effectiveness. *Clin Colorectal Cancer* 2006;6:278-87.
16. Cassidy J, Clarke S, Díaz-Rubio E, et al. XELOX vs FOLFOX-4 as first-line therapy for metastatic colorectal cancer: NO16966 updated results. *Br J Cancer* 2011;105:58-64.
17. Yamada Y, Takahari D, Matsumoto H, et al. Leucovorin, fluorouracil, and oxaliplatin plus bevacizumab versus S-1 and oxaliplatin plus bevacizumab in patients with metastatic colorectal cancer (SOFT): an open-label, non-inferiority, randomised phase 3 trial. *Lancet Oncol* 2013;14:1278-86.
18. Tebbutt NC, Wilson K, GebSKI VJ, et al. Capecitabine, bevacizumab, and mitomycin in first-line treatment of metastatic colorectal cancer: results of the Australasian Gastrointestinal Trials Group Randomized Phase III MAX Study. *J Clin Oncol* 2010;28:3191-8.
19. Masuda N, Lee SJ, Ohtani S, et al. Adjuvant Capecitabine for Breast Cancer after Preoperative Chemotherapy. *N Engl J Med* 2017;376:2147-59.
20. Cassidy J, Twelves C, Van Cutsem E, et al. First-line oral capecitabine therapy in metastatic colorectal cancer: a favorable safety profile compared with intravenous 5-fluorouracil/leucovorin. *Ann Oncol* 2002;13:566-75.
21. Hong YS, Park YS, Lim HY, et al. S-1 plus oxaliplatin versus capecitabine plus oxaliplatin for first-line treatment of patients with metastatic colorectal cancer: a randomised, non-inferiority phase 3 trial. *Lancet Oncol* 2012;13:1125-32.
22. Kang YK, Kang WK, Shin DB, et al. Capecitabine/cisplatin versus 5-fluorouracil/cisplatin as first-line therapy in patients with advanced gastric cancer: a randomised phase III noninferiority trial. *Ann Oncol* 2009;20:666-73.
23. Kwakman JJM, Simkens LHJ, van Rooijen JM, et al. Randomized phase III trial of S-1 versus capecitabine in the first-line treatment of metastatic colorectal cancer: SALTO study by the Dutch Colorectal Cancer Group. *Ann Oncol* 2017;28:1288-93.
24. Ajani JA, Buyse M, Lichinitser M, et al. Combination of cisplatin/S-1 in the treatment of patients with advanced gastric or gastroesophageal adenocarcinoma: Results of noninferiority and safety analyses compared with cisplatin/5-fluorouracil in the First-Line Advanced Gastric Cancer Study. *Eur J Cancer* 2013;49:3616-24.
25. Ter Veer E, Mohammad NH, Lodder P, et al. The efficacy and safety of S-1-based regimens in the first-line treatment of advanced gastric cancer: a systematic review and meta-analysis. *Gastric Cancer* 2016;19:696-712.
26. O'Brien ME, Wigler N, Inbar M, et al. Reduced cardiotoxicity and comparable efficacy in a phase III trial of pegylated liposomal doxorubicin HCl (CAELYX/Doxil) versus conventional doxorubicin for first-line treatment of metastatic breast cancer. *Ann Oncol* 2004;15:440-9.
27. Pujade-Lauraine E, Wagner U, Aavall-Lundqvist E, et al. Pegylated liposomal Doxorubicin and Carboplatin compared with Paclitaxel and Carboplatin for patients with platinum-sensitive ovarian cancer in late relapse. *J Clin Oncol* 2010;28:3323-9.
28. Lorusso D, Naldini A, Testa A, et al. Phase II study of pegylated liposomal doxorubicin in heavily pretreated epithelial ovarian cancer patients. May a new treatment schedule improve toxicity profile? *Oncology* 2004;67:243-9.
29. Rose PG, Maxson JH, Fusco N, et al. Liposomal doxorubicin in ovarian, peritoneal, and tubal carcinoma: a retrospective comparative study of single-agent dosages. *Gynecol Oncol* 2001;82:323-8.
30. Tagawa N, Sugiyama E, Tajima M, et al. Comparison of adverse events following injection of original or generic docetaxel for the treatment of breast cancer. *Cancer Chemother Pharmacol* 2017;80:841-9.
31. Simkens LH, van Tinteren H, May A, et al. Maintenance treatment with capecitabine and bevacizumab in metastatic colorectal cancer (CAIRO3): a phase 3 randomised controlled trial of the Dutch Colorectal Cancer Group. *Lancet* 2015;385:1843-52.
32. Martschick A, Sehouli J, Patzelt A, et al. The pathogenetic mechanism of anthracycline-induced palmar-plantar erythrodysesthesia. *Anticancer Res* 2009;29:2307-13.
33. Yokomichi N, Nagasawa T, Coler-Reilly A, et al. Pathogenesis of hand-foot syndrome induced by PEG-modified liposomal doxorubicin. *Hum Cell* 2013;26:8-18.
34. Lou Y, Wang Q, Zheng J, et al. Possible Pathways of Capecitabine-Induced Hand-Foot Syndrome. *Chem Res Toxicol* 2016;29:1591-1601.
35. Meulendijks D, Henricks LM, Sonke GS, et al. Clinical relevance of DPYD variants c.1679T>G, c.1236G>A/HapB3, and c.1601G>A as predictors of severe fluoropyrimidine-associated toxicity: a systematic review and meta-analysis of individual patient data. *Lancet Oncol* 2015;16:1639-50.
36. Yamada Y, Hamaguchi T, Goto M, et al. Plasma concentrations of 5-fluorouracil and F-beta-alanine following oral administration of S-1, a dihydropyrimidine dehydrogenase inhibitory fluoropyrimidine, as compared with protracted venous infusion of 5-fluorouracil. *Br J Cancer* 2003;89:816-20.
37. Murugan K, Ostwal V, Carvalho MD, et al. Self-identification and management of hand-foot syndrome (HFS): effect of a structured teaching program on patients receiving capecitabine-based chemotherapy for colon cancer. *Support Care Cancer* 2016;24:2575-81.
38. Bun S, Yunokawa M, Tamaki Y, et al. Symptom management: the utility of regional cooling for hand-foot syndrome induced by pegylated liposomal doxorubicin in ovarian cancer. *Support Care Cancer* 2018;26:2161-6.
39. Mangili G, Petrone M, Gentile C, et al. Prevention strategies in palmar-plantar erythrodysesthesia onset: the role of regional cooling. *Gynecol Oncol* 2008;108:332-5.
40. Scotté F, Banu E, Medioni J, et al. Matched case-control phase 2 study to evaluate the use of a frozen sock to prevent docetaxel-induced onycholysis and cutaneous toxicity of the foot. *Cancer* 2008;112:1625-31.
41. Jo SJ, Shin H, Jo S, et al. Prophylactic and therapeutic efficacy of pyridoxine supplements in the management of hand-foot syndrome during chemotherapy: a meta-analysis. *Clin Exp Dermatol* 2015;40:260-70.
42. Chen M, Zhang L, Wang Q, Shen J. Pyridoxine for prevention of hand-foot syndrome caused by chemotherapy: a systematic review. *PLoS One* 2013;8:e72245.
43. Yap YS, Kwok LL, Syn N, et al. Predictors of Hand-Foot Syndrome and Pyridoxine for Prevention of Capecitabine-Induced Hand-Foot Syndrome: A Randomized Clinical Trial. *JAMA Oncol* 2017;3:1538-45.
44. Ren Z, Zhu K, Kang H, et al. Randomized controlled trial of the prophylactic effect of urea-based cream on sorafenib-associated hand-foot skin reactions in patients with advanced hepatocellular carcinoma. *J Clin Oncol* 2015;33:894-900.
45. Wolf SL, Qin R, Menon SP, et al. Placebo-controlled trial to

- determine the effectiveness of a urea/lactic acid-based topical keratolytic agent for prevention of capecitabine-induced hand-foot syndrome: North Central Cancer Treatment Group Study N05C5. *J Clin Oncol* 2010;28:5182-7.
46. Hofheinz RD, Gencer D, Schulz H, et al. Mapisal Versus Urea Cream as Prophylaxis for Capecitabine-Associated Hand-Foot Syndrome: A Randomized Phase III Trial of the AIO Quality of Life Working Group. *J Clin Oncol* 2015;33:2444-9.
 47. Zhang RX, Wu XJ, Wan DS, et al. Celecoxib can prevent capecitabine-related hand-foot syndrome in stage II and III colorectal cancer patients: result of a single-center, prospective randomized phase III trial. *Ann Oncol* 2012;23:1348-53.
 48. Lin E, Morris JS, Ayers GD. Effect of celecoxib on capecitabine induced hand-foot syndrome and antitumor activity. *Oncology* 2002;16:31-7.
 49. Macedo LT, Lima JP, Dos Santos LV, Sasse AD. Prevention strategies for chemotherapy-induced hand-foot syndrome: a systematic review and meta-analysis of prospective randomized trials. *Support Care Cancer* 2014;22:1585-93.
 50. Johnsen SP, Larsson H, Tarone RE, et al. Risk of hospitalization for myocardial infarction among users of rofecoxib, celecoxib, and other NSAIDs: a population-based case-control study. *Arch Intern Med* 2005;165:978-84.
 51. Chen YF, Jobanputra P, Barton P, et al. Cyclooxygenase-2 selective non-steroidal anti-inflammatory drugs (etodolac, meloxicam, celecoxib, rofecoxib, etoricoxib, valdecoxib and lumiracoxib) for osteoarthritis and rheumatoid arthritis: a systematic review and economic evaluation. *Health Technol Assess* 2008;12:1-278.
 52. Kara IO, Sahin B, Erkisi M. Palmar-plantar erythrodysesthesia due to docetaxel-capecitabine therapy is treated with vitamin E without dose reduction. *Breast* 2006;15:414-24.
 53. Drake RD, Lin WM, King M, et al. Oral dexamethasone attenuates Doxil-induced palmar-plantar erythrodysesthesias in patients with recurrent gynecologic malignancies. *Gynecol Oncol* 2004;94:320-4.
 54. Meadows KL, Rushing C, Honeycutt W, et al. Treatment of palmar-plantar erythrodysesthesia (PPE) with topical sildenafil: a pilot study. *Support Care Cancer* 2015;23:1311-9.
 55. Vakalis D, Ioannides D, Lazaridou E, et al. Acral erythema induced by chemotherapy with cisplatin. *Br J Dermatol* 1998;139:750-1.
 56. Pendharkar D, Goyal H. Novel and effective management of capecitabine induced hand foot syndrome. *J Clin Oncol* 2004;22(suppl):751.abstr 8105.
 57. Leicher LW, de Graaf JC, Coers W, et al. Tolerability of Capecitabine Monotherapy in Metastatic Colorectal Cancer: A Real-World Study. *Drugs R D* 2017;17:117-24.
 58. Kwakman JJM, Baars A, Boot H, et al. Tolerability of the oral fluoropyrimidine S-1 after hand-foot syndrome-related discontinuation of capecitabine in Western cancer patients. *Acta Oncologica* 2017;56:1023-6.