

Corrigendum: “High-resolution spectral domain-optical coherence tomography in multiple sclerosis, part II – the total macular volume. The first follow-up study over 2 years”

*Nermin Serbecic*¹, *Fahmy Aboulenein-Djamshidian*^{2*}, *Sven C. Beutelspacher*^{3*}, *Adnan Khan*⁴, *Clemens Vass*¹, *Wolfgang Kristoferitsch*², *Andreas Reitner*¹ and *Ursula Schmidt-Erfurth*¹

¹ Department of Ophthalmology, Medical University of Vienna, Vienna, Austria, ² Department of Neurology, SMZ-Ost Donauespital, Vienna, Austria, ³ Department of Ophthalmology, Faculty of Medicine Mannheim, University of Heidelberg, Mannheim, Germany, ⁴ Nuffield Department of Surgical Sciences, Division of Medical Sciences, University of Oxford, Oxford, UK

Keywords: multiple sclerosis, optical coherence tomography, retinal nerve fiber layer thickness, total macular volume, spectral domain, time domain, heterogeneity, individual differences

OPEN ACCESS

Edited and reviewed by:

Kenneth Shindler,
University of Pennsylvania, USA

*Correspondence:

Fahmy Aboulenein-Djamshidian and
Sven C. Beutelspacher
fahmy.aboul-enein@telering.at;
sven.beutelspacher@gmail.com

Specialty section:

This article was submitted to
Neuro-Ophthalmology, a section of
the journal *Frontiers in Neurology*

Received: 14 May 2015

Accepted: 20 May 2015

Published: 04 June 2015

Citation:

Serbecic N,
Aboulenein-Djamshidian F,
Beutelspacher SC, Khan A, Vass C,
Kristoferitsch W, Reitner A and
Schmidt-Erfurth U (2015)
Corrigendum: “High-resolution
spectral domain-optical coherence
tomography in multiple sclerosis,
part II – the total macular volume.
The first follow-up study over 2 years”.
Front. Neurol. 6:131.
doi: 10.3389/fneur.2015.00131

A corrigendum on

High-resolution spectral domain-optical coherence tomography in multiple sclerosis, part II – the total macular volume. The first follow-up study over 2 years

by Serbecic N, Aboul-Enein F, Beutelspacher SC, Khan A, Vass C, Kristoferitsch W, Reitner A and Schmidt-Erfurth U. *Front Neurol* (2014) 5:20. doi: 10.3389/fneur.2014.00020

A Corrigendum on the Affiliation

The affiliations for Wolfgang Kristoferitsch and Fahmy Aboul-Enein is:

Karl Landsteiner Institute for Neuroimmunological and Neurodegenerative Disorders, SMZ-Ost Donauespital, Langobardenstrasse 122, 1220 Wien, Austria

A Corrigendum on Figure 2

As we confused the terms “RNFL” and “TMV” in the figure legend and submitted the incorrect image for Figure 2, we have to re-submit Figure 2 and correct the figure legend for Figure 2 as follows:

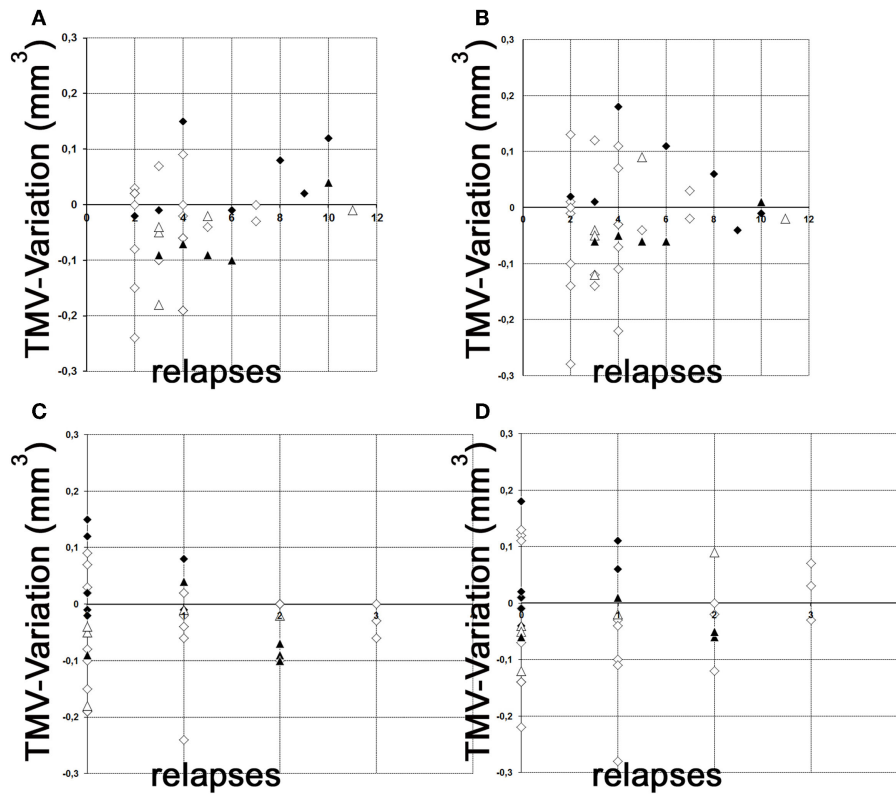


FIGURE 2 | Variation of global TMV measurements. (A,B) variation of TMV measurements between baseline and follow-up examination in relation to the total relapses (without ON) before study entry. **(C,D)** variation of TMV measurements between baseline and follow-up examination in relation to the relapses (without ON) during the

observation period. **(A)** left eye; **(B)** right eye; **(C)** left eye; **(D)** right eye; white squares, RRMS without ON; black squares, RRMS with ON; white triangles, SPMS without ON; black triangles, SPMS with ON. However, neither the raw data nor their interpretations have thus be changed.

Conflict of Interest Statement: The authors declare that the research was conducted in the absence of any commercial or financial relationships that could be construed as a potential conflict of interest.

Copyright © 2015 Serbecic, Aboulenein-Djamshidian, Beutelspacher, Khan, Vass, Kristoferitsch, Reitner and Schmidt-Erfurth. This is an open-access article

distributed under the terms of the Creative Commons Attribution License (CC BY). The use, distribution or reproduction in other forums is permitted, provided the original author(s) or licensor are credited and that the original publication in this journal is cited, in accordance with accepted academic practice. No use, distribution or reproduction is permitted which does not comply with these terms.