



Case Report: Use of Liposomal Amphotericin B in Low Doses in Patients With Visceral Leishmaniasis

Danfeng Ren^{1†}, Wenya Cao^{2†}, Xiaojing Liu¹, Qunying Han¹, Wanhu Fan¹, Guoliang Li³, Han Xia⁴ and Xi Zhang^{1*}

¹ Department of Infectious Diseases, The First Affiliated Hospital of Xi'an Jiaotong University, Xi'an, China, ² Dialysis Department of Nephrology Hospital, The First Affiliated Hospital of Xi'an Jiaotong University, Xi'an, China, ³ Department of Cardiovascular Medicine, The First Affiliated Hospital of Xi'an Jiaotong University, Xi'an, China, ⁴ Hugobiotech Co., Ltd., Beijing, China

OPEN ACCESS

Edited by:

Sergio Oscar Angel,
CONICET Instituto Tecnológico de
Chascomús (INTECH), Argentina

Reviewed by:

Adelina Rosa Riarte,
Dr. Mario Fatała Chabén National
Institute of Parasitology, Argentina
Katharine Carter,
University of Strathclyde,
United Kingdom

*Correspondence:

Xi Zhang
mengfeier82@163.com

[†]These authors have contributed
equally to this work and share first
authorship

Specialty section:

This article was submitted to
Infectious Diseases - Surveillance,
Prevention and Treatment,
a section of the journal
Frontiers in Medicine

Received: 29 August 2021

Accepted: 26 October 2021

Published: 17 November 2021

Citation:

Ren D, Cao W, Liu X, Han Q, Fan W,
Li G, Xia H and Zhang X (2021) Case
Report: Use of Liposomal
Amphotericin B in Low Doses in
Patients With Visceral Leishmaniasis.
Front. Med. 8:766400.
doi: 10.3389/fmed.2021.766400

Background: No consensus has been reached regarding the optimal therapy for visceral leishmaniasis (VL), which affects ~12 million people worldwide.

Case Presentation: This report described four cases of VL encountered in the First Affiliated Hospital of Xi'an Jiaotong University between October 2019 and December 2020. Of the four patients, one patient experienced relapse after antimonial treatment, and the remaining patients had primary VL (including one patient with impaired kidney function and one patient with hemophagocytic syndrome). All patients received a novel treatment protocol, namely the low-dose L-AmB therapy, which was characterized by a low initial dose, cautious dose escalation, and low-dose therapy as maintenance. All patients were cured without severe complications, and there was no further recurrence during follow-up.

Conclusions: This case series demonstrated the safety and efficacy of the low-dose L-AmB therapy for VL patients, providing novel treatment protocol for the VL.

Keywords: visceral leishmaniasis (VL), case series, amphotericin B (AMB), liposomal amphotericin B (L-AmB), the low-dose L-AmB therapy

BACKGROUND

Visceral leishmaniasis (VL) (also known as kala-azar) is a chronic endemic infectious disease caused by the *Leishmania donovani*, which is most transmitted through sandfly bites. Patients with classic VL present with a characteristic pentad of prolonged irregular fever, weight loss, hepatosplenomegaly (especially splenomegaly), pancytopenia, and hyperimmunoglobulinemia (1, 2). VL afflicts 1.5–2 million people each year, and more than 380 million are at risk in 98 subtropical and tropical countries worldwide (3, 4). Over 90% of the patients live in India, Brazil, Sudan, Bangladesh, Nepal, and Ethiopia (4–6). ~ 400 cases of VL are reported in China each year, which mainly occur in six western provinces (Xinjiang, Gansu, Sichuan, Shanxi, Shaanxi and Inner Mongolia). In Shaanxi province, VL is mainly prevalent in Yichuan county and Hancheng City which are located in the junction of the Loess Plateau and the Guanzhong Plain, especially in Hancheng. Recently, the warming climate and the intensified population movement has caused expanding endemic zones and widespread morbidity, which make VL an acute threat to public health and social economy (7–9).

Existing therapeutic options for VL have several limitations. Pentavalent antimonials were the first and the most common drugs used to treat VL (10, 11). Over time, escalating drug resistance exhibited by *Leishmania* parasites had gradually led to the withdrawal of antimony drugs from therapeutic regimens in some regions. Amphotericin B (AMB) and its liposomal formulation (L-AmB) have been gradually employed in many Western countries because of their efficacy (5, 12, 13). However, inevitable severe side effects limit their use (14). Therefore, effective and safe treatments for VL are urgently needed. We proposed a novel approach called the low-dose L-AmB therapy as a method for treating VL. The treatment starts with an average L-AmB dose of 0.1–0.15mg/(kg·day) for a few days. Then, the dose is increased by 0.2 mg/(kg·day) every 1–2 days. Finally, a low dose of L-AmB [0.6–1.2mg/(kg·day)] is applied for maintenance therapy to maximize efficacy and minimize toxicity until the cumulative dose recommended by the World Health Organization (WHO) is achieved (15). A low initial dose and gradual dose escalation help clinicians to adjust the dosage timely according to the patients' condition, which has a great utility for reducing complications. This report describes our experience using the low-dose L-AmB therapy in four patients with VL to provide a basis for selecting safe and effective therapeutic options in VL treatment.

CASE PRESENTATION

Case 1

A 60-year-old previously healthy male farmer presented to the First Affiliated Hospital of Xi'an Jiaotong University with a 6-month history of intermittent fever. Five months ago, he was diagnosed with VL and treated with sodium antimony gluconate (SAG) (0.6 g/d) for 6 days. The patients' condition improved, and he was discharged from the hospital. However, he was readmitted to our hospital because of recrudescence fever. He had a history of working in coalmines and current hypertension treated with oral therapy. There was no complication related to hypertension. Medical, surgical, pharmacological and family histories were not significant. His body weight was 70 kg. Physical examination revealed splenomegaly, no superficial lymphadenopathy, and no edema of the lower limbs. Blood cultures as well as tests for bacteria, fungi, tuberculosis, parasites, and brucellosis agglutination were all negative. His laboratory findings included pancytopenia with a C-reactive protein (CRP) level of 82.8 mg/L and procalcitonin (PCT) level of 0.88 ng/mL. The patient's liver function and coagulation function were abnormal. Computed tomography of the abdomen confirmed the presence of splenomegaly. Examination of bone marrow aspirate revealed amastigotes, which is the typical sign of leishmaniasis. PACE-seq metagenomic next-generation sequencing (mNGS) (Hugobiotech, Beijing, China) detected 5,074 specific reads of

Leishmania in the blood sample, also indicating leishmaniasis (Figure 1). The polymerase chain reaction (PCR) test of the bone marrow aspirate confirmed the diagnosis. He was thus diagnosed with recurrent VL.

Because the patient experienced relapse after treatment with antimonials, he received L-AmB. The starting dose of L-AmB was 10 mg/day (~0.15 mg/kg). Then dose escalation of the L-AmB for the patient is presented in Figure 2. On the 17th day of the treatment protocol when the accumulated dose reached 500 mg (10 mg/kg), PCR of the bone marrow aspirate of *Leishmania* was negative. The patient's blood cell counts (red blood cells, white blood cells, and platelets) increased gradually, and his spleen size decreased gradually. During the treatment, patient's liver function remained normal. There was no recurrence of VL at the 1-year follow-up visit. The patient's temperature and L-AmB dose were presented in Figure 2, and his basic information was summarized in Table 1.

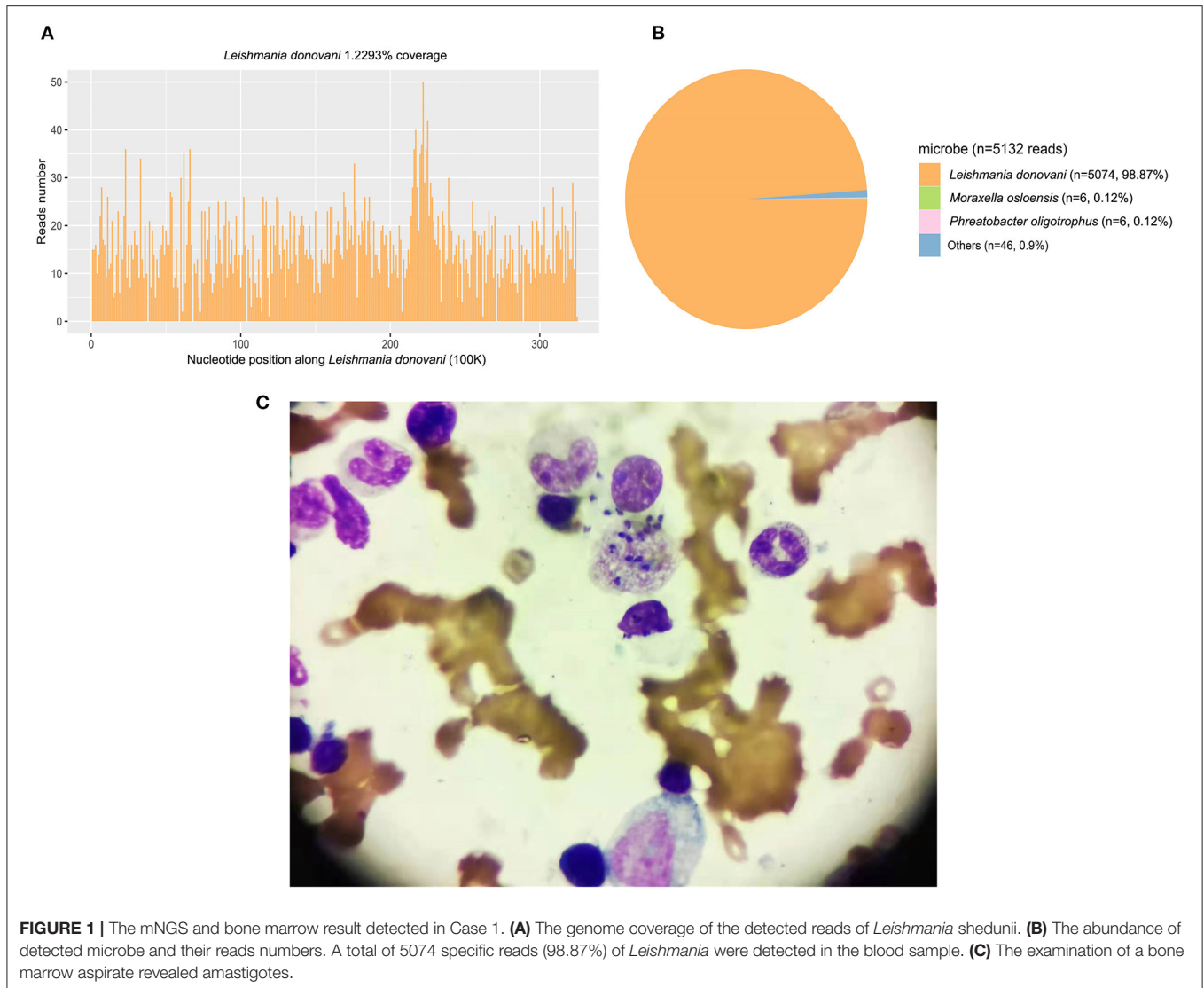
Case 2

A 53-year-old woman with no significant underlying medical history was admitted to our hospital with a 1-month history of intermittent fever. She ever picked *Zanthoxylum* seeds in Hancheng, China 8 years ago, and she had a history of mosquito bites. She had a history of esophageal cancer and received surgical treatment one and a half years ago, and there was no recurrence after operation. Past medical, past surgical, drug and family histories were not significant. Her body weight was 55 kg. Physical examination revealed splenomegaly and axillary and inguinal lymphadenopathy. Laboratory tests revealed high levels of CRP (97.3 mg/L; reference value, <10.0 mg/L), as well as elevated liver enzyme levels, abnormal coagulation, and pancytopenia. Her PCT level was 1.24 ng/mL. Antibodies against *Leishmania* were detected in her blood. A positive PCR result for *Leishmania* in bone marrow aspirate confirmed the diagnosis of VL. She received prompt treatment with L-AmB at an initial dose of 5 mg (~0.10 mg/kg) on the first day. The L-AmB protocol for the patient is presented in Figure 3. During L-AmB dose escalation, laboratory tests of renal functions and electrolytes uncovered no particular abnormality during treatment. Routine blood parameters gradually normalized during therapy, and her spleen size gradually decreased. No VL recurrence was observed at the 1-year follow-up visit.

Case 3

A 56-year-old woman presented with fever. Her symptoms weren't improved after 1 week of anti-infective treatment in a local hospital. Similar to case 2, she also had picked *Zanthoxylum* seeds in Hancheng 1 years ago, and she had a history of mosquito bites. She was healthy in the past. Her body weight was 50 kg. Physical examination revealed splenomegaly, mild lower extremity edema, and multiple skin petechiae. Blood cultures as well as tests for bacteria, fungi, tuberculosis, parasites, and brucellosis agglutination were all negative. The patient's laboratory results revealed pancytopenia and elevated liver enzyme levels (aspartate aminotransferase, 121 U/L; alanine aminotransferase, 36 U/L). Her PCT, CRP, and creatinine levels were 5.67 ng/mL, 89.7 mg/L, and 641

Abbreviations: VL, Visceral leishmaniasis; AMB, Amphotericin B; L-AmB, Liposomal amphotericin B; AKI, Acute kidney impairment; HLH, Hemophagocytic lymphohistiocytosis; WHO, World Health Organization; US-FDA, U.S. Food and Drug Administration; PCR test, the polymerase-chain-reaction test.



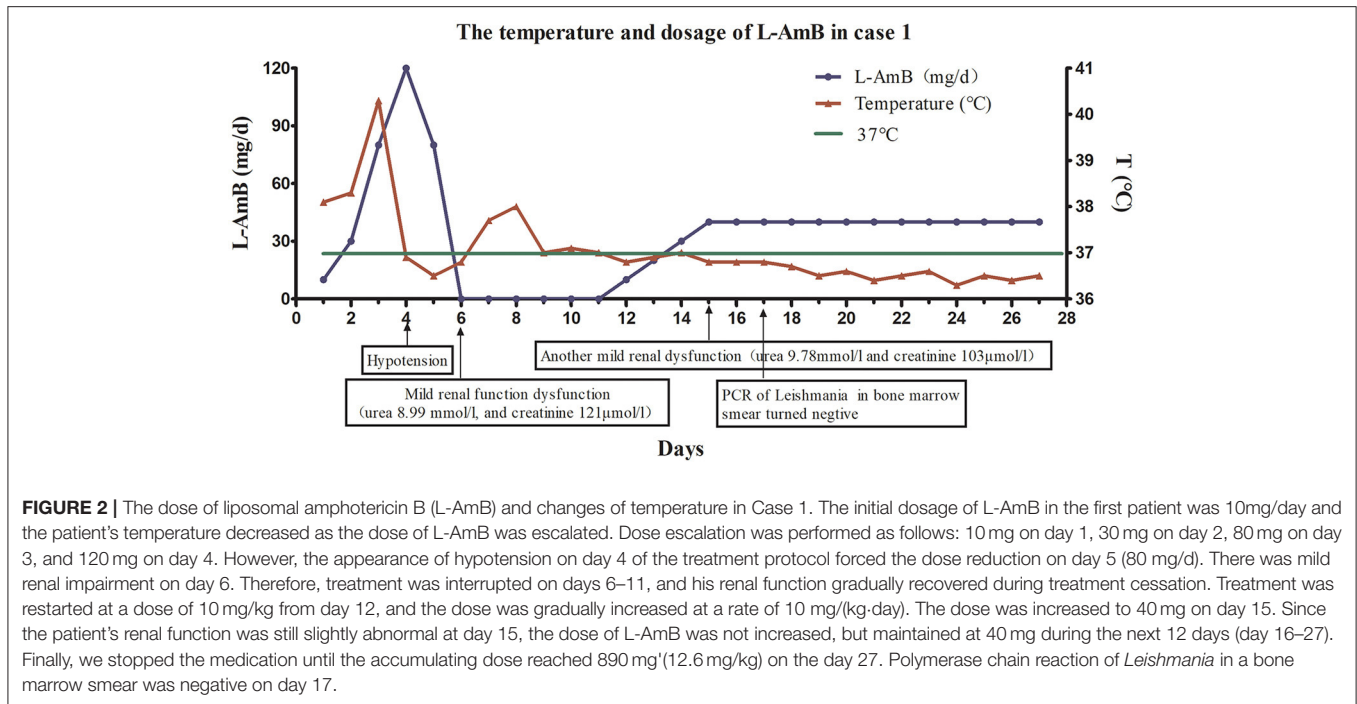
$\mu\text{mol/L}$, respectively. Computed tomography of the abdomen revealed homogeneous splenomegaly. Her bone marrow smear was negative for *Leishmania*. Conversely, antibodies against *Leishmania* were detected in peripheral blood, and PCR was positive for *Leishmania*. The patient was diagnosed with VL combined with acute renal impairment.

Continuous renal replacement therapy (CRRT) was administered on days 2, 4, and 6 after admission, and this treatment resulted in significantly diminished creatinine levels. To avoid the aggravation of pre-existing renal injury, the low-dose therapy of L-AmB was initiated with a starting dose of 5mg (~ 0.10 mg/kg) on days 9–10 after admission. The L-AmB administration protocol is presented in **Figure 3**. During therapy, an increase of plasma creatinine levels was observed, peaking at 178 $\mu\text{mol/L}$ on day 4 of treatment. Her creatinine level subsequently declined to 148 $\mu\text{mol/L}$ on day 8 in the absence of CRRT. Thus, slow dose escalation appeared to prevent the further deterioration of renal function.

The patient's creatinine further declined during maintenance therapy. Routine blood testing revealed gradual increase of red blood cell, white blood cell, and platelet counts. Her spleen size was gradually decreased, and her kidney function was gradually improved by therapy. The patient's liver function also gradually returned to normal during treatment. No relapse was observed during the 3- and 6-month follow-up visit. In addition, we observed complete recovery of her renal function at 6 months after discharge (urea, 5.66 mmol/L; creatinine, 75 $\mu\text{mol/L}$).

Case 4

A 46-year-old man presented with a 3-week history of fever and pancytopenia. He had worked in coalmines in Hebei Province, Henan Province, and Shanxi Province for more than 10 years. There was negative past medical and past surgical history. His body weight was 70 kg. Physical examination suggested sporadic hemorrhagic spots on his skin of chest



and back, palpable right sided cervical lymphadenopathy, and splenomegaly. Blood cultures as well as tests for bacteria, fungi, tuberculosis, parasites, and brucellosis agglutination were all negative. The laboratory examination revealed pancytopenia, coagulation abnormalities, and elevated liver enzyme levels. The patient's PCT and CRP levels were 0.99 ng/mL and 73.4 mg/L, respectively. Bone marrow biopsy disclosed hypocellular marrow with trilineage hematopoiesis and macrophages with microorganisms. The aspirate prominently contained hemophagocytic macrophages. Additional investigations identified elevated ferritin and soluble interleukin-2 receptor (sCD25) levels and absent natural killer (NK)-cell activity, supportive of hemophagocytic lymphohistiocytosis (HLH). Antibodies against *Leishmania* in peripheral blood and PCR were positive, confirming the diagnosis of VL. He was received intravenous gammaglobulin. The L-AmB protocol followed that presented in **Figure 3**. The initial dose was 10 mg (~0.14 mg/kg), and the maintenance dose was 70 mg (~1.0 mg/kg). The total accumulative dosage was 910 mg (13 mg/kg), which was close to the WHO-recommended dosage. The patient's liver enzymes (AST and ALT) were mild abnormal before the treatment. He received the low-dose L-AmB therapy in addition to liver-protecting treatment. His liver function gradually recovered and kidney function remained normal during the treatment. No complications occurred during treatment excluding hypokalaemia, which was corrected via potassium supplementation. The patient's blood routine parameters gradually normalized and spleen size gradually decreased during therapy. No VL recurrence was observed at the 6-month follow-up visit.

DISCUSSION AND CONCLUSIONS

Leishmaniasis, a global disease of poverty, mainly occurs in remote, underdeveloped areas where access to health-care facilities is limited or non-existent (16, 17). Because of its high biological heterogeneity, no treatment option has been found to be universally effective. Pentavalent antimony has been implemented into VL treatment since 1916, and this regimen has remained reliable after more than a century of clinical practice. Antimonial drugs were initially the first-line drugs recommended by WHO, but they have been gradually replaced by L-AmB because of multiple toxicities and inefficacy associated with resistance (5, 15, 17, 18).

The polyene anti-fungal agents AMB and L-AmB exert their fungicidal effects by binding to sterols, i.e., ergosterol of *Leishmania* and cholesterol of host macrophages, leading to the formation of aqueous pores in leishmanial promastigote cell membrane and osmotic changes that result in cell lysis and markedly inhibit the ability of *L. donovani* promastigotes to bind macrophages (19–21). AMB and L-AmB have provided remarkable curative effects and low recurrence rates in the treatment of VL. They are also applicable for patients who experience relapse. AMB was first used to treat VL in other countries in the 1960s, and it was later introduced in China. To date, AMB has been rarely used in China, and its use in the literature was limited to antimony-resistant leishmaniasis (22–24). This might be related to its side effects. By contrast, L-AmB is readily absorbed and highly bioavailable with low rates of adverse events compared with standard

TABLE 1 | Basic patient information and examination results before and after treatment.

	Case 1	Case 2	Case 3	Case 4
Age/ Sex	60/M	53/F	56/F	46/M
Epidemiological history	Travel history to endemic areas	Travel history to endemic areas	Travel history to endemic areas	Travel history to endemic areas
Initial treatment / Relapse	relapse	Initial treatment	Initial treatment	Initial treatment
Complications	-	-	AKI	HLH
Pre-treatment				
Blood routine test				
White blood cell counts [(3.5-9.5) × 10 ⁹ /L]	1.19	1.71	1.06	1.13
Platelet count [(125-350) × 10 ⁹ /L]	42	31	8	32
Red blood cell count [(4.3-5.8) × 10 ¹² /L]	2.5	3.2	2.68	2.5
Hemoglobin concentration [(130-175)g/L]	69	73	55	70
Spleen size				
Line I (cm)	12.5	9	9	9
Line II (cm)	16	9	14	8
Line III (cm)	-3	-4.5	2	-5.5
Bone marrow examination	PCR (+); A bone marrow aspiration revealed Leishmania	PCR (+)	PCR (+)	PCR (+)
Post-treatment/before discharge				
Blood routine test				
White blood cell counts [(3.5-9.5) × 10 ⁹ /L]	2.39	3.02	1.85	3
Platelet count [(125-350) × 10 ⁹ /L]	112	134	27	222
Red blood cell count [(4.3-5.8) × 10 ¹² /L]	3.89	4.58	3.04	3.38
Hemoglobin concentration [(130-175)g/L]	108	121	75	96
Spleen size				
Line I (cm)	8	4	7	4
Line II (cm)	8	1	10	1
Line III (cm)	-8	-7.5	0	-8.5
Bone marrow examination	PCR (-)	PCR (-)	PCR (-)	PCR (-)
Follow-up after discharge	1 year of follow-up	1 year of follow-up	6 months of follow-up	6 months of follow-up
Blood routine test				
White blood cell counts [(3.5-9.5) × 10 ⁹ /L]	5.09	7.05	2.79	8.02
Platelet count [(125-350) × 10 ⁹ /L]	189	251	66	182
Red blood cell count [(4.3-5.8) × 10 ¹² /L]	4.89	4.78	2.91	4.97
Hemoglobin concentration [(130-175)g/L]	140	132	90	155
Spleen size	Untouched below the costal margin	Untouched below the costal margin	3 cm below the costal margin	Untouched below the costal margin
Bone marrow examination	PCR (-)	PCR (-)	PCR (-)	PCR (-)

AKI, acute kidney impairment; HLH, hemophagocytic lymphohistiocytosis; PCR, polymerase chain reaction; PCR (+), PCR for the detection of *Leishmania* was positive; PCR (-), PCR for the detection of *Leishmania* was negative; Spleen line I, the distance between the midline of the left clavicle and the costal margin to the lower margin of the spleen; Spleen line II, the distance between the midline of the left clavicle and the intercostal margin to the farthest point of the spleen; Spleen line III, the distance between the right margin of the spleen and the anterior median line.

The spleen crosses the anterior median line to the right, which was measured as a positive value, and vice versa.

AMB, and it is a front-line agent in various endemic areas (21). However, clinical data for L-AmB remain extremely limited, especially in underdeveloped areas, because of its prohibitive price. In this article, we reported the treatment of four patients with VL who received the low-dose L-AmB therapy. All four patients achieved etiological cure without severe complications.

According to the instructions of L-AmB, treatment is usually started at a dose of 0.1 mg/(kg·day) via slow intravenous infusion with a drip rate not exceeding 30 drops/min. If tolerated, this dose could be increased in 0.25–0.50mg/kg increments per day up to 1–3 mg/(kg·day) for maintenance therapy. Different

treatment regimens have been introduced for patients with VL in different regions. The regimen recommended by WHO is a dose of 3–5mg/(kg·day) for 3–5 days (the cumulative dose can be up to a maximum of 15 mg/kg) or a single dose of 10 mg/kg (15). The regimen recommended by the US FDA is 3 mg/(kg·day) on days 1–5, 14, and 21, with an accumulative dose of 21 mg/kg (25). According to these recommendations, we intended to start with a low dose and maintain it at 3–5mg/(kg·day) to achieve the target cumulative therapeutic dose. However, the first patient experienced transient renal dysfunction and hypotension when the dose was quickly increased to 2 mg/(kg·day) at day 4. The therapy had to be stopped until his

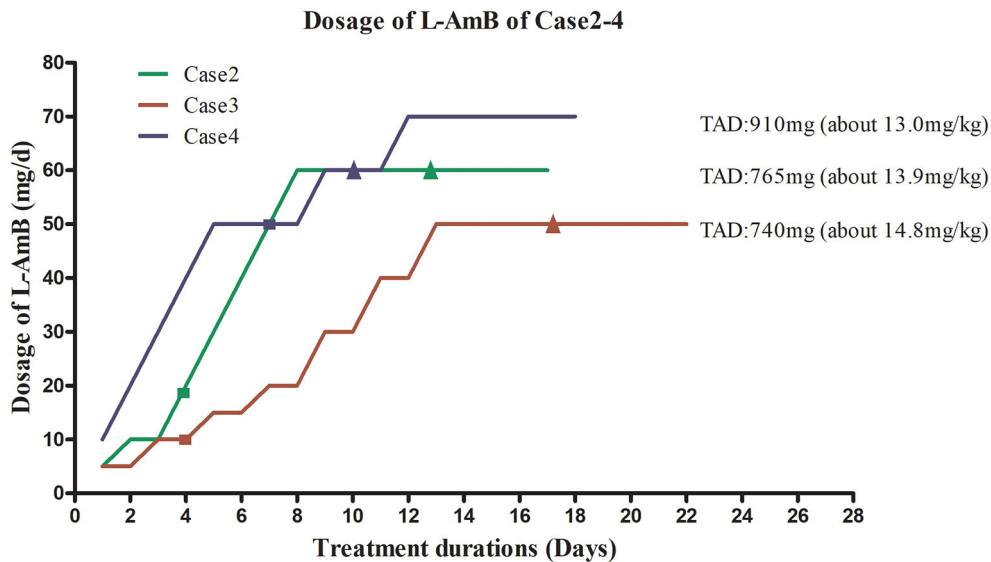


FIGURE 3 | Liposomal amphotericin B (L-AmB) administration protocol and temperature changes in Cases 2–4. TAD, total accumulated dosage. ■ Normalization of body temperature. ▲ Negative PCR result for bone marrow aspirate. To avoid complications associated with adverse drug reactions, the dosing regimens of L-AmB in case 2–4 were similar to those used for case 1, starting with a low dose that was gradually increased until the maximum tolerated dose was reached. This dosage was used for maintenance therapy. The initial dose for case 2 was 5 mg (~0.1 mg/kg) on day 1. The dose was increased to 10 mg on day 2–3, and no complications occurred. Therefore, the patient received L-AmB in 10 mg dose increments up to a dose of 60 mg (~1.2 mg/kg) on day 8. This dosage (60mg) was used for maintenance therapy until the cumulative dose of L-AmB reached 765 mg (13.9 mg/kg) on day 17. Her body temperature returned to normal on day 4. Polymerase chain reaction (PCR) for *Leishmania* in bone marrow aspirate was negative on day 12, when the dose of L-AmB was 405 mg. The trapezoidal regimen of L-AmB in case 3 was initiated at a dose of 5 mg (~0.1 mg/kg). The dosage of L-AmB was increased by 5 mg every 2 days as tolerated from day 1 to day 8 and increased by 10 mg every 2 days from day 9 to day 13 to 50 mg (~1.0 mg/kg), which was administered as maintenance therapy on days 14–22. Treatment was stopped when the cumulative dose of L-AmB reached 740 mg (14.8 mg/kg) on day 22 of protocol. The patient's body temperature had returned to normal on day 4. PCR for *Leishmania* in bone marrow aspirate was negative on day 15, when the cumulative dose of L-AmB was 400 mg. In case 4, L-AmB treatment was initiated at a dose of 10 mg and increased in increments of 10 mg (~0.14 mg/kg) daily, reaching 70 mg (~1.0 mg/kg) on day 7 of the protocol. To avoid complications, instead of further increasing the L-AmB dose, we used a dose of 70 mg as maintenance therapy until the cumulative dose reached 910 mg (13 mg/kg) on day 16. His body temperature returned to normal on day 7. PCR for *Leishmania* in bone marrow aspirate was negative on day 9, when the cumulative dose of L-AmB was 420 mg.

blood pressure stabilized and his kidney function improved. In order to complete the treatment, we subsequently adopted the low-dose therapy as described above, which proved to be equally safe and effective. To avoid the similar situation as patient 1, patient 2, 3, and 4 were also treated with low-dose L-AmB and were cured clinically without serious adverse events. A recent study indicated that empirical L-AmB therapy at a low dose [1 mg/(kg·day)] might be associated with greater medication safety and better economic benefits than high-dose treatments (26). In addition, the low-dose L-AmB therapy has been successfully applied in pulmonary fungal infection (27). Overall, this novel treatment protocol we adopted showed its significant tolerability, efficacy, and safety in the treatment of primary, recurrent, or severe VL.

In summary, the low-dose L-AmB therapy is novel and unique because of its low initial dose, cautious dose-escalation protocol, and low maintenance dose, and it proved effective and minimally toxic in patients with VL. This individualized and flexible treatment reaches the recommended cumulative dose in a safe and controlled manner. The low-dose L-AmB therapy is a novel and promising method for patients with primary, recurrent, or severe VL. However, further large prospective, multicenter, randomized controlled, trials are needed to further evaluate the clinical applicability and safety of this treatment protocol.

DATA AVAILABILITY STATEMENT

The original contributions presented in the study are included in the article/**Supplementary Material**, further inquiries can be directed to the corresponding authors.

ETHICS STATEMENT

Written informed consent was obtained from the individual(s) for the publication of any potentially identifiable images or data included in this article.

AUTHOR CONTRIBUTIONS

XZ, DR, and WC designed research and wrote the article. XL and QH conceived the idea of the case report. HX drew the figure. WF and GL revised the article. All authors reviewed the final version of the manuscript and agreed to its submission.

FUNDING

This work was supported by the National Science and Technology Projects (Project Nos. 2017ZX10203201,

2017ZX10201201, 2017ZX10202202, and 2018ZX10302206) and the National Natural Science Fund (Project No. 81700559).

ACKNOWLEDGMENTS

We thank all health care workers and show the greatest appreciation to all those involved in the treatment of disease. We

thank Joe Barber Jr., PhD, from Liwen Bianji (Edanz), for basic language editing of a draft of this manuscript.

SUPPLEMENTARY MATERIAL

The Supplementary Material for this article can be found online at: <https://www.frontiersin.org/articles/10.3389/fmed.2021.766400/full#supplementary-material>

REFERENCES

- Lun Z, Wu M, Chen Y, Wang J, Zhou X, Liao L, et al. Visceral Leishmaniasis in China: an endemic disease under control. *Clin Microbiol Rev.* (2015) 28:987–1004. doi: 10.1128/CMR.00080-14
- Savoia D. Recent updates and perspectives on leishmaniasis. *J Infect Dev Ctries.* (2015) 9:588–96. doi: 10.3855/jidc.6833
- Gebremichael Tedla D, Bariagabr FH, Abreha HH. Incidence and trends of leishmaniasis and its risk factors in humera, Western Tigray. *J Parasitol Res.* (2018) 2018:1–9. doi: 10.1155/2018/8463097
- Alvar J, Velez ID, Bern C, Herrero M, Desjeux P, Cano J, et al. Leishmaniasis worldwide and global estimates of its incidence. *PLoS ONE.* (2012) 7:e35671. doi: 10.1371/journal.pone.0035671
- Mondal D, Alvar J, Hasnain MG, Hossain MS, Ghosh D, Huda MM, et al. Efficacy and safety of single-dose liposomal amphotericin B for visceral leishmaniasis in a rural public hospital in Bangladesh: a feasibility study. *Lancet Glob Health.* (2014) 2:e51–7. doi: 10.1016/S2214-109X(13)70118-9
- Leta S, Dao TH, Mesele F, Alemayehu G. Visceral leishmaniasis in Ethiopia: an evolving disease. *PLoS Negl Trop Dis.* (2014) 8:e3131. doi: 10.1371/journal.pntd.0003131
- Lin M, Lei C, Lin Q, al E. Prevalence characteristics and space-time clustering of leishmaniasis in Shaanxi province. *Chin J Public Health.* (2018) 34:1021–5. doi: 10.11847/zggws1115469
- Zheng CJ, Xue CZ, Wu WP, XN. Z. Epidemiological characteristics of Kala-azar disease in China, during 2005–2015. *Chin J Epidemiol.* (2017) 38:431–4.
- Osman Y, Simay A, Keyunn K, Ablimit M, Fang J, Hong YY, et al. Investigation on the Outbreak of Visceral Leishmaniasis in 2014 in Jiashi County of Xinjiang. *Chin J Parasitol Parasit Dis.* (2015)33:357–61.
- Martins-Melo FR, Carneiro M, Ramos AN, Heukelbach J, Ribeiro ALP, Werneck GL. The burden of Neglected Tropical Diseases in Brazil, 1990–2016: A subnational analysis from the Global Burden of Disease Study 2016. *PLoS Neg Trop Dis.* (2018) 12:e6559. doi: 10.1371/journal.pntd.006559
- McGwire BS, Satskar AR. Leishmaniasis: clinical syndromes and treatment. *QJM.* (2013) 107:7–14. doi: 10.1093/qjmed/hct116
- Sundar S, Sinha PK, Rai M, Verma DK, Nawin K, Alam S, et al. Comparison of short-course multidrug treatment with standard therapy for visceral leishmaniasis in India: an open-label, non-inferiority, randomised controlled trial. *Lancet.* (2011) 377:477–86. doi: 10.1016/S0140-6736(10)62050-8
- Taslimi Y, Zahedifard F, Rafati S. Leishmaniasis and various immunotherapeutic approaches. *Parasitology.* (2018) 145:497–507. doi: 10.1017/S003118201600216X
- Yuan C, Zhu Y. Liposomal amphotericin B successfully in treatment of Kala-Azar with antimonial resistance in a child: a case report and literature review. *J Clin Pediatr Vol.* (2017) 35:307–10. doi: 10.3969/j.issn.1000-3606.2017.04.017
- Control of the leishmaniasis. *World Health Organ Tech Rep Ser.* (2010)(949):1-186. PubMed PMID: 21485694.
- Okwor I, Uzonna J. Social and economic burden of human leishmaniasis. *Am J Trop Med Hyg.* (2016) 94:489–93. doi: 10.4269/ajtmh.15-0408
- Malalie, Zhai J, Gao X. Advances in the Development of Leishmaniasis Vaccine. *Dermatology Bulletin.* (2020) 37:355–63.
- Matlashewski GP, Arana BM, Kroeger AM, Battacharya SM, Sundar SM, Das PP, et al. Visceral leishmaniasis: elimination with existing interventions. *Lancet Infect Dis.* (2011) 11:322–5. doi: 10.1016/S1473-3099(10)70320-0
- Xiaoyan H, Yali S, Pu B, Yixuan N, Na Z, Changhai S, et al. Systematic classification of antifungal drugs, resistance mechanisms and development of new drugs. *Chin J Mod Appl Pharm.* (2019) 36:1430–6. doi: 10.13748/j.cnki.issn1007-7693.2019.11.025
- Anderson TM, Clay MC, Cioffi AG, Diaz KA, Hisao GS, Tuttle MD, et al. Amphotericin forms an extramembranous and fungicidal sterol sponge. *Nat Chem Biol.* (2014) 10:400–6. doi: 10.1038/nchembio.1496
- Singh N, Kumar M, Singh RK. Leishmaniasis: Current status of available drugs and new potential drug targets. *Asian Pac J Trop Med.* (2012) 5:485–97. doi: 10.1016/S1995-7645(12)60084-4
- Chen S, Yang C, Zhang C, Du G. Treatment of antimony-resistant visceral leishmaniasis with domestic amphotericin B: a case report. *Chinese Journal of Parasitology and Parasitic Diseases.* (2007) 25:156.
- Yuan Q. Treatment of 2 cases of antimony-resistant visceral leishmaniasis with domestic amphotericin B: case report. *Chinese Journal of Parasitology and Parasitic Diseases.* (2010) 28:209–13. doi: 10.4103/0974-777X.62886
- Huo N, Weng H, Li J, Wang Y, Wang G, Zhao H. Successful treatment for a patient with visceral leishmaniasis by amphotericin B. *Chinese Journal of Practical Internal Medicine.* (2017) 37:366–8. doi: 10.19538/j.nk2017040123
- Pearson RD, Jeronimo SM, Lareau SM, US. Food and Drug Administration Approval of Liposomal Amphotericin B for the Treatment of Visceral Leishmaniasis: A Model for Orphan Drug Development. *Curr Infect Dis Rep.* (1999) 1:415–6. doi: 10.1007/s11908-999-0052-0
- Aversa F, Busca A, Candoni A, Cesaro S, Girmenia C, Luppi M, et al. Liposomal amphotericin B (AmBisome(R)) at beginning of its third decade of clinical use. *J Chemother.* (2017) 29:131–43. doi: 10.1080/1120009X.2017.1306183
- Lang X, Xia P, He J, Tang M. Analysis of the administration regimen of amphotericin B liposome in the treatment of pulmonary fungal infection. *Journal Of Imaging Research And Medical Applications.* (2018) 2:210–2.

Conflict of Interest: HX was employed by the company Hugobiotech Co., Ltd.

The remaining authors declare that the research was conducted in the absence of any commercial or financial relationships that could be construed as a potential conflict of interest.

Publisher's Note: All claims expressed in this article are solely those of the authors and do not necessarily represent those of their affiliated organizations, or those of the publisher, the editors and the reviewers. Any product that may be evaluated in this article, or claim that may be made by its manufacturer, is not guaranteed or endorsed by the publisher.

Copyright © 2021 Ren, Cao, Liu, Han, Fan, Li, Xia and Zhang. This is an open-access article distributed under the terms of the Creative Commons Attribution License (CC BY). The use, distribution or reproduction in other forums is permitted, provided the original author(s) and the copyright owner(s) are credited and that the original publication in this journal is cited, in accordance with accepted academic practice. No use, distribution or reproduction is permitted which does not comply with these terms.