



Case Report: Convalescent Plasma Achieves SARS-CoV-2 Viral Clearance in a Patient With Persistently High Viral Replication Over 8 Weeks Due to Severe Combined Immunodeficiency (SCID) and Graft Failure

OPEN ACCESS

Edited by:

Antonio Condino-Neto,
University of São Paulo, Brazil

Reviewed by:

Mike Joyner,
Mayo Clinic, United States
Yun Ling,
Fudan University, China

*Correspondence:

Verena Keitel
verena.keitel@med.uni-duesseldorf.de
Björn Jensen
Bjoern-ErikOle.Jensen@med.uni-duesseldorf.de
Johannes Bode
johannes.bode@med.uni-duesseldorf.de

†These authors have contributed equally to this work

Specialty section:

This article was submitted to Primary Immunodeficiencies, a section of the journal *Frontiers in Immunology*

Received: 03 February 2021

Accepted: 22 March 2021

Published: 03 May 2021

Citation:

Keitel V, Bode JG, Feldt T, Walker A, Müller L, Kunstein A, Klindt C, Killer A, Senff T, Timm J, Ostermann P, Damagnez M, Lübke N, Adams O, Schaal H, Antoch G, Neubert J, Albrecht P, Meuth S, Elben S, Mohring A, Fischer JC, Bölke E, Hoenig M, Schulz AS, Luedde T and Jensen B (2021) Case Report: Convalescent Plasma Achieves SARS-CoV-2 Viral Clearance in a Patient With Persistently High Viral Replication Over 8 Weeks Due to Severe Combined Immunodeficiency (SCID) and Graft Failure. *Front. Immunol.* 12:645989. doi: 10.3389/fimmu.2021.645989

Verena Keitel^{1*†}, Johannes Georg Bode^{1*†}, Torsten Feldt¹, Andreas Walker², Lisa Müller², Anselm Kunstein¹, Caroline Klindt¹, Alexander Killer¹, Tina Senff², Jörg Timm², Philipp Ostermann², Maximilian Damagnez², Nadine Lübke², Ortwin Adams², Heiner Schaal², Gerald Antoch³, Jennifer Neubert⁴, Philipp Albrecht⁵, Sven Meuth⁵, Saskia Elben⁵, Annemarie Mohring⁶, Johannes C. Fischer⁷, Edwin Bölke⁸, Manfred Hoenig⁹, Ansgar S. Schulz⁹, Tom Luedde¹ and Björn Jensen^{1*†}

¹ Department of Gastroenterology, Hepatology and Infectious Diseases, University Hospital Duesseldorf, Medical Faculty, Heinrich-Heine-University Duesseldorf, Duesseldorf, Germany, ² Institute of Virology, University Hospital Duesseldorf, Medical Faculty, Heinrich-Heine-University Duesseldorf, Duesseldorf, Germany, ³ Department of Diagnostic and Interventional Radiology, University Hospital Duesseldorf, Medical Faculty, Heinrich-Heine-University Duesseldorf, Duesseldorf, Germany, ⁴ Department of Pediatric Oncology, Hematology and Clinical Immunology, University Children's Hospital, Medical Faculty, Heinrich-Heine-University Duesseldorf, Duesseldorf, Germany, ⁵ Department of Neurology, University Hospital Duesseldorf, Medical Faculty, Heinrich-Heine-University Duesseldorf, Duesseldorf, Germany, ⁶ Department of Hematology, Oncology and Clinical Immunology, Medical Faculty, Heinrich-Heine-University Duesseldorf, Duesseldorf, Germany, ⁷ Institute for Transplant Diagnostics and Cell Therapeutics, University Hospital Duesseldorf, Medical Faculty, Heinrich-Heine-University, Duesseldorf, Germany, ⁸ Department of Radiation Oncology, University Hospital Duesseldorf, Medical Faculty Heinrich-Heine-University, Duesseldorf, Germany, ⁹ Pediatric Stem Cell Transplantation Unit, University Hospital Ulm, Ulm, Germany

We describe the unique disease course and cure of SARS-CoV-2 infection in a patient with SCID and graft failure. In absence of a humoral immune response, viral clearance was only achieved after transfusion of convalescent plasma. This observation underscores the necessity of the humoral immune response for SARS-CoV-2 clearance.

Keywords: SARS-CoV-2, severe combined immunodeficiency, humoral immune response, convalescent plasma, remdesivir

INTRODUCTION

We describe a 25-year-old female patient with severe combined immunodeficiency (SCID) due to a RAG1 variant (1, 2) with persistently high SARS-CoV-2-RNA concentrations in respiratory samples over 60 days. Immunocompromised patients have not only an increased risk of acquiring severe Corona virus disease 2019 (COVID-19) (3, 4) but may fail to achieve viral clearance with prolonged shedding of viable virus (5, 6).

Our patient was first treated with remdesivir and subsequently received convalescent plasma (CP), which achieved sustained viral clearance.

CASE DESCRIPTION AND DIAGNOSTIC ASSESSMENT

The patient was diagnosed with T⁻/B⁻/NK⁺ SCID and received unconditioned haploidentical hematopoietic stem cell transplantation (HSCT) from her father at 4 months of age (7). Due to incomplete immune reconstitution with poor T cell- and no B cell-engraftment she received a stem cell boost without preconditioning at 4 years of age, repetitive donor lymphocyte infusions (5 times, last infusion 11/2019) and regular immunoglobulin substitution therapy.

She suffered from recurrent bronchopulmonary infections and chronic obstructive pulmonary disease. Due to progressive graft failure she was scheduled for another HSCT.

After a close friend tested positive for SARS-CoV-2, testing was performed while she was asymptomatic and results were positive for SARS-CoV-2 on 30th of April 2020 (day 0). Since patients with SCID are prone to severe systemic viral infections (e.g. cytomegalovirus, adenovirus, parainfluenza virus) (8–10) she was admitted for clinical observation.

Upon admission, her physical examination, vital signs, chest radiography and a CT scan were unremarkable (**Figure 1**). The patient experienced a mild headache for one day but no other COVID-19 associated symptoms. The initial SARS-CoV-2-RNA concentration in the nasopharyngeal swab was 4.89×10^8 copies/ml. SARS-CoV-2 could not be PCR-amplified from the patient's EDTA blood, bone marrow, urine and stool samples. Over the course of 30 days, the patient did not develop any overt symptoms despite persistent high-level viral replication.

On initial admission (day 0) the patient had a reduced neutrophil count (nadir of 115/ μ l on day 4), lymphopenia (389/ μ l) with reduced T-cells 250/ μ l (CD4⁺CD45RA⁺T-cells 6.4/ μ l; CD4⁺CD45RO⁺T-cells 63/ μ l; CD8⁺CD45RA⁺T-cells 29/ μ l; CD8⁺CD45RO⁺T-cells 68/ μ l). NK-cells (CD3⁻CD56⁺) were reduced to 1.3% (4.8/ μ l). Monocytes were 285/ μ l and B-cells were absent, which was in line with undetectable IgA and IgM levels (IgG was substituted). Neutrophils were reduced shortly after infection and recovered preceding development of pneumonia (**Table 1**). The patient received prophylactic antibiotic and antifungal treatment.

On d33 of follow-up the patient presented without overt symptoms, but oxygen saturation was 93% and a CT-scan showed signs of COVID-19 pneumonia (**Figure 1**). SARS-CoV-2-RNA was 1.95×10^7 and 4.07×10^6 copies/ml in nasopharyngeal and bronchial fluid samples, respectively. Thus, COVID-19 pneumonia was diagnosed and the patient received remdesivir (200 mg i.v. on d33, 100 mg/d i.v. d34-42) over 10 days (11). Remdesivir treatment reduced viral concentrations from 1.95×10^7 copies/ml to 5.35×10^4 copies/ml (**Figure 2**). Whole genome sequencing of SARS-CoV-2 showed no remdesivir resistance development. Clinical

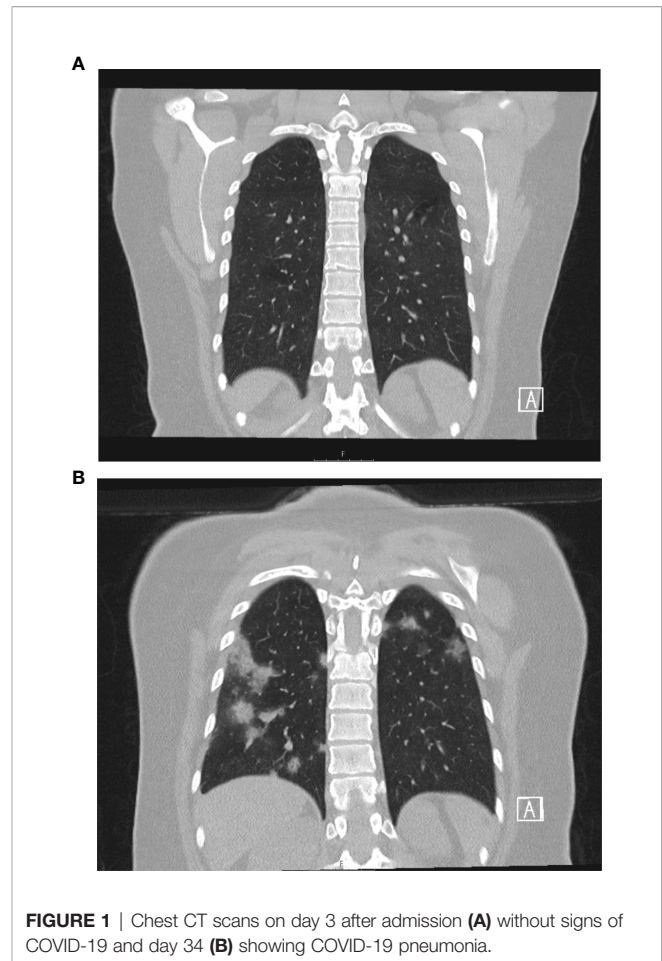


FIGURE 1 | Chest CT scans on day 3 after admission (**A**) without signs of COVID-19 and day 34 (**B**) showing COVID-19 pneumonia.

symptoms of pneumonia improved, however, virus concentrations increased again to levels of 1.48×10^8 copies/ml on d54. To achieve viral clearance, the patient received two units of convalescent plasma (CP, 250 ml each) from donor-1 on day 55 (12). This contained spike-specific IgA- and IgG-antibodies (OD-ratios were 1.94 and 3.26, respectively) and had a neutralizing antibody titer (NT-titer) of 1:80. On d57 a third unit of donor-1 CP was administered. Viral concentration dropped from 3.8×10^7 copies/ml (d55) to 6.75×10^4 copies/ml (d59, 2.75-log reduction). Infusion of three additional units of CP from a different donor (donor-2; d60, d62, d64; IgA/IgG OD-ratio: 8.58/6.44; NT-titer: 1:80) resulted in undetectable viral concentration on NP swabs and increased anti-SARS-CoV-2 antibodies in the patient's serum above the detection limit (IgA/IgG OD-ratio: 2.78/2.96) (**Figure 1**). The patient's symptoms cleared completely and SARS-CoV-2 RNA remained negative even after anti-SARS-CoV-2 antibodies decreased below the detection limit on day 111. The patient received the planned second HSCT on day 138 following conditioning with treosulfan (42g/m^2). Despite this immunosuppressive and -modulatory procedure, the SARS-CoV-2-RNA was not detected by PCR on NP swabs or in the patient's blood (last test from day 158).

TABLE 1 | Laboratory and virological findings; n.d., not detected; NPS, nasopharyngeal swab; CRP, C-reactive protein; PCT, procalcitonin; WBC, white blood cell count (absolute numbers) and differentiation by FACS.

	01/2019	d1	d4	d14	d21	d33	d43	d46	d54/55	d64	d75	d82	d109
Viral load	not appl.	490	116	227	202	19	0.5	0.1	148	n.d.	n.d.	n.d.	n.d.
NPS *10 ⁶													
CRP (mg/dl) <0.5		0.8	0.6	3.4	0.3	4.4	0.3	0.2	0.3	<0.1	<0.1	0.1	0.5
PCT (ng/ml) <0.05		0.07	0.07	0.03	0.03	0.07		0.1	0.08	0.06	0.05	0.04	
IL-6 (pg/ml)		3.9				24.6	9.5		5.3				
Ferritin (µg/ml)		33	77	69	29	90	87	47	32	42	26	24	19
WBC *10 ⁴ /µl	5.5	0.8	0.6	1.0	2.6	3.5	3.1	4.9	3.5	4.9	3.4	4.0	4.5
Neutrophils (n/µl)		190	125	1238	1134	2479	1135	1928	1322	2628	1623	2329	3045
CD20+	n.d.	n.d.	n.d.	n.d.	n.d.	n.d.	n.d.	n.d.	n.d.	n.d.	n.d.	n.d.	n.d.
B-cells (n/µl)													
CD3+ T-cells (n/µl)	574	250	373	428	522	375	435	617	816	676	711	709	1151
CD3+/CD4+ (n/µl)	125		71	72	92	56	88	96	114	97	92	118	152
CD3+/CD8+ (n/µl)	224		108	86	187	157	215	327	426	358	343	339	530
CD3-/CD56+/-	79		4.8	7.3	7.3	5.2	6.1	16.2	19.3	16.7	6.21	12.0	21.5
CD16+ (n/µl)													

Yellow indicates values before SARS-CoV-2 infection. Grey indicates remdesivir application (d33-d43), green indicates application of 6 units of convalescent plasma (CP) from 2 different donors (d55-d64).

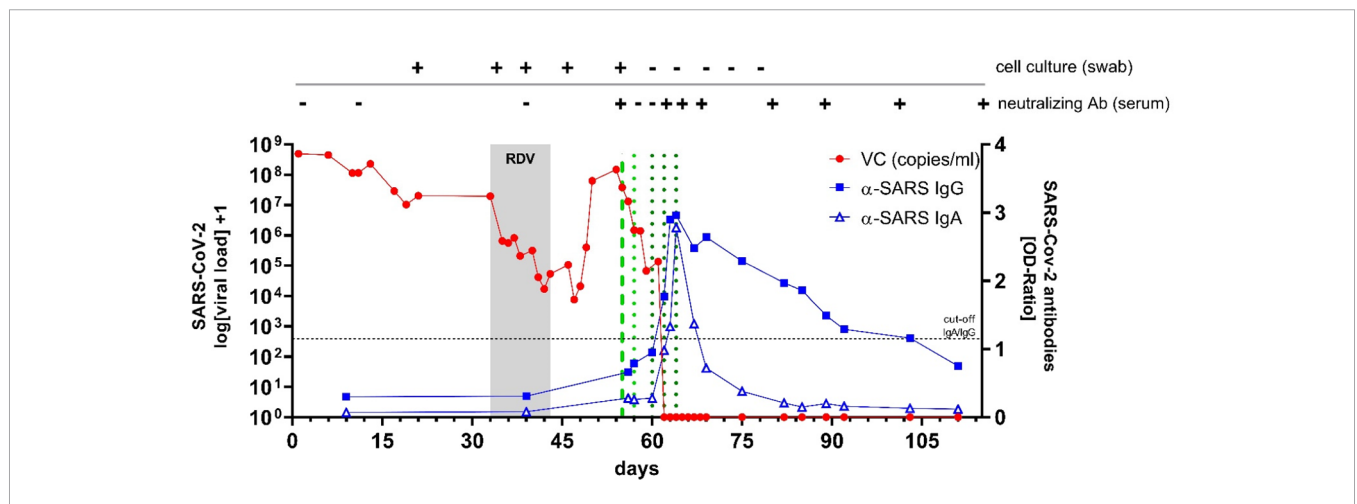


FIGURE 2 | SARS-CoV-2 viral concentration (VC) in nasopharyngeal swabs (in red) and spike specific SARS-CoV-2 antibody titers over time (in blue). Cell culture was used to determine viral replication as well as presence of neutralizing antibodies (Ab). Application of remdesivir (RDV) over 10 days is depicted in grey. Application of convalescent plasma from 2 different donors is depicted as dotted green lines (light green = 3 units from donor-1; dark green = 3 units from donor-2).

DISCUSSION

This unique case illustrates the course of COVID-19 in a situation where the functionality of innate and especially adaptive humoral and cellular immunity is severely limited. Development of COVID-19 pneumonia was significantly delayed despite high viral concentrations and only developed after partial recovery of the cellular immune response. As expected, viral clearance is not achieved with severely impaired T-cell and absent B-cell mediated responses (13, 14). This case and the detection of viral replication in cell culture beyond d50 highlights the need for prolonged quarantine measures and monitoring in patients with immune defects (6).

While remdesivir treatment reduced virus concentrations by 2.6-log, however, after stopping of the drug virus concentrations quickly recovered. CP administration from two different donors achieved sustained viral clearance even after anti-SARS-CoV-2

antibodies dropped below the detection limit, which is in line with reports from patients with primary and secondary immunodeficiency as well as with hematological malignancies (15–17). This therapeutic effect was retained even during a second HSCT on day 138. This case report underscores the importance of the humoral immune response, substituted here by CP transfusions, to successfully clear SARS-CoV-2 infection.

DATA AVAILABILITY STATEMENT

The datasets presented in this study can be found in online repositories. Consensus Sequences are available on GISAID: EPI_ISL_572330, EPI_ISL_572331, EPI_ISL_572333, EPI_ISL_573152, EPI_ISL_574259, EPI_ISL_572397. See also **Supplementary Material**.

ETHICS STATEMENT

The examinations were carried out in accordance with the Declaration of Helsinki and the patient gave written informed consent for use of CP as well as for publication of the pseudonymized results and patient history.

AUTHOR CONTRIBUTIONS

VK, JB, TF, and BJ initiated this work, supervised the study, and drafted the manuscript. VK, JB, TF, BJ, AKu, CK, AKi, TL, AM, AS, MH, PA, GA, JN, SM, and SE took care of the patient, analyzed the clinical data and phenotype, determined diagnostic procedures and treatment plan, and interpreted treatment responses. AW, LM, TS, JT, PO, MD, NL, OA, and HS developed virological test strategies (ELISAs, testing for neutralizing SARS-CoV-2 antibodies, viral sequencing), and performed and interpreted virological data. All authors

critically revised the manuscript. All authors contributed to the article and approved the submitted version.

FUNDING

JT received acknowledges funding through BMBF B-FAST.

ACKNOWLEDGMENTS

Expert technical assistance by Lisa Knopp is thankfully acknowledged.

SUPPLEMENTARY MATERIAL

The Supplementary Material for this article can be found online at: <https://www.frontiersin.org/articles/10.3389/fimmu.2021.645989/full#supplementary-material>

REFERENCES

- Notarangelo LD, Kim MS, Walter JE, Lee YN. Human RAG Mutations: Biochemistry and Clinical Implications. *Nat Rev Immunol* (2016) 16(4):234–46. doi: 10.1038/nri.2016.28
- Fischer A, Notarangelo LD, Neven B, Cavazzana M, Puck JM. Severe Combined Immunodeficiencies and Related Disorders. *Nat Rev Dis Primers* (2015) 1:15061. doi: 10.1038/nrdp.2015.61
- Goodall JW, Reed TAN, Ardissino M, Bassett P, Whittington AM, Cohen DL, et al. Risk Factors for Severe Disease in Patients Admitted With COVID-19 to a Hospital in London, England: A Retrospective Cohort Study. *Epidemiol Infect* (2020) 148:e251. doi: 10.1017/S0950268820002472
- Kim L, Garg S, O'Halloran A, Whitaker M, Pham H, Anderson EJ, et al. Risk Factors for Intensive Care Unit Admission and In-hospital Mortality Among Hospitalized Adults Identified Through the U.S. Coronavirus Disease 2019 (Covid-19)-Associated Hospitalization Surveillance Network (Covid-Net). *Clin Infect Dis* (2020). doi: 10.1093/cid/ciaa1012
- Avanzato VA, Matson MJ, Seifert SN, Pryce R, Williamson BN, Anzick SL, et al. Case Study: Prolonged Infectious SARS-Cov-2 Shedding From an Asymptomatic Immunocompromised Individual With Cancer. *Cell* (2020) 183:1901–12. doi: 10.1016/j.cell.2020.10.049
- Aydillo T, Gonzalez-Reiche AS, Aslam S, van de Guchte A, Khan Z, Obla A, et al. Shedding of Viable Sars-CoV-2 After Immunosuppressive Therapy for Cancer. *N Engl J Med* (2020) 383:2586–8. doi: 10.1056/NEJMc2031670
- Pai SY, Logan BR, Griffith LM, Buckley RH, Parrott RE, Dvorak CC, et al. Transplantation Outcomes for Severe Combined Immunodeficiency, 2000–2009. *N Engl J Med* (2014) 371(5):434–46. doi: 10.1056/NEJMoa1401177
- Ruffner MA, Sullivan KE, Henrickson SE. Recurrent and Sustained Viral Infections in Primary Immunodeficiencies. *Front Immunol* (2017) 8:665. doi: 10.3389/fimmu.2017.00665
- Dropulic LK, Cohen JL. Severe Viral Infections and Primary Immunodeficiencies. *Clin Infect Dis* (2011) 53(9):897–909. doi: 10.1093/cid/cir610
- Al-Herz W, Essa S. Spectrum of Viral Infections Among Primary Immunodeficient Children: Report From a National Registry. *Front Immunol* (2019) 10:1231. doi: 10.3389/fimmu.2019.01231
- Grein J, Ohmagari N, Shin D, Diaz G, Asperges E, Castagna A, et al. Compassionate Use of Remdesivir for Patients With Severe Covid-19. *N Engl J Med* (2020) 382(24):2327–36. doi: 10.1056/NEJMc2015312
- Bloch EM, Shoham S, Casadevall A, Sachais BS, Shaz B, Winters JL, et al. Deployment of Convalescent Plasma for the Prevention and Treatment of COVID-19. *J Clin Invest* (2020) 130(6):2757–65. doi: 10.1172/JCI138745
- Vardhana SA, Wolchok JD. The Many Faces of the anti-COVID Immune Response. *J Exp Med* (2020) 217(6):e20200678. doi: 10.1084/jem.20200678
- Liu STH, Lin HM, Baine I, Wajnberg A, Gumprecht JP, Rahman F, et al. Convalescent Plasma Treatment of Severe COVID-19: A Propensity Score-Matched Control Study. *Nat Med* (2020) 26:1708–13. doi: 10.1038/s41591-020-1088-9
- Senefeld JW, Klassen SA, Ford SK, Wiggins CC, Bostrom BC, Thompson MA, et al. Therapeutic Use of Convalescent Plasma in COVID-19 Patients With Immunodeficiency. *medRxiv* (2020) 2020.11.08.20224790. doi: 10.1101/2020.11.08.20224790
- Thompson MA, Henderson JP, Shah PK, Rubinstein SM, Joyner MJ, Choueiri TK, et al. Convalescent Plasma and Improved Survival in Patients With Hematologic Malignancies and COVID-19. *medRxiv* (2021) 2021.02.05.21250953. doi: 10.1101/2021.02.05.21250953
- Hueso T, Poudroux C, Péré H, Beaumont A-L, Raillon L-A, Ader F, et al. Convalescent Plasma Therapy for B-cell-depleted Patients With Protracted COVID-19. *Blood* (2020) 136(20):2290–5. doi: 10.1182/blood.202008423

Conflict of Interest: The authors declare that the research was conducted in the absence of any commercial or financial relationships that could be construed as a potential conflict of interest.

Copyright © 2021 Keitel, Bode, Feldt, Walker, Müller, Kunstein, Klindt, Killer, Senff, Timm, Ostermann, Damagnez, Lübke, Adams, Schaal, Antoch, Neubert, Albrecht, Meuth, Elben, Mohring, Fischer, Bölke, Hoenig, Schulz, Luedde and Jensen. This is an open-access article distributed under the terms of the Creative Commons Attribution License (CC BY). The use, distribution or reproduction in other forums is permitted, provided the original author(s) and the copyright owner(s) are credited and that the original publication in this journal is cited, in accordance with accepted academic practice. No use, distribution or reproduction is permitted which does not comply with these terms.