



Revisiting hydrocephalus as a model to study brain resilience

Matheus Fernandes de Oliveira*, Fernando Campos Gomes Pinto, Koshiro Nishikuni, Ricardo Vieira Botelho, Alessandra Moura Lima and José Marcus Rotta

Department of Neurosurgery, Hospital do Servidor Público Estadual de São Paulo, São Paulo, Brazil

Edited by:

João Ricardo Mendes Oliveira,
Federal University of Pernambuco,
Brazil

Reviewed by:

João Ricardo Mendes Oliveira,
Federal University of Pernambuco,
Brazil
Carlos Augusto Carvalho De
Vasconcelos, Federal University of
Pernambuco, Brazil

*Correspondence:

Matheus Fernandes de Oliveira,
Hospital do Servidor Público Estadual
de São Paulo, Avenue Pedro de
Toledo, 1800, Vila Clementino, São
Paulo, Brazil.
e-mail: mafernoliv@yahoo.com.br

Hydrocephalus is an entity which embraces a variety of diseases whose final result is the enlarged size of cerebral ventricular system, partially or completely. The physiopathology of hydrocephalus lies in the dynamics of circulation of cerebrospinal fluid (CSF). The consequent CSF stasis in hydrocephalus interferes with cerebral and ventricular system development. Children and adults who sustain congenital or acquired brain injury typically experience a diffuse insult that impacts many areas of the brain. Development and recovery after such injuries reflects both restoration and reorganization of cognitive functions. Classic examples were already reported in literature. This suggests the presence of biological mechanisms associated with resilient adaptation of brain networks. We will settle a link between the notable modifications to neurophysiology secondary to hydrocephalus and the ability of neuronal tissue to reassume and reorganize its functions.

Keywords: hydrocephalus, resilience, brain, neural networks, plasticity

PRESENTATION

Hydrocephalus is an entity which embraces a variety of diseases whose final result is the enlarged size of cerebral ventricular system, partially or completely. Among usual classifications, the most important are those who differ the communicating from non-communicating and congenital from acquired. Its prevalence is near 1–1.5% among general population and is progressively rising with populational growth, thus representing an impressive healthy concern. Congenital hydrocephalus due to a myriad of causes has a rate of 1–2/1000 births, being a common finding among pediatric age (Rekate, 2009).

The physiopathology of hydrocephalus lies in the dynamics of circulation of cerebrospinal fluid (CSF). There should be a disturbance either in production, circulation, or in reabsorption, resulting in positive balances and dilation of ventricular system, producing abnormal high pressure on the ventricles walls. Elevated pressure reflects blocked blood flow out of the lateral ventricle. The consequent CSF stasis in hydrocephalus interferes with cerebral and ventricular system development (Penn and Linninger, 2009).

Responses to elevated CSF pressure can be marked oxidative changes in hydrocephalus that are reflected in the way that injured neurons metabolize neurotransmitters and myelin. Contrary to the previously held belief that gliosis in the hydrocephalic brain is restricted only to the periventricular white-matter, gliosis extends through all of the cortex and the peri-aqueductal area (Penn and Linninger, 2009).

The pathology of cerebral cortex in human hydrocephalus show nerve cells swelling. The neighboring neuropil exhibits notable enlargement of extracellular space, synaptic plasticity and degeneration, damage of myelinated axons, and myelination delay. The astrocytes reveal edematous changes and phagocytic activity.

Glycogen rich- and glycogen-depleted astrocytes are observed. Some oligodendroglial cells exhibit normal morphology, and other exhibit hydropic changes. The capillary wall shows signs of blood–brain barrier dysfunction. The role of ischemia, oxidative stress, increased calcium concentration, activation of NMDA receptors, and disturbance of ion homeostasis are discussed in relationship with the fine structural alterations of hydrocephalic brain parenchyma (Castejón, 2010).

Clinical manifestations depend especially on the time of appearance and form of onset, if acute/subacute or chronic. As a general rule, acute hydrocephalus produce pronounced symptoms as headache, vomitus, papilledema, and impaired consciousness, leading patient to coma and death (Drake, 2008). Chronic hydrocephalus, on other hand, produces skull enlargement, spasticity, progressive neurological deficits in children and dementia, urinary incontinence, and gait changes in elderly (Bergsneider et al., 2008; Ishikawa et al., 2008; Missori et al., 2010).

The treatment, usually represented by some variation of a diversion procedure, consists in deviating CSF flux and acts by reducing intracranial pressure, restoring periventricular, and global perfusion (Bergsneider et al., 2008; Drake, 2008). In children, it is generally performed to restore CSF dynamics and prevent worsening of symptoms. In chronic cases, it controls symptoms of intracranial pressure and interfere in cognitive and motor functions (Ishikawa et al., 2008; McGirt et al., 2008; Ladika and Gurevitz, 2011).

Thus, the form of onset is also the great determinant of cerebral tissue response, leading to physical adaptations, changing elastance and complacency, determining chemical and biological changes, including neuronal plasticity (Penn and Linninger, 2009).

In this context, we will try to settle a link between the notable modifications to neurophysiology secondary to hydrocephalus

and the ability of neuronal tissue to reassume and reorganize its functions toward adaptation.

HYPOTHESIS

Computational models such as the “small-world” and “scale-free” network might explain clinical resilience in various situations (Friston and Price, 2003; Noppeney et al., 2004; Achard and Bullmore, 2007; Van den Heuvel et al., 2008). Small-world networks predicts that neuronal cells are engaged in clustered connectivity with fewer long-range connections (Friston and Price, 2003; Achard et al., 2006). Thus, there would be a shorter path length between any pair of neurons or Brain regions, resulting in higher dynamical complexity, lower wiring costs, and resilience to tissue insults. A scale-free network is characterized by the existence of a small number of nodes having more connections than the other nodes. The nodes that have such a high connectivity degree are referred to as hub-nodes and are suggested to play an important role in the overall network organization (Friston and Price, 2003).

Brain resilience may be also the final result of processes such as redundancy, degeneracy, and pluripotentiality of neural systems (Friston and Price, 2003; Noppeney et al., 2004). Another possible mechanism would be the local neurogenesis already reported in structures such as the basal ganglia, with preferential distribution in sub-regions of the ventral striatum (Stopczynski et al., 2008).

SCIENTIFIC BACKGROUND

Neuronal plasticity is a continuous process where the central nervous system learn skills and remember information, structure neuronal networks in response to environment, and recover from brain and spinal cord injuries, being a fundamental tool in brain resilience to lesions (Johnston, 2009). Basic mechanisms that are involved in plasticity include neurogenesis, programmed cell death, and activity-dependent synaptic plasticity (Wojtowicz, 2011).

Clinical examples of adaptive neuronal plasticity include reorganization of cortical maps of the fingers in response to practice playing a stringed instrument and constraint-induced movement therapy to improve hemiparesis caused by stroke or cerebral palsy (Ewing-Cobbs et al., 2003; Johnston, 2009). Hydrocephalus, congenital or acquired, represents a model of brain resilience too, once transient or permanent perfusional deficits generate structural and/or functional injuries, being partially or completely compensated by remaining cortical areas (Ewing-Cobbs et al., 2003).

Much evidence shows that the brain has an astounding ability to modulate cognitive and motor skills after acute insults, during insidious neurodegenerative processes, psychological stress, or even along the aging course (Price and Friston, 2002; Meunier et al., 2009; Oliveira et al., 2011). Permanent and transient lesions caused by strokes, tumors, head trauma, and hydrocephalus are good models to understand how the compensation process works, following focal or even broader damage (Price and Friston, 2002; Oliveira et al., 2011).

Classic examples were already reported in literature. John Lorber (1915–1996), a British pediatrician recognized by his work with spina bifida and ethic issues in Sheffield University, had the opportunity of attending two young children with hydrocephalus presenting with normal mental development for their age. In both children, there was no evidence of a cerebral cortex, which was

filled by CSF. One of the children died at age 3 months, the second at 12 months. Later, a young man with macrocephaly was referred to Lorber (Lewin, 1980). Although the boy had an IQ of 126 and had a first class honors degree in mathematics, he had “virtually no brain.” Thus, he thought, there should be a tremendous amount of redundancy or spare capacity in the brain. These ideas were shared with scientific community in a pediatric conference in 1980. Later in the same year, his ideas were published by Roger Levin in Science magazine.

Additionally, Norman Geschwind (1926–1984), an American neurologist at Boston’s Beth Israel Hospital known for his works with behavioral neurology, also stated a certainty of capacity for reassigning functions following trauma and injuries in the brain, what should represent a high level of organization of cerebral tissue in order to promote adaptation (Berker et al., 1992).

Other reports even generate a scientific query in the past, where the main question was the seemingly normal brain function with remarkable images of hydrocephalus and congenital malformations (Lewin, 1980). For example, scans of a 44-year-old man’s brain, showed fluid-filled ventricles, leaving little more than a thin sheet of actual brain tissue. He was married and father of two children, and worked as a civil servant. The man went to a hospital after he had mild weakness in his left leg. He used to have a shunt inserted into his head to drain away hydrocephalus as an infant and was removed when he was 14. Intelligence tests showed the man had an IQ of 75, below the average score of 100 but not considered mentally retarded or disabled, either (Feuillet et al., 2007). In **Figure 1**, we try to illustrate this scene by presenting the brain parenchyma of a normal subject followed by the brain of a normal subject with impressive hydrocephalus (Oliveira et al., unpublished data) and then an equally impressive hydrocephalus of a patient with profound symptoms (Oliveira et al., unpublished data).

The surprising question is that patients with very similar neuroradiological aspects may present with different and complex neurological impairments, from motor to cognitive.

DISCUSSION

Some important discussions about symptoms in hydrocephalic and non-hydrocephalic patients were already reported. Previous studies of 10 sets of twins discordant for hydrocephalus in early life displayed differences in quality and quantity of development of verbal versus non-verbal cognitive functions, birth order, and hand and eye preference (Berker et al., 1992). The differences between those discordant twins seems to indicate systematic changes in pre-, peri-, and/or early postnatal organization and development of hemispheric function (Berker et al., 1992).

Other study considering the development of five language domains (word finding, fluency and automaticity, immediate sentence memory, understanding of grammar, and metalinguistic awareness) was held in children and adolescents, 75 with hydrocephalus in the first year of life, and 50 normal controls (Dennis et al., 1987). The results revealed a limited resilience of language to the effects of early hydrocephalus (Dennis et al., 1987).

OUTCOME

In adult hydrocephalus, especially idiopathic normal pressure hydrocephalus (INPH), it is observed recover after shunting

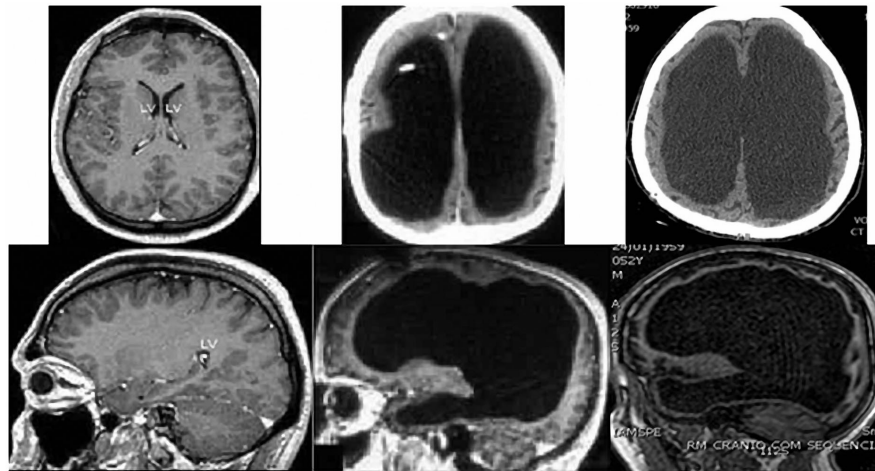


FIGURE 1 | The contrast among a normal brain in a normal adult (left), the brain of a normal man with impressive hydrocephalus (Oliveira et al., unpublished data; middle), and an equally impressive hydrocephalus in a 54-year-old man with deep cognitive and motor impairment since childhood (right; Oliveira et al., unpublished data).

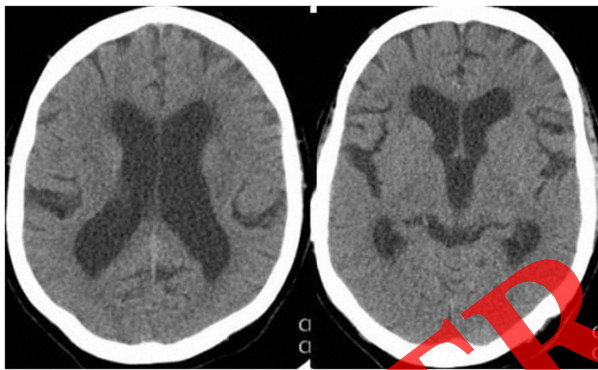


FIGURE 2 | Neuroimaging in normal pressure hydrocephalus.

procedures, which represents proof of brain resilience (Bergsneider et al., 2008; Ishikawa et al., 2008; Ladika and Gurevitz, 2011). A study displayed significant improvements at follow-up demonstrated on tests of verbal memory as well as in one test of psychomotor speed. Eight of 10 patients showed improvement by more than 1 SD on at least one memory test. Six of 10 patients improved significantly on more than 50% of the tests administered (McGirt et al., 2008; Simon et al., 2009). Our own experience with INPH shunting is also in accordance with literature results. Patients elected for surgery and with good response after execution of tap test in the pre operative period, usually present a remarkable recovery in cognitive and especially motor functions gradually (Oliveira et al., unpublished data). In a report, there was a significant reversal in neuropsychological test scores with increased brain volume and increased regional cerebral glucose utilization in several brain regions after shunting of INPH (Simon et al., 2009; Figure 2).

Rat models of chronic hydrocephalus suggested that disturbance in the postsynaptic integration processes, rather than

axonal conduction or synaptic transmission, are more important for the production of the neurological deficits seen in chronic hydrocephalus (Kaye et al., 1990; Miller and McAllister, 2007; Kondziella et al., 2008). In the same models, it was found impaired hippocampal plasticity (Ishibokawa et al., 1988).

Recent evidences also hypothesize the role played by dopamine D2 receptors in normal pressure hydrocephalus. In NPH, D2 receptor down regulation was attenuated at 1 month after shunt surgery (Nakayama et al., 2007). A PET study showed significant increases of glucose metabolism in the cerebral cortical areas after surgery and a micro dialysis study showed a postoperative reduction in the glutamate content of the cerebral cortex, pointing that shunting and consecutively better regional perfusion reestablish the citoarchitecture and synthesis of dopamine D2 receptors, attenuating motor dysfunctions (Nakayama et al., 2007).

CONCLUSION

Therefore, several examples can be elicited to assign neural plasticity and resilience applied to hydrocephalic models, reassuming concepts of basic neurophysiology and discussing neural networks and integration, regeneration of neuronal tissue, and resilience to injuries. Degeneracy and resilience are probably continuous and simultaneous events taking part in this complex process.

We should not forget that, as long as there are large hydrocephalic, tumoral, traumatic, and ischemic samples of brain resilience and recovery, there are also cases of specific and punctiform lesions, sometimes only seem in high definition image studies, causing aggressive impairment of neurological function, even compatible with death.

Clinical experience and experimental models have already shown the resistance of the brain tissue to injuries, acute or chronic. Until now, what we have summarized are pieces of individual reports and atypical manifestations of neurological diseases. Doubtlessly, further multicenter investigations will be needed to clarify the infinite questions asked about neuronal tissue physiology.

REFERENCES

- Achard, S., and Bullmore, E. (2007). Efficiency and cost of economical brain functional networks. *PLoS Comput. Biol.* 3, e17. doi:10.1371/journal.pcbi.0030017
- Achard, S., Salvador, R., Whitcher, B., Suckling, J., and Bullmore, E. (2006). A resilient, low-frequency, small-world human brain functional network with highly connected association cortical hubs. *J. Neurosci.* 26, 63–72.
- Bergsneider, M., Miller, C., Vespa, P. M., and Hu, X. (2008). Surgical management of adult hydrocephalus. *Neurosurgery* 62(Suppl. 2), 643–659; discussion 659–660.
- Berker, E., Goldstein, G., Lorber, J., Priestley, B., and Smith, A. (1992). Reciprocal neurological developments of twins discordant for hydrocephalus. *Dev. Med. Child Neurol.* 34, 623–632.
- Castejón, O. J. (2010). Submicroscopic pathology of human and experimental hydrocephalic cerebral cortex. *Folia Neuropathol.* 48, 159–174.
- Dennis, M., Hendrick, E. B., Hoffman, H. J., and Humphreys, R. P. (1987). Language of hydrocephalic children and adolescents. *J. Clin. Exp. Neuropsychol.* 9, 593–621.
- Drake, J. M. (2008). The surgical management of pediatric hydrocephalus. *Neurosurgery* 62(Suppl. 2), 633–640; discussion 640–642.
- Ewing-Cobbs, L., Barnes, M. A., and Fletcher, J. M. (2003). Early brain injury in children: development and reorganization of cognitive function. *Dev. Neuropsychol.* 24, 669–704.
- Feuillet, L., Dufour, H., and Pelletier, J. (2007). Brain of a white-collar worker. *Lancet* 370, 262.
- Friston, K. J., and Price, C. J. (2003). Degeneracy and redundancy in cognitive anatomy. *Trends Cogn. Sci. (Regul. Ed.)* 7, 151–152.
- Ishikawa, M., Hashimoto, M., Kuwana, N., Mori, E., Miyake, H., Wachi, A., Takeuchi, T., Kazui, H., and Koyama, H. (2008). Guidelines for management of idiopathic normal pressure hydrocephalus. *Neurol. Med. Chir. (Tokyo)* 48(Suppl.), S1–S23.
- Johnston, M. V. (2009). Plasticity in the developing brain: implications for rehabilitation. *Dev. Disabil. Res. Rev.* 15, 94–101.
- Kaye, J. A., Grady, C. L., Haxby, J. V., Moore, A., and Friedland, R. P. (1990). Plasticity in the aging brain. Reversibility of anatomic, metabolic, and cognitive deficits in normal-pressure hydrocephalus following shunt surgery. *Arch. Neurol.* 47, 1336–1341.
- Kondziella, D., Sonnewald, U., Tullberg, M., and Wikkelso, C. (2008). Brain metabolism in adult chronic hydrocephalus. *J. Neurochem.* 106, 1515–1524.
- Ladika, D. J., and Gurevitz, S. L. (2011). Identifying the most common causes of reversible dementias: a review. *JAAPA* 24, 28–31, 57.
- Lewin, R. (1980). Is your brain really necessary? *Science* 210, 1232–1234.
- McGirt, M. J., Woodworth, G., Coon, A. L., Thomas, G., Williams, M. A., and Rigamonti, D. (2008). Diagnosis, treatment, and analysis of long-term outcomes in idiopathic normal-pressure hydrocephalus. *Neurosurgery* 62(Suppl. 2), 670–677.
- Meunier, D., Achard, S., Morcom, A., and Bullmore, E. (2009). Age-related changes in modular organization of human brain functional networks. *Neuroimage* 44, 715–723. [Epub Nov 5, 2008].
- Miller, J. M., and McAllister, J. P. II. (2007). Reduction of astrogliosis and microgliosis by cerebrospinal fluid shunting in experimental hydrocephalus. *Cerebrospinal Fluid Res.* 4, 5.
- Missori, P., Paolini, S., and Currà, A. (2010). From congenital to idiopathic adult hydrocephalus: a historical research. *Brain* 133(Pt 6), 1836–1849.
- Nakayama, T., Ouchi, Y., Yoshikawa, E., Sugihara, G., Torizuka, T., Tanaka, K. (2007). Striatal D2 receptor availability after shunting in idiopathic normal pressure hydrocephalus. *J. Nucl. Med.* 48, 1981–1986.
- Noppeney, U., Friston, K. J., and Price, C. J. (2004). Degenerate neuronal systems sustaining cognitive functions. *J. Anat.* 205, 433–442.
- Oliveira, J. R. M., Oliveira, M. F., Kuhn, R., Lemos, R. R., and Oliveira, D. F. (2011). “Neuro imaging genetics studies in basal ganglia calcification as a model to understand brain resilience,” in *The Israel Society for Neuroscience 19th Annual Meeting*, Eilat.
- Penn, R. D., and Linninger, A. (2009). The physics of hydrocephalus. *Pediatr. Neurosurg.* 45, 161–174.
- Price, C. J., and Friston, K. J. (2002). Degeneracy and cognitive anatomy. *Trends Cogn. Sci. (Regul. Ed.)* 6, 416–421.
- Rekate, H. L. (2009). A contemporary definition and classification of hydrocephalus. *Semin. Pediatr. Neurol.* 16, 9–15.
- Simon, T. D., Lamb, S., Murphy, N. A., Hom, B., Walker, M. L., and Clark, E. B. (2009). Who will care for me next? Transitioning to adulthood with hydrocephalus. *Pediatrics* 124, 1431–1437.
- Stopczynski, R. E., Poloskey, S. L., and Haber, S. N. (2008). Cell proliferation in the striatum during postnatal development: preferential distribution in subregions of the ventral striatum. *Brain Struct. Funct.* 213, 119–127.
- Tsubokawa, T., Katayama, Y., and Kawamura, T. (1988). Impaired hippocampal plasticity in experimental chronic hydrocephalus. *Brain Inj.* 2, 19–30.
- Van den Heuvel, M. P., Stam, C. J., Boersma, M., and Hulshoff Pol, H. E. (2008). Small-world and scale-free organization of voxel-based resting-state functional connectivity in the human brain. *Neuroimage* 43, 528–539.
- Wojtowicz, J. M. (2011). Adult neurogenesis. From circuits to models. *Behav. Brain Res.* doi: 10.1016/j.bbr.2011.08.013. [Epub ahead of print].

Conflict of Interest Statement: The authors declare that the research was conducted in the absence of any commercial or financial relationships that could be construed as a potential conflict of interest.

Received: 18 October 2011; paper pending published: 25 November 2011; accepted: 18 December 2011; published online: 06 January 2012.

Citation: de Oliveira MF, Pinto FCG, Nishikuni K, Botelho RV, Lima AM and Rotta JM (2012) Revisiting hydrocephalus as a model to study brain resilience. *Front. Hum. Neurosci.* 5:181. doi: 10.3389/fnhum.2011.00181
Copyright © 2012 de Oliveira, Pinto, Nishikuni, Botelho, Lima and Rotta. This is an open-access article distributed under the terms of the Creative Commons Attribution Non Commercial License, which permits non-commercial use, distribution, and reproduction in other forums, provided the original authors and source are credited.