



OPEN ACCESS

EDITED BY

Francesc Bosch,
Vall d'Hebron University Hospital,
Spain

REVIEWED BY

John P. Campbell,
University of Bath, United Kingdom
Francesca Fazio,
Department of Translational and
Precision Medicine Hematology
Sapienza University of Rome, Italy

*CORRESPONDENCE

Roberto Lovero
robertolovero69@gmail.com

SPECIALTY SECTION

This article was submitted to
Blood Cancer,
a section of the journal
Frontiers in Hematology

RECEIVED 21 June 2022

ACCEPTED 29 July 2022

PUBLISHED 16 September 2022

CITATION

Troiano T, Brescia V, De Marinis L,
Marinaccio A, Lovero R, Rizzi R and Di
Serio F (2022) Case Report: A case of
IgD lambda/lambda Multiple
Myeloma in patient with acute
renal failure and without monoclonal
spike in serum electrophoresis.
Front. Hematol. 1:974392.
doi: 10.3389/frhem.2022.974392

COPYRIGHT

© 2022 Troiano, Brescia, De Marinis,
Marinaccio, Lovero, Rizzi and Di Serio.
This is an open-access article
distributed under the terms of the
[Creative Commons Attribution License
\(CC BY\)](#). The use, distribution or
reproduction in other forums is
permitted, provided the original
author(s) and the copyright owner(s)
are credited and that the original
publication in this journal is cited, in
accordance with accepted academic
practice. No use, distribution or
reproduction is permitted which does
not comply with these terms.

Case Report: A case of IgD lambda/lambda Multiple Myeloma in patient with acute renal failure and without monoclonal spike in serum electrophoresis

Teresa Troiano¹, Vincenzo Brescia¹, Lucia De Marinis¹,
Anna Marinaccio¹, Roberto Lovero^{1*}, Rita Rizzi²
and Francesca Di Serio¹

¹Clinical Pathology Unit, Polyclinic of Bari, Bari, Italy, ²Hematology and Bone Marrow Transplantation Unit, Azienda Ospedaliera Unicersitaria Consorziata (AOUC) Policlinico, Bari, Italy

Background: IgD Multiple Myeloma is a rare form of plasma cell dyscrasia and accounts for approximately 1-2% of all cases of Multiple Myeloma. It mainly affects young, male subjects; it is characterized by an aggressive course, a high production of Bence Jones protein, acute renal failure and an often unfortunate outcome compared to the other isotypes of MM. A distinctive feature is the lack of a monoclonal peak on serum protein electrophoresis (SPE).

Case report: a 57-year-old man with pain in his left lower limb and weight loss goes to the Emergency Department (Emergency Department). Laboratory tests performed showed normocytic normochromic anemia (Hemoglobin 9.4 g/dL), acute renal failure (s-creatinine 2.85 mg/dL, e-GFR 23 mL/min/1.73 m². serum protein electrophoresis (SPE) detected only mild polyclonal in the gamma zone with no evidence of any monoclonal peak.

Results: serum immunofixation (s-IFE) showed a monoclonal IgD λ band and a monoclonal λ band. The Free Light Chains (s-FLC) measurement showed a ratio of 0.04. The bone marrow biopsy confirmed an infiltration of > 20% of clonal plasma cells; renal biopsy diagnosed "cast nephropathy".

Conclusion: IgD λ/λ Multiple Myeloma is a rare form of this disease with a poor prognosis; an early and correct laboratory diagnosis is crucial for appropriate treatment and effective monitoring in order to improve patient outcome.

KEYWORDS

Multiple Myeloma, IgD lambda/lambda, monoclonal spike, serum electrophoresis, acute renal failure

Introduction

Multiple Myeloma, represents about 10% of hematological neoplasms, is characterized by the clonal proliferation of plasma cells that produces a monoclonal protein almost always visible on the electrophoretic trace (SPE). IgD MM is a rare form of this disease (1-2%) and is characterized by, compared to the other isotypes, greater frequency in male subjects (M/F: 1.6/1); absence of monoclonal protein on serum protein electrophoresis, low survival, higher frequency of the elevated isotype IgD λ compared to IgD k, hypercalcemia, incidence of extramedullary infiltration, bone lesions and often associated with amyloidosis to read (AL) (1–3).

At the time of diagnosis, 20-40% of patients present with acute renal failure with “cast nephropathy” caused by the intratubular precipitation of the free light chains of immunoglobulin (4, 5).

We report a challenging case in the laboratory diagnosis of a bclonal IgD λ/λ Multiple Myeloma in a patient with impaired renal function, anemia, without hypercalcemia and with an electrophoretic trace of monoclonal peak serum proteins.

Case report

A 57-year-old male patient with a history of hypertension and type 2 diabetes mellitus being treated with oral antidiabetics, he arrived he was admitted to at the Emergency Department (Emergency Department) of the University Hospital Polyclinic of Bari for pain in the left lower limb, asthenia and weight loss. On physical examination he presented obesity (body weight 112kg; height 173cm; BMI of 37.12), referred with an inexplicable weight loss of about 10 kg in two months. The first level laboratory investigations are performed showed in **Table 1** a normocytic normochromic anemia (Hemoglobin 9.4 g/dL) (13.3-17.2 g/dL); acute renal failure (AKI) ((s-creatinine 2.85 mg/dL) (0.67-1.17 mg/dL) and eGFR 23 mL/min/1.73m²), blood glucose 212 mg/dL (<100 mg/dL), total protein 8.5 g/dL (6.4 - 8.2 g/dL), albumin 3.6 g/dL (3.4-5.0 g/dL), calcium 8.8 mg/dL (8.5-10.1 g/dL), U-PCR (U-Protein/U-Creatinine Ratio) 1258 mg/g (<200mg/g) and U-ACR (U-Albumin/U- Creatinine Ratio) 146 mg/g (<30 mg/g). For a better understanding of the renal damage, further laboratory investigations were performed and renal biopsy planned in a diabetic and hypertensive patient.

Serum protein electrophoresis (CZE capillary method SEBIA-France instrumentation) showed a mild hypergammaglobulinemia without any monoclonal peak; the s-Free Light Chains λ (sFLCL) and the s-Free Light Chains k (sFLCK) (Freelite immunoturbidimetric method Optilite instrumentation The Binding Site, Birmingham, UK) were respectively 2348 mg/L (5.71-26.30 mg/L) and 92.3 mg/L (3.3-19.40 mg/L) with a k/ λ ratio of 0.04. Total Protein 24h Urine (UTP) was 1680 mg/24h (0–149) and Albumin 24h Urine was 232mg/24h (<30). Total IgG, IgM, IgA and IgE were performed with

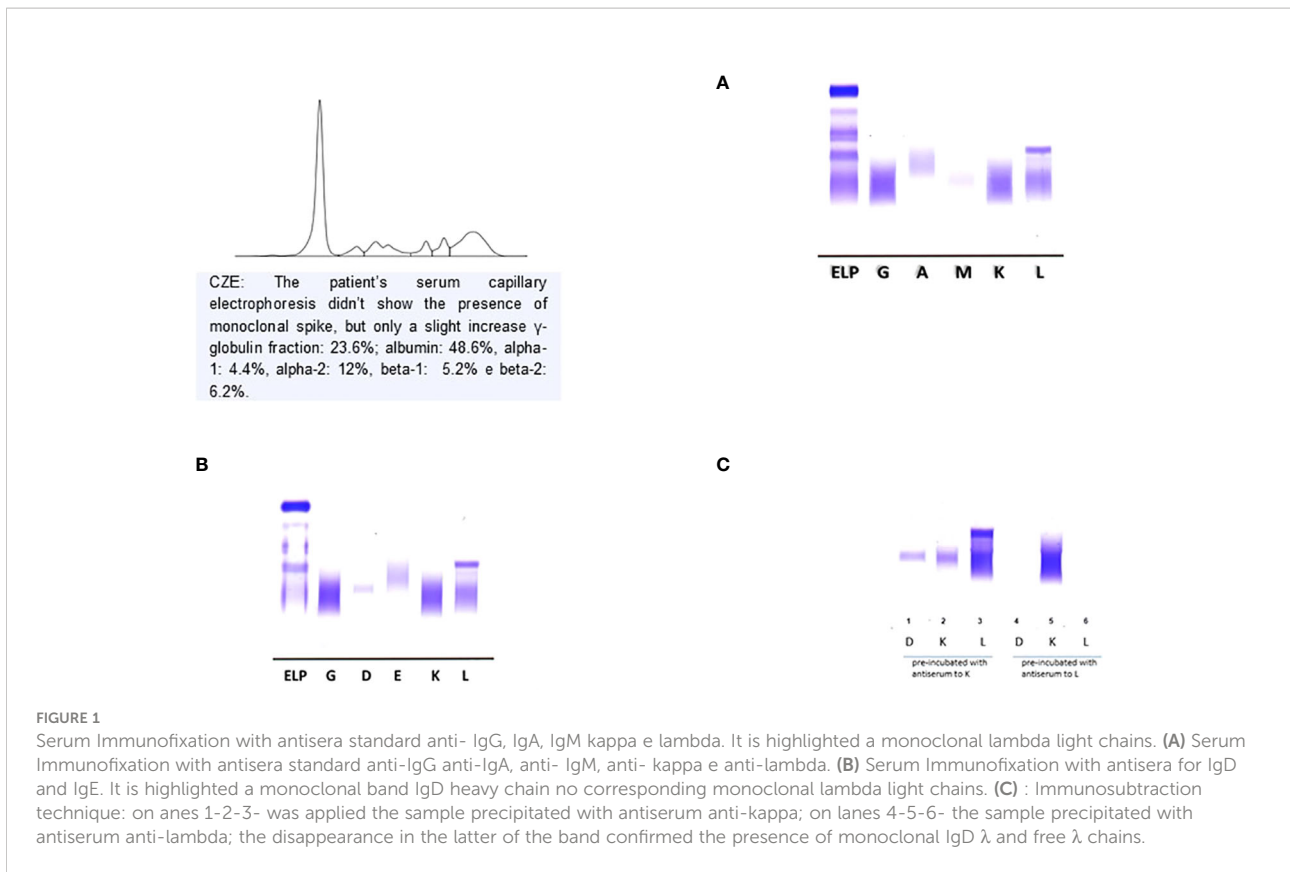
immunonephelometric method on Dimension Vista 1500 analyzer (Siemens Healthineers). The total IgD was determined with the immunonephelometric method on the BN ProSpec System analyzer (Siemens Healthineers) (**Table 1**).

The laboratory diagnostic work-up was completed with serum (s-IFE) and urinary (u-IFE) immunofixation performed on agarose gel (Hydrasis Sebia France) for the search for monoclonal immunoglobulins and the Bence Jones protein. The laboratory diagnostic work-up was completed with serum (s-IFE) and urinary (u-IFE) immunofixation performed on agarose gel (Hydrasis Sebia France) to detect the monoclonal immunoglobulins and the Bence Jones protein. The first s-IFE was performed using standard anti-IgG, IgA, IgM, Kappa and lambda antisera which showed the presence of a monoclonal band of lambda type (λ) not binding any heavy chain (**Figure 1A**). The second s-IFE was performed using anti IgD and IgE kappa and lambda (Sebia Instrumentation, Francia) antisera which showed the presence of a monoclonal, homogeneous and compact band, type IgD band and a monoclonal lambda band (λ) (**Figure 1B, 2**). The visualization of the agarose gel showed that the monoclonal band of the IgD heavy chain had different electrophoretic motility of the lambda light chain and were not aligned with each other. The correct characterization of the two monoclonal immunoglobulins required an additional s-IFE using an immunosubtraction technique. Patient serum (10 μ L) was incubated at 4° C for 48h with 100 μ L of anti-kappa antiserum and 100 μ L of anti-lambda antiserum respectively. After centrifugation of the samples, an s-IFE was performed on both supernatants: the disappearance on the agarose gel tracks of the IgD λ and λ monoclonal bands reacted with anti IgD and anti- λ antisera respectively confirmed the presence of the complete IgD λ and λ free (**Figure 1C**).

TABLE 1 Laboratory values admission to the patient's hospital.

Tests	Patient Value	Reference Value
Haemoglobin (g/L)	9,4	13,3-17,2
s-creatinine (mg/dL)	2,85	0,67-1,17
e-GFR (mL/min/1,73m ²)	23	<100
glycemia (mg/dL)	212	8,5-10,1
calcemia (mg/dL)	8,8	3,4-5,0
albumin (g/dL)	3,6	3,3 ÷ 19,40
FLC kappa (mg/L)	92,3	5,71 ÷ 26,30
FLC lambda (mg/L)	2348	< 0,26 ÷ > 1,65*
k/ λ ratio	0,04	7,0 ÷ 16
IgG (g/L)	15,6	0,68 ÷ 3,79
IgA (g/L)	2,2	0,40 ÷ 2,30
IgM (g/L)	0,9	1 ÷ 10
IgD (mg/L)	17	0 ÷ 100
IgE (UI/ml)	9	6,4 ÷ 8,2
Total Protein (g/dL)	8,5	1,09 ÷ 2,53
β^2 microglobulin (g/dL)	9,51	<200
U-PCR (mg/g)	1258	<30
U-ACR (mg/g)	147	0 ÷ 149
dU-Total Protein (mg/24h)	1680	< 30
dU- Albumin (mg/24h)	232	

*Normal k/ λ ratio is 0.26-1.65 in a normal individuals.



Urinary immunofixation (u-IFE) on agarose gel (Hydrasis Sebia France) showed a marked presence of λ -type Bence Jones protein of 925 mg/24h.

These laboratory data led clinicians to perform an urgent hematology work-up for the diagnosis of Multiple Myeloma.

Immunophenotypic analysis by flow cytometry, performed on a bone marrow aspirate sample, showed revealed a proportion 7% of CD38 and CD138 positive plasma cells polyclonal, which had cytoplasmic lambda light chain restriction and expressed CD117, but were CD19, CD45 and CD56 negative.

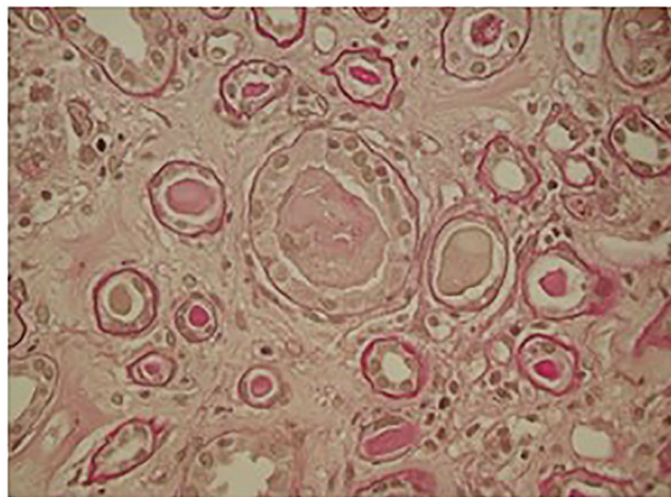


FIGURE 2
Kidney biopsy: light microscopy showed ischemic glomeruli; intratubular casts, fractured appearance giant cell cast reaction.

Immunohistochemistry on osteo-medullary biopsy sections revealed focal infiltration > 20% of plasma cells positive for CD138, immunoglobulin D heavy chain and lambda light chain. The bone marrow biopsy detected plasma cell infiltrate > 20%, positive for CD138, immunoglobulin D heavy chain and lambda light chain.

Conventional G-banding analysis revealed a normal 46 XY male karyotype, while fluorescence *in situ* hybridization (FISH) with Vysis DNA probes was negative for the most common high-risk markers.

The skeletal x-ray and total body CT were negative for osteolytic lesions; PET-CT showed widespread hypermetabolic activity throughout the bone marrow. Optical microscopy renal biopsy revealed glomeruli with signs of ischemia and thickening of the capsule and retraction of the floc; widespread signs of tubular distress with flattening of the epithelium and detachment of epithelial cells from the basement membrane and several protein cylinders in the tubular lumen, some of them showing clear margins of fracture associated with rupture of the tubular wall; Tubular atrophy associated with interstitial fibrosis was present in 50% of the cortical tissue. The microscopic picture was compatible with acute tubular necrosis with aspects of cast nephropathy (Figure 2).

The patient's final diagnosis was λ/λ IgD bicyclonal multiple myeloma and stage IV Chronic Kidney Disease (CKD stage IV).

Therapy with Bortezomib, Doxorubicin and Dexamethasone was started immediately and the patient was scheduled for autologous stem cell transplantation.

Discussion

Multiple Myeloma represents about 10% of all hematological neoplasms and IgD MM is a rare subtype of this disease (1-2%); the electrophoretic pattern is different from that of the IgA and IgG MM isotypes but more similar to the Light Chain MM isotype, in fact most of the IgD MM have a normal electrophoretic pattern or hypogammaglobulinemia. This electrophoretic specificity can be explained on the basis of the intrinsic characteristics of IgD which have an average life of 2.8 days and are present in plasma in low concentrations (0-10 mg/dL) (6, 7). To avoid that an IgD MM is erroneously diagnosed as an LCMM, laboratory investigations must include the use of anti IgD and anti IgE antisera whenever the s-IFE with standard anti-IgG, IgA, IgM, kappa and lambda antisera only shows one band monoclonal type κ or λ (8). Furthermore, the interpretation of the electrophoretic pattern can be further complicated by the presence in the patient's serum of free light chains with almost identical mobility to complete immunoglobulin (Ig). The characterization of monoclonal Ig in the serum of the patient

with monoclonal gammopathies is usually simple and a single determination is sufficient to identify the specific isotype (9). In our case, to confirm that the free light chains highlighted in the s-IFE were the product of a proliferative clone secreting free light chains and not the excess production of the complete IgD (free quota), it was necessary to carry out a further s-IFE after immunosubtraction as a further diagnostic test. The evidence on agarose gel of the disappearance of both IgD and lambda light chains has supported the hypothesis of a double neoplastic clone and the diagnosis of MM IgD λ/λ .

The analytical difficulties encountered could be related to the low IgD concentration, to the partial overlap of the second clone and, as already highlighted by other authors, to the poor avidity and inaccessibility of the anti light chain antisera in the intact Ig (10, 11). Knowledge of MM IgD λ/λ and its laboratory analytical specificities are essential to avoid a misdiagnosis of LCMM. Bence Jones proteinuria is present in 71 to 96% of patients and cast nephropathy is the most common pathophysiological mechanism of kidney damage. The light chains precipitated in the distal tubule form obstructing protein cylinders with consequent atrophy of the same and interstitial fibrosis. Acute renal failure (AKI) with no apparent cause with high 24-hour proteinuria, associated with bone pain, must lead to suspicion of IgD Multiple Myeloma (12, 13).

Clinical laboratories performing diagnostic work-up for MM should always perform s-IFE with anti-IgD and anti-IgE antisera, in the presence of a single monoclonal κ - or λ -type band, and an agarose gel after immunosubtraction as a follow-up diagnostic test when there is no correspondence in the deposition zone between the monoclonal free light chain and the heavy chain. The technique used for immunosubtraction is simple, inexpensive and allows for the integration of u-IFE and s-FLC information, directing the diagnosis towards a bicyclonal MM. This laboratory information will be useful above all in the response to therapy and will improve the patient's outcome.

Data availability statement

The original contributions presented in the study are included in the article/supplementary material. Further inquiries can be directed to the corresponding author.

Ethics statement

Ethical review and approval was not required for the study on human participants in accordance with the local legislation and institutional requirements. The participants provided their

written informed consent to participate in this study. Written Informed Consent was obtained for the publication of any potentially identifiable images or data included in this article.

Author contributions

Author Contributions: Conceptualization, TT and VB; methodology, LM and AM; Software, VB and RL; validation, FDS and TT; formal analysis, VB; investigation, LM and AM; resources, RR; data curation, RL; writing—original draft preparation, TT; writing—review and editing, TT and VB; visualization, LM and AM; supervision, TT; project administration, FDS; funding acquisition, RR. All authors have read and agreed to the published version of the manuscript.

References

1. Pisani F, Petrucci MT, Giannelli D, Bongarzone V, Montanaro M, De Stefano V, et al. IgD multiple myeloma a descriptive report of 17 cases: Survival and response to therapy. *J Exp Clin Cancer Res* (2012) 31(1):17. doi: 10.1186/1756-9966-31-17
2. Pandey S, Kyle RA. Unusual myelomas: A review of IgD and IgE variants. *Oncology (Williston Park)* (2013) 27(8):798–803.
3. Liu J, Hu X, Jia Y, Lu J, Lee JH, Kim K, et al. Clinical features and survival outcomes in IgD myeloma: A study by Asia myeloma network (AMN). *Leukemia* (2021) 35(6):1797–802. doi: 10.1038/s41375-020-01060-w
4. Modi J, Kamal J, Eter A, El-Sayegh S, El-Charabaty E. Immunoglobulin d multiple myeloma with rapidly progressing renal failure. *J Clin Med Res* (2015) 7(8):653–5. doi: 10.14740/jocmr2210w
5. Hutchison CA, Baturman V, Behrens J, Bridoux F, Sirac C, Dispenzieri A, et al. The pathogenesis and diagnosis of acute kidney injury in multiple myeloma. *Nat Rev Nephrol* (2011) 8(1):43–51. doi: 10.1038/nrneph.2011.168
6. El Maataoui A, Fares S, Taoufik A. Immunoglobulin d-lambda multiple myeloma and a review of the literature. *Clin Med Rev Case Rep* (2021) 8:341. doi: 10.23937/2378-3656/1410341
7. Selene II, Jose JA, Khalil MJ, Faisal MS, Malik MN. Presentation patterns, diagnostic markers, management strategies, and outcomes of IgD multiple

Conflict of interest

The authors declare that the research was conducted in the absence of any commercial or financial relationships that could be construed as a potential conflict of interest.

Publisher's note

All claims expressed in this article are solely those of the authors and do not necessarily represent those of their affiliated organizations, or those of the publisher, the editors and the reviewers. Any product that may be evaluated in this article, or claim that may be made by its manufacturer, is not guaranteed or endorsed by the publisher.

- myeloma: A systemic review of literature. *Cureus* (2019) 11(2):e4011. doi: 10.7759/cureus.4011
8. Willrich MAV, Murray DL, Kyr R. Laboratory testing for monoclonal gammopathies: Focus on monoclonal gammopathy of undetermined significance and smoldering multiple myeloma. *Clin Biochem* (2018) 51:38–47. doi: 10.1016/j.clinbiochem.2017.05.001
9. Katzmann JA, Hyle RA, Benson J, Larson DR, Snyder MR, Lust JA, et al. Screening panels for detection of monoclonal gammopathies. *Clin Chem* (2009) 55(8):1517–22. doi: 10.1373/clinchem.2009.126664
10. Cejka J, Kithier K. IgD myeloma protein with “Unreactive” light determinants. *Clin Chem* (1979) 25/8:1495–8. doi: 10.1093/clinchem/25.8.1495
11. Rowe DS, Fahey JL. A new class of human immunoglobulin. *J Exp Med* (1965) 121:185–99. doi: 10.1084/jem.121.1.185
12. Blade' J, Lust JA, Kyle RA. Immunoglobulin d multiple myeloma: Presenting feature, response to therapy, and survival in a series of 53 cases. *J Clin Oncol* (1994) 12(11):2398–404. doi: 10.1200/JCO.1994.12.11.2398
13. Robier C, Piribauer M. Beham-schmid c: IgD-l myeloma with extensive free light-chain excretion: A diagnostic pitfall in the identification of monoclonal gammopathies. *Clin Chem Lab Med* (2017) 55(7):e137–9. doi: 10.1515/cclm-2016-0653