



## OPEN ACCESS

## EDITED BY

Ceferino M. López Sáñez,  
University of Santiago de Compostela, Spain

## REVIEWED BY

Ji Hyung Kim,  
Gachon University, Republic of Korea  
Lusheng Xin,  
Jining Medical University, China

## \*CORRESPONDENCE

Guosi Xie

✉ xiegs@ysfri.ac.cn

Jie Huang

✉ huangjie@ysfri.ac.cn

†These authors have contributed equally to this work

RECEIVED 31 October 2023

ACCEPTED 14 December 2023

PUBLISHED 04 January 2024

## CITATION

Liu Z, Xie G, Wang H, Li X, Wan X, Li A, Zhou L, Shi C, Zhang Q and Huang J (2024) *Macrophthalmus (Macrophthalmus) abbreviatus* Manning & Holthuis, 1981, a new natural host for *Hematodinium perezii* infection. *Front. Cell. Infect. Microbiol.* 13:1328872. doi: 10.3389/fcimb.2023.1328872

## COPYRIGHT

© 2024 Liu, Xie, Wang, Li, Wan, Li, Zhou, Shi, Zhang and Huang. This is an open-access article distributed under the terms of the [Creative Commons Attribution License \(CC BY\)](https://creativecommons.org/licenses/by/4.0/). The use, distribution or reproduction in other forums is permitted, provided the original author(s) and the copyright owner(s) are credited and that the original publication in this journal is cited, in accordance with accepted academic practice. No use, distribution or reproduction is permitted which does not comply with these terms.

# *Macrophthalmus (Macrophthalmus) abbreviatus* Manning & Holthuis, 1981, a new natural host for *Hematodinium perezii* infection

Zhengmin Liu<sup>1,2,3†</sup>, Guosi Xie<sup>1,2,3\*†</sup>, Hailiang Wang<sup>2</sup>, Xinshu Li<sup>4</sup>, Xiaoyuan Wan<sup>1,2,3</sup>, Ang Li<sup>1</sup>, Liqing Zhou<sup>1</sup>, Chengyin Shi<sup>1,2,3</sup>, Qingli Zhang<sup>1,2,3</sup> and Jie Huang<sup>1,2,3,5\*</sup>

<sup>1</sup>State Key Laboratory of Mariculture Biobreeding and Sustainable Goods, Yellow Sea Fisheries Research Institute (YSFRI), Chinese Academy of Fishery Sciences (CAFS), Qingdao, China, <sup>2</sup>Laoshan National Laboratory, Qingdao, China, <sup>3</sup>Key Laboratory of Maricultural Organism Disease Control, Ministry of Agriculture and Rural Affairs, Qingdao Key Laboratory of Mariculture Epidemiology and Biosecurity, Qingdao, Shandong, China, <sup>4</sup>School of Marine Science and Fisheries, Jiangsu Ocean University, Lianyungang, China, <sup>5</sup>Network of Aquaculture Centres in Asia-Pacific, Bangkok, Thailand

Recent reports have shown that wild crabs may be important hosts involved in the transmission and spread of the parasitic *Hematodinium* in cultured marine crustaceans. Therefore, monitoring the prevalence of *Hematodinium* infections in wild crabs is necessary to develop effective strategies for the prevention and control of *Hematodinium* disease. Here we report a wild crab species, *Macrophthalmus (Macrophthalmus) abbreviatus* Manning & Holthuis, 1981, as a new natural host for *Hematodinium* sp. infection. It is one of the common wild crab species dwelling in the ponds or waterways connected to the polyculture ponds located on the coast of Rizhao or Weifang, Shandong Peninsula, China. According to the results of PCR detection and phylogenetic analysis targeting the internal transcribed spacer 1 (ITS 1) region, these *Hematodinium* sp. isolates were identified as *H. perezii* and fell into the genotype II category within *H. perezii*. A high monthly prevalence of *H. perezii* infection was observed during the 2021–2022 field survey, ranging from 33.3% to 90.6% in *M. abbreviatus* originating from Weifang (n=304 wild crabs) and from 53.6% to 92.9% in those from Rizhao (n=42 wild crabs). Artificial inoculation infection experiments demonstrated that *M. abbreviatus* could be infected by *H. perezii*, and massive *Hematodinium* cells and typical histopathological changes were observed in the hepatopancreas and gill tissues of the infected crabs. To our knowledge, this is the first report of *M. abbreviatus* as a new natural host for *H. perezii* infection. Results in the present study extend the known host spectrum for this emerging parasite pathogen, and also provide valuable information for epidemic surveillance of the *Hematodinium* disease as well.

## KEYWORDS

parasitic dinoflagellates, *Hematodinium* sp., *Hematodinium perezii*, *Macrophthalmus abbreviatus*, host

## 1 Introduction

The parasitic dinoflagellate *Hematodinium* spp., first reported in 1931 (Chatton and Poisson, 1931), infect more than 40 crustacean species worldwide (Li et al., 2021a). This parasite has been recognized as an important pathogen causing massive mortality and extensive economic losses to some economic crustaceans (Field et al., 1992; Taylor and Khan, 1995; Messick and Shields, 2000; Shields et al., 2007; Xu et al., 2007; Li et al., 2008; Ryazanova et al., 2010; Xu et al., 2010; Albalat et al., 2012; Small, 2012; Li et al., 2013; Smith et al., 2015; Stentiford et al., 2015; Wang et al., 2017; Huang et al., 2021; Ryazanova et al., 2021). Lack of knowledge in the pathogenic and transmission mechanisms of *Hematodinium* in crustaceans has hindered the development of effective management strategies for the *Hematodinium* disease (caused by the pathogenic *Hematodinium* spp.).

To date, six wild crab species, i.e. *Helice tientsinensis*, *Uca arcuata*, *Hemigrapsus penicillatus*, *Helice wuana*, *Macrophthalmus japonicus*, and *Hemigrapsus takanoi*, inhabiting the waterways connected to the polyculture ponds of marine crustaceans, have been identified as hosts for *Hematodinium* infections (Huang et al., 2019; Li et al., 2021b; Gong et al., 2023). The prevalence of *H. perezii* in *H. tientsinensis* (up to 30.1%) is much higher than in the other five wild crab species (up to 20.0%), and is positively correlated with the prevalence of *H. perezii* in cultured *Portunus trituberculatus* (Li et al., 2021b; Gong et al., 2023). *H. perezii* can be transmitted directly from *H. tientsinensis* to *P. trituberculatus*, as evidenced by the fact that healthy *P. trituberculatus* are infected by *H. perezii*, when being cohabitated with *H. perezii* infected-*H. tientsinensis* (Huang et al., 2021). The potential role of *H. tientsinensis* is highlighted in the transmission and maintenance of *Hematodinium* in the integrative culture systems (Huang et al., 2019; Huang et al., 2021).

In the years of 2021 and 2022, we carried out epidemiological surveys for the *Hematodinium* disease in wild and cultured populations of marine crustaceans, inhabiting along the coast (mainly in Rizhao and Weifang) of the Shandong Peninsula. This area is a major mariculture region for *P. trituberculatus*, contributing to over 80% of the gross outcome in northern China (data from China Fishery Statistical Yearbook in 2021). Among the wild crab species sampled in the surveys, *M. abbreviatus* was finally identified as a novel host for *H. perezii*, based on evidences from morphological observation, molecular detection, experimental challenge tests, and histopathological examination. The prevalence of *H. perezii* in *M. abbreviatus* was also presented. The results in the present study provide important information on the *H. perezii* epidemics, and will contribute to the development of an effective prevention and management strategy for this parasite in marine crustacean pond systems.

## 2 Materials and methods

### 2.1 Crab samples and the experimental conditions

During June to October in 2021 and June to August in 2022, a total of 346 *M. abbreviatus* crabs were collected from the waterways

connecting to polyculture ponds, located on the coast of Rizhao or Weifang, Shandong Province, China. These crabs were transported to the laboratory in plastic tanks with constant aeration.

In the laboratory, crabs were housed individually in perforated plastic boxes (108×108 × 42 mm, 24 holes with diameter of 3 mm) and cultured with aeration in the tanks, containing 40 L of seawater (24 ± 1°C, salinity of 30 ppt). They were fed with clams, and the residuals of clam tissue were removed timely after each feeding. 80% of culturing seawater in each tank was exchanged every day. Crabs were acclimated for a week before artificial inoculation tests.

### 2.2 Hemolymph smear assay

Hemolymph smear assays were performed as described by Stentiford and Shields (2005). Briefly, 2–3 drops of hemolymph, drawn from the juncture (prior sterilization with 70% ethanol) between the basis and ischium of the 5th walking leg, were mixed with an aliquots of neutral red (0.04%, w/v). The hemolymph smear was then screened under a light microscope (Olympus, Japan) for diagnosing and observing the status of *Hematodinium*.

### 2.3 Molecular detections for *Hematodinium*

Genomic DNA (gDNA) of hemolymph (~30 µl) sampled from natural *Hematodinium*-infected crabs and abdominal muscle (~30 mg) sampled from artificial *Hematodinium*-infected crabs were extracted by using a TIANamp Blood DNA Kit (Tiangen, China) or a TIANamp Marine Animals DNA Kit (Tiangen, China) according to the manufacturer's instructions, respectively.

*Hematodinium* were detected using nested PCR with two primer sets as previously described by Gong et al. (2023). The nested PCR targets an interval region between 18S ribosomal RNA gene and the first internal transcribed spacer (ITS 1). The outer primer set includes primers He.p-18sF1 (CAG CTC GTG CTG ATT ACG TCC C) and He.p-ITS1R1 (AAA GCC CTA ACC CCG CTA AAG G), and the inner primer set includes primers He.p-18sF2 (TCG TAA CAA GGT TTC CGT AGG T) and He.p-ITS1R2 (ATG GAG GAG TTC AGT GGT AGG C). The PCR reaction mix (25 µL) composed of 12.5 µl Premix PrimeSTAR HS (TaKaRa, Dalian, China), 1µl exacted gDNA (~10 ng), 1 µl forward and reverse primers (10 µM, each), and 9.5 µl sterile water, respectively. PCR amplifications were conducted at 95°C for 5 min, 35 cycles (94°C for 30 s, 60°C (for outer primers)/55°C (for inner primers) for 30 s, and 72°C for 60 s (for outer primers)/20 s (for inner primers)), and 72°C for 5 min. The amplicons were analyzed using 1.2% agarose gel electrophoresis, and positive products were further sequenced with the corresponding amplification primers in Sangon Biotech (Shanghai, China) Co., Ltd.

### 2.4 Phylogenetic analysis

Eight *Hematodinium* sp. ITS1 sequences (308–341 bp in length) were retrieved from naturally *Hematodinium*-infected *M.*

*abbreviatus* in the present study, and deposited in GenBank with Accession numbers of OQ564394 (retrieved from one crab originating from Rizhao), and OQ564393, OQ564395–OQ564400 (retrieved from seven crabs originating from Weifang). These ITS 1 sequences were multiply aligned with other *Hematodinium* sp. sequences originated from different crustacean hosts (Li et al., 2021a; Li et al., 2021b; Gong et al., 2023), using the software Clustal X. A phylogenetic tree was constructed by using the neighbor-joining method with 1000 bootstrap replicates embedded in MEGA 7.0 (Kumar et al., 2016).

## 2.5 Challenging tests

To evaluate the susceptibility of *M. abbreviatus* to *Hematodinium* sp., artificial inoculation infection experiments were performed according to the protocol in a previous report (Li et al., 2021b). Before inoculation infections, *M. abbreviatus* were examined for *Hematodinium* using the hemolymph smear. Negatively examined *M. abbreviatus* were used for the challenge tests. Briefly, *M. abbreviatus* (n=15) was injected with 10  $\mu$ l of hemolymph, extracted from a donor *Helice tientsinensis* heavily infected by *H. perezii*, and containing  $1.46 \times 10^4$  parasites/ $\mu$ l, assessed by using a hemocytometer under a microscope. The gDNA extracted from a hemolymph sample was used for detection of *Hematodinium* via the nested PCR assays. The PCR amplicons were confirmed after sequencing.

## 2.6 Histopathological analysis

Tissues (gills, heart, hepatopancreas, and muscle) dissected from *Hematodinium* detection-negative or positive crabs were immediately immersed in Davidson's AFA for 24 h. After fixation, these fixed tissues were transferred to serial alcohol and dimethylbenzene, and embedded in paraffin. The sections were stained with hematoxylin and eosin (H&E), using routine histological method as described by (Wheeler et al., 2007), and subsequently photographed under a light microscope (Olympus, Japan).

## 3 Results

### 3.1 Morphology of *Hematodinium* sp. in the hemolymph from naturally infected *M. abbreviatus*

*Hematodinium* sp. exhibited various shapes were observed in the hemolymph from the naturally *Hematodinium*-infected crabs, which indicates different developmental stages in the lifecycle of *Hematodinium*. They were ameboid trophonts (e.g., uninucleate, binuclear, trinuclear and multinucleate) (Figures 1A, B) and presumptive clump colonies (Figure 1C).

### 3.2 Prevalence of *Hematodinium* infections in *M. abbreviatus*

Considerable prevalence of *H. perezii* infections existed in *M. abbreviatus* originated from Weifang (the averaged prevalence rate of 62.2%; n=304) or Rizhao (66.7%; n=42). On the month scale, the prevalence in specific varied from 33.3% to 90.6% in Weifang samples, and from 53.6% to 92.9% in Rizhao samples (Figure 2). The overall prevalence in these samples originated from the two regions during investigations in years 2021 and 2022 was 62.7% (n=346).

### 3.3 Phylogenetic and taxonomic analyses

Eight *Hematodinium* ITS 1 sequences (265 or 266 bp in length) were retrieved from *M. abbreviatus* collected from Weifang and Rizhao and they shared 99.6–100% sequence similarity with each other. In addition, multiple sequence alignments showed that they shared high similarity (97.8–100%) with those of *H. perezii* genotypes I and II, which infect crustacean species such as *P. trituberculatus*, *S. paramamosain*, *P. monodon*, and *H. tientsinensis* in China (Small et al., 2012; Wang et al., 2017; Huang et al., 2019; Li et al., 2021b), while they shared relatively lower similarity (95.9%–96.7%) with that of *H. perezii* genotype III

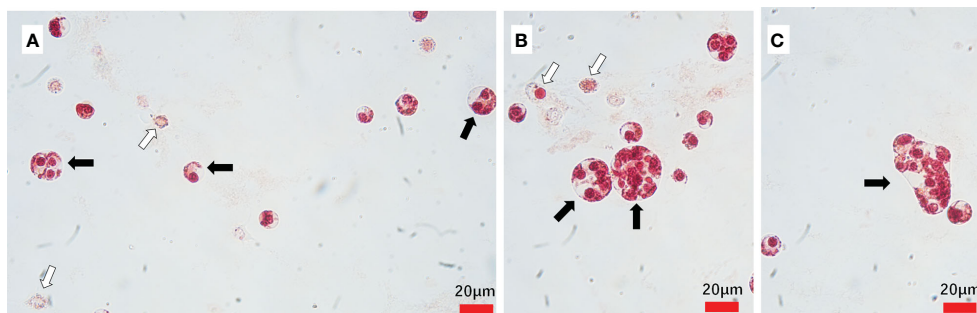


FIGURE 1

*Hematodinium* staining and examination in the hemolymph from naturally infected *M. abbreviatus*. Uninucleate, binuclear and trinuclear ameboid trophonts (A) Multinucleate ameboid trophonts (B) Putative clump colony (C). Black arrows indicate parasites and white arrow indicate host haemocytes.

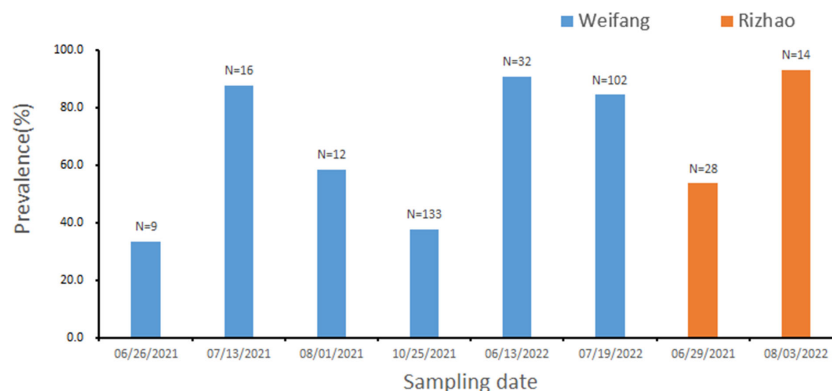


FIGURE 2  
Prevalence of *Hematodinium* infections in *M. abbreviatus*, collected from Rizhao and Weifang during the sampling period. The total sample number are shown over each bar.

isolates, infecting *Callinectes sapidus* in USA (Jensen et al., 2010), and other *Hematodinium* isolates ( $\leq 63.5\%$ ).

The phylogenetic analysis based on ITS1 sequences indicated that the eight *Hematodinium* isolates in the present study were all grouped into *H. perezii* genotype II (Figure 3), which together with that other isolates reported in China, e.g., *P. trituberculatus*, *P. monodon*, *S. paramamosain*, *H. tientsinensis*, and *H. takanoi* (Small et al., 2012; Wang et al., 2017; Huang et al., 2019; Li et al., 2021b; Gong et al., 2023). Taken together, the *Hematodinium* isolates in *M. abbreviatus* were taxonomically identified as *H. perezii* and belonged to the genotype II.

### 3.4 *H. perezii* confirmed in the hemolymph from artificially challenged *M. abbreviatus*

Massive *Hematodinium* ameboid cells were observed in the hemolymph of artificially inoculated *H. perezii*-infected crabs, whereas haemocytes were rare in this sample (Figures 4A, B). The hemolymph samples were positive for *Hematodinium* and identified as *H. perezii* based on the results of PCR and phylogenetic analysis.

### 3.5 Histopathology caused by *Hematodinium* infections

The histopathology caused by natural and artificial *H. perezii* infections in *M. abbreviatus* was examined. Compared to the histology of *Hematodinium*-negative crabs (Figures 5A–D), obvious histopathological changes were observed in the tissues of hepatopancreas and gills of *M. abbreviatus* suffering from natural *Hematodinium* infection (Figures 6A–D). The prominent V-shaped chromosomes characteristic of syndinean dinoflagellates were observed in hepatopancreas (Figure 6B) and gills (Figure 6D), whereas these parasites were rarely observed in heart and muscle, probably due to light infections. Granulomas were also observed in the diseased gills (Figure 6C).

In inoculated crabs at 25-day post-infection, the hepatopancreas was severely altered due to the invasion of *Hematodinium* parasites, the spongy connective tissue around the hepatopancreatic tubules appeared to be diminished, and haemocytes were barely observed. The enlarged hemal space among the hepatopancreatic tubules was filled with massive numbers of parasites, while the hepatopancreatic tubules appeared intact and no parasites were observed within the lumen proper of the hepatopancreatic tubules. In addition, fixed phagocytes which were enlarged and activated were observed, probably in response of tissue degradation or parasite infection (Figures 7A, B). In the gills, a number of *Hematodinium* parasites were observed in the gill stem and filaments. The epithelium was deformed and appeared to be necrotic, and reduction or loss of spongy connective tissue was also observed. In some of the gill lamellae, necrosis of the connective tissue, and loss or necrosis of the trabecular cells were observed due to parasite infection (Figures 7C–F). The released spores were also observed between adjacent lamellae (Figure 7D). In abdominal muscle tissue, the intact structure of the muscle fibers was distorted and lost its normal dense appearance due to interstitial infiltrates of parasites (Figure 7G). In the heart tissue, the heart muscle lost its normal dense appearance and the myocardial fibers showed a reduction or loss of spongy connective tissue, separated by parasite cell invasion (Figure 7H).

## 4 Discussion

Since 2013, frequent outbreaks of the *Hematodinium* disease have led to serious economic losses to the cultured *P. trituberculatus* in coastal areas of the Shandong Peninsula. Considering the fact that hosts play an important role in occurrence and spread of parasitic diseases, it is important to conduct epidemic surveillance for hosts of *Hematodinium* sp. In the present study, we demonstrated that *M. abbreviatus* is a new natural host of *H. perezii*. This finding together with previous publications show that *H. perezii* genotype II can infect various marine crustaceans (e.g. *H. takanoi*, *P. trituberculatus*, *H. tientsinensis*, *S. paramamosain* and *P. monodon*) under a wide host range in China (Small et al., 2012; Wang et al., 2017; Huang et al.,



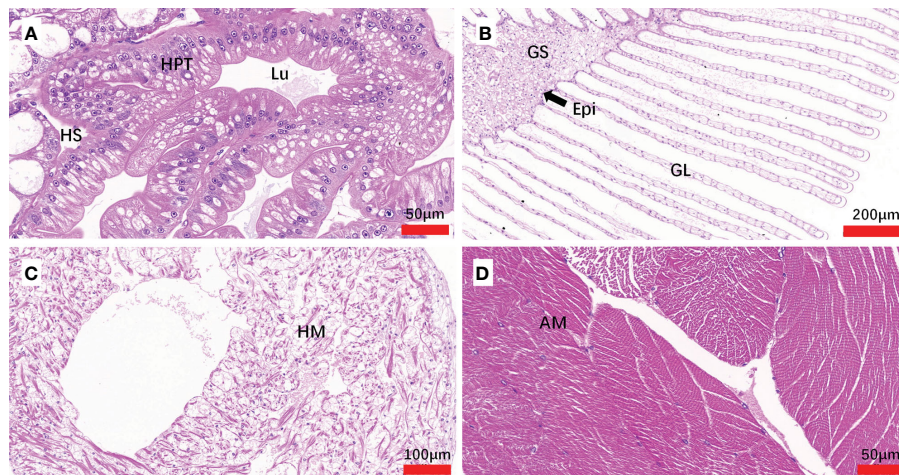


FIGURE 5

Sections of tissues from *Hematodinium* infection-negative *M. abbreviatus*. Hepatopancrea (A), gill (B), heart (C) and abdominal muscle (D) tissue. H&E staining. HPT, Hepatopancreatic tubule; Lu, lumen of hepatopancreatic tubules; HS, hemal space; Epi, epithelium; GS, Gill stem; GL Gill lamellae; HM, heart muscle; AM, abdominal muscle.

higher than that in the cultured *P. trituberculatus* (unpublished data) in 2021. When compared with the data from a previous survey from June to October in 2018 in Qingdao, China (Li et al., 2021b), which is adjacent to the sampling site in the present study, the monthly prevalence of *H. perezi* in *M. abbreviatus* was also much higher than that in *H. tientsinensis* (9.4%-30.1%) and the cultured *P. trituberculatus* (3.0%-55.7%). In addition, *M. abbreviatus* is a migratory species in the integrative culture ponds and a dominant species of the most common wild crab species, dwelling in the

polyculture ponds or in the waterways connected to the polyculture pond system along the coast of the Shandong Peninsula. Therefore, it is reasonable to assume that *M. abbreviatus* as well as other co-inhabiting crabs are likely important alternates or reservoir hosts involved in transmission and maintenance of *Hematodinium*. It requires further investigations to determine whether *M. abbreviatus* is more susceptible to *Hematodinium* infection compared to *P. trituberculatus* and/or other reported wild crabs, and the exact role of *M. abbreviatus* in the epizootiology of *Hematodinium* disease.

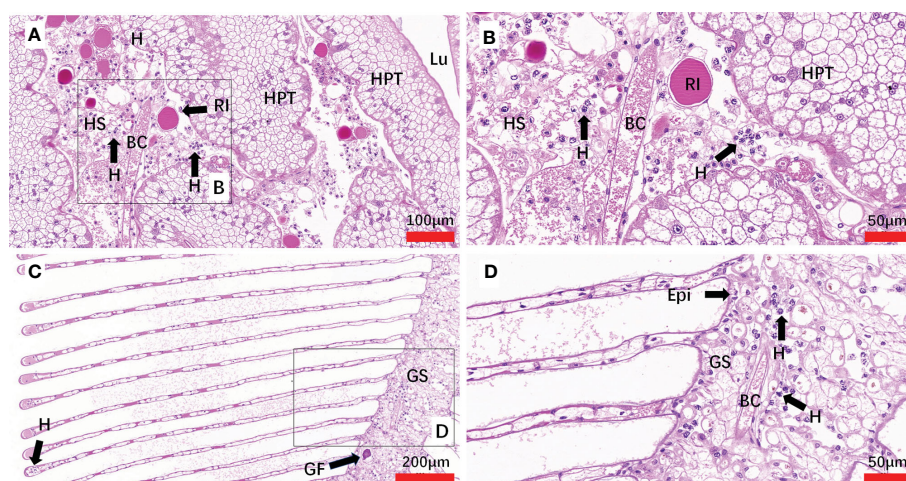


FIGURE 6

Sections of tissues from naturally *Hematodinium*-infected *M. abbreviatus*. Hepatopancrea (A, B) and gill (C, D). Note uniuclate ameboid trophonts with V-shaped chromatin in the nucleus were observed in Hepatopancrea (B) and gill (D). A granulomas was present in the gill tissues (C). H&E staining. HPT, Hepatopancreatic tubule; Lu, lumen of hepatopancreatic tubules; HS, hemal space; BC, blood channel; H, *Hematodinium* cells; P, fixed phagocytes; RI, reserve inclusion cells; GF, granuloma formation; Epi, epithelium; GS, Gill stem; GL Gill lamellae.

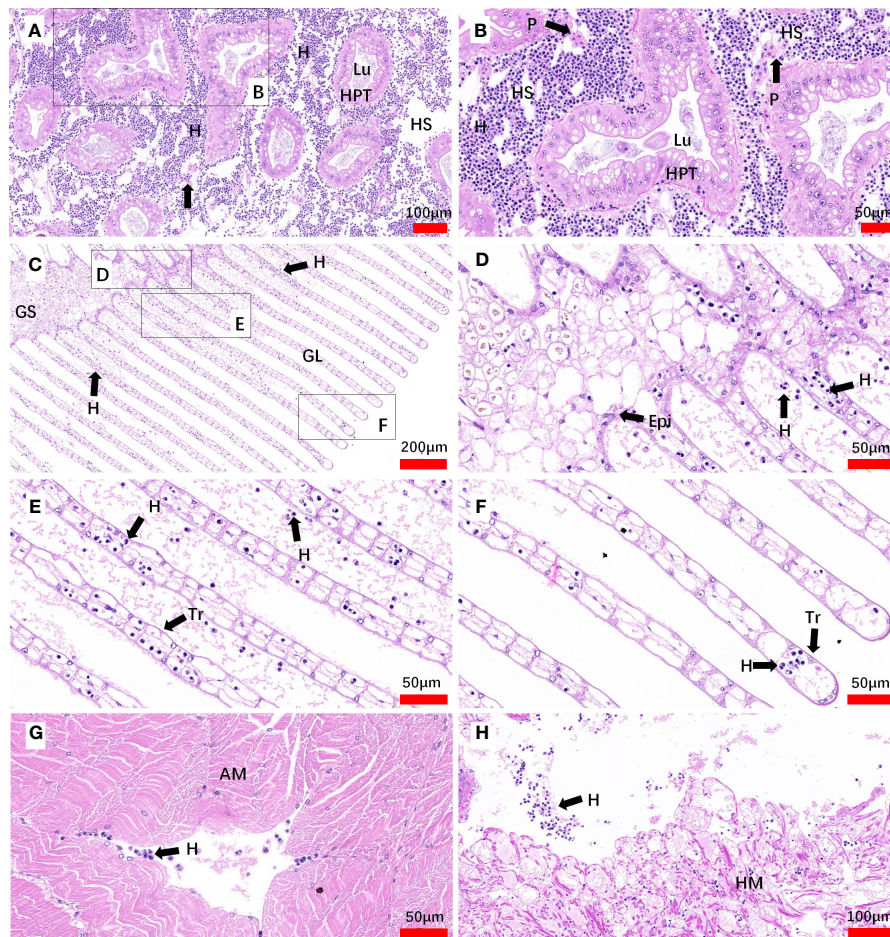


FIGURE 7

Sections of tissues from artificial inoculation *Hematodinium*-infected *M. abbreviatus*. Hepatopancrea (A, B), gill (C–F), abdominal muscle (G) and heart (H) tissue of infected crab. H&E staining. HPT, Hepatopancreatic tubule; Lu, lumen of hepatopancreatic tubules; HS, hemal space; H, *Hematodinium* cells; P, fixed phagocytes; Epi, epithelium; GS, Gill stem; GL Gill lamellae; Tr, trabecular cell; AM, abdominal muscle; HM, heart muscle.

## 5 Conclusions

In summary, to our knowledge, this is the first report of naturally infected *M. abbreviatus* with *H. perezii*. *M. abbreviatus* with a high prevalence of *H. perezii* infections indicates that more attention should be paid to their potential risk in *Hematodinium* epizootics. The present study extends the known hosts for *H. perezii*, and also provides important information for monitoring and designing effective management strategies for *Hematodinium* disease in marine crustacean aquaculture in China.

## Data availability statement

The datasets presented in this study can be found in online repositories. The names of the repository/repository and accession number(s) can be found in the article/supplementary material.

## Ethics statement

The animal study was approved by Since the Ethical Principles and Guidelines for the Use of Animals of the National Research Council of China apply to vertebrates only, there is no official standard for invertebrates. We adapted its principles to shrimp. All of the animal experiments were performed according to local government regulations and the protocols were approved by the Animal Ethics Committee of the Yellow Sea Fisheries Institute, Chinese Academy of Fishery Sciences. The study was conducted in accordance with the local legislation and institutional requirements.

## Author contributions

ZL: Investigation, Project administration, Writing – original draft, Formal analysis. GX: Writing – original draft, Writing – review &

editing, Conceptualization, Data curation, Formal analysis, Funding acquisition, Investigation, Methodology, Project administration, Resources, Software, Supervision, Validation, Visualization. HW: Formal analysis, Methodology, Supervision, Writing – original draft, Writing – review & editing. XL: Methodology, Writing – review & editing, Formal analysis. XW: Methodology, Software, Supervision, Writing – review & editing. AL: Methodology, Writing – review & editing. LZ: Methodology, Writing – review & editing. CS: Supervision, Writing – review & editing. QZ: Formal analysis, Writing – review & editing. JH: Conceptualization, Funding acquisition, Project administration, Resources, Supervision, Writing – review & editing.

## Funding

The author(s) declare financial support was received for the research, authorship, and/or publication of this article. This study was supported by the Joint Research Fund of the National Natural Science Foundation of China (NNSFC)–Shandong Province (U1906214), the Central Public-Interest Scientific Institution Basal Research Fund, CAFS (NO. 2023TD42), and the Project of Species Conservation from the Ministry of Agriculture and Rural Affairs-Marine Fisheries Resources Collection and Preservation.

## References

- Albalat, A., Gornik, S. G., Beevers, N., Atkinson, R. J. A., Miskin, D., and Neil, D. M. (2012). *Hematodinium* sp. infection in Norway lobster *Nephrops norvegicus* and its effects on meat quality. *Dis. Aquat. Organ.* 100, 105–112. doi: 10.3354/dao02500
- Chatton, E. P. L., and Poisson, R. (1931). Sur l'existence dans la sang des crabes, de péridiniens parasites: *Hematodinium perezii* n.g., n. sp. (Syndinidae). *C.R. Seances Soc. Biol. Paris* 1931 105, 553–557.
- Field, R., Chapman, C., Taylor, A., Neil, D., and Vickerman, K. (1992). Infection of the Norway lobster *Nephrops norvegicus* by a *Hematodinium*-like species of dinoflagellate on the west coast of Scotland. *Dis. Aquat. Organ.* 13, 1–15. doi: 10.3354/dao013001
- Gong, M., Xie, G., Wang, H., Li, X., Li, A., Wan, X., et al. (2023). *Hematodinium perezii* naturally infects Asian brush-clawed crab (*Hemigrapsus takanoi*). *J.Fish.Dis.* 46, 67–74. doi: 10.1111/jfd.13718
- Huang, Q., Li, M., Wang, F., and Li, C. (2019). The parasitic dinoflagellate *Hematodinium perezii* infecting mudflat crabs, *Helice tientsinensis*, in polyculture system in China. *J. Invertebr. Pathol.* 166, 107229. doi: 10.1016/j.jip.2019.107229
- Huang, Q., Li, M., Wang, F., Song, S., and Li, C. (2021). Transmission pattern of the parasitic dinoflagellate *Hematodinium perezii* in polyculture ponds of coastal China. *Aquaculture* 538, 736549. doi: 10.1016/j.aquaculture.2021.736549
- Jensen, P. C., Califf, K., Lowe, V., Hauser, L., and Morado, J. F. (2010). Molecular detection of *Hematodinium* sp. in Northeast Pacific *Chionoecetes* spp. and evidence of two species in the Northern Hemisphere. *Dis. Aquat. Organ.* 89, 155–166. doi: 10.3354/dao02193
- Kumar, S., Stecher, G., and Tamura, K. (2016). MEGA7: molecular evolutionary genetics analysis version 7.0 for bigger datasets. *Mol. Biol. Evol.* 33, 1870–1874. doi: 10.1093/molbev/msw054
- Li, M., Huang, Q., Lv, X., Song, S., and Li, C. (2021b). The parasitic dinoflagellate *Hematodinium* infects multiple crustaceans in the polyculture systems of Shandong Province, China. *J. Invertebr. Pathol.* 178, 107523. doi: 10.1016/j.jip.2020.107523
- Li, C., Li, M., and Huang, Q. (2021a). The parasitic dinoflagellate *Hematodinium* infects marine crustaceans. *Mar. Life. Sci. Technol.* 3, 313–325. doi: 10.1007/s42995-020-00061-z
- Li, C., Song, S., Liu, Y., and Chen, T. (2013). *Hematodinium* infections in cultured Chinese swimming crab, *Portunus trituberculatus*, in northern China. *Aquaculture* 396, 59–65. doi: 10.1016/j.aquaculture.2013.02.022
- Li, Y. Y., Xia, X. A., Wu, Q. Y., Liu, W. H., and Lin, Y. S. (2008). Infection with *Hematodinium* sp. in mud crabs *Scylla serrata* cultured in low salinity water in southern China. *Dis. Aquat. Organ.* 82, 145–150. doi: 10.3354/dao01988
- Messick, G. A., and Shields, J. D. (2000). Epizootiology of the parasitic dinoflagellate *Hematodinium* sp. in the American blue crab *Callinectes sapidus*. *Dis. Aquat. Organ.* 43, 139–152. doi: 10.3354/dao043139
- Ryazanova, T., Eliseikina, M., and Kukhlevsky, A. (2021). First detection of *Hematodinium* sp. in spiny king crab *Paralithodes brevipes*, and new geographic areas for the parasite in tanner crab *Chionoecetes bairdi*, and red king crab *Paralithodes camtschaticus*. *J. Invertebr. Pathol.* 184, 107651. doi: 10.1016/j.jip.2021.107651
- Ryazanova, T., Eliseikina, M., Kukhlevsky, A., and Kharlamenko, V. (2010). *Hematodinium* sp. infection of red *Paralithodes camtschaticus* and blue *Paralithodes platypus* king crabs from the Sea of Okhotsk, Russia. *J. Invertebr. Pathol.* 105, 329–334. doi: 10.1016/j.jip.2010.07.009
- Shields, J. D., Taylor, D. M., O'Keefe, P. G., Colbourne, E., and Hynick, E. (2007). Epidemiological determinants in outbreaks of bitter crab disease (*Hematodinium* sp.) in snow crabs *Chionoecetes opilio* from Conception Bay, Newfoundland, Canada. *Dis. Aquat. Organ.* 77, 61–72. doi: 10.3354/dao01825
- Small, H. J. (2012). Advances in our understanding of the global diversity and distribution of *Hematodinium* spp.—Significant pathogens of commercially exploited crustaceans. *J. Invertebr. Pathol.* 110, 234–246. doi: 10.1016/j.jip.2012.03.012
- Small, H. J., Shields, J. D., Reece, K. S., Bateman, K., and Stentiford, G. D. (2012). Morphological and molecular characterization of *Hematodinium perezii* (Dinophyceae: Syndiniales), a dinoflagellate parasite of the harbour crab, *Liocarcinus depurator*. *J. Eukaryot. Microbiol.* 59, 54–66. doi: 10.1111/j.1550-7408.2011.00592.x
- Smith, A. L., Hirschle, L., Vogan, C. L., and Rowley, A. F. (2015). Parasitization of juvenile edible crabs (*Cancer pagurus*) by the dinoflagellate, *Hematodinium* sp.: pathobiology, seasonality and its potential effects on commercial fisheries. *Parasitology*. 142, 428–438. doi: 10.1017/S0031182014001255
- Stentiford, G., Neil, D., Albalat, A., Milligan, R., and Bailey, N. (2015). The effect of parasitic infection by *Hematodinium* sp. on escape swimming and subsequent recovery in the Norway lobster, *Nephrops norvegicus* (L.). *J. Crustacean. Biol.* 35, 1–10. doi: 10.1163/1937240X-00002296

## Acknowledgments

We thank Dr Meng Li (Institute of Oceanology, Chinese Academy of Sciences) for providing us the donor *Helice tientsinensis* with heavy infection by *Hematodinium perezii*.

## Conflict of interest

The authors declare that the research was conducted in the absence of any commercial or financial relationships that could be construed as a potential conflict of interest.

## Publisher's note

All claims expressed in this article are solely those of the authors and do not necessarily represent those of their affiliated organizations, or those of the publisher, the editors and the reviewers. Any product that may be evaluated in this article, or claim that may be made by its manufacturer, is not guaranteed or endorsed by the publisher.



Stentiford, G. D., and Shields, J. D. (2005). A review of the parasitic dinoflagellates *Hematodinium* species and *Hematodinium*-like infections in marine crustaceans. *Dis. Aquat. Organ.* 66, 47–70. doi: 10.3354/dao066047

Taylor, D., and Khan, R. (1995). Observations on the occurrence of *Hematodinium* sp. (Dinoflagellata: Syndinidae), the causative agent of bitter crab disease in Newfoundland snow crab (*Chionoecetes opilio*). *J. Invertebr. Pathol.* 65, 283–288. doi: 10.1006/jipa.1995.1043

Wang, J., Li, M., Xiao, J., Xu, W., and Li, C. (2017). *Hematodinium* spp. infections in wild and cultured populations of marine crustaceans along the coast of China. *Dis. Aquat. Organ.* 124, 181–191. doi: 10.3354/dao03119

Wheeler, K., Shields, J. D., and Taylor, D. M. (2007). Pathology of *Hematodinium* infections in snow crabs (*Chionoecetes opilio*) from Newfoundland, Canada. *J. Invertebr. Pathol.* 95, 93–100. doi: 10.1016/j.jip.2007.01.002

Xu, W., Shi, H., Xu, H., and Small, H. (2007). Preliminary study on the *Hematodinium* infection in cultured *Portunus trituberculatus*. *Acta Hydrobiologica Sin.* 31, 637–640. doi: 10.3321/j.issn:1000-3207.2007.05.004

Xu, W., Xie, J., Shi, H., and Li, C. (2010). *Hematodinium* infections in cultured ridgetail white prawns, *Exopalaemon carinicauda*, in eastern China. *Aquaculture* 300, 25–31. doi: 10.1016/j.aquaculture.2009.12.024