



OPEN ACCESS

EDITED AND REVIEWED BY
Claus Bachert,
University Hospital Münster, Germany

*CORRESPONDENCE

Hai Wang,
✉ 814899096@qq.com
Zheng Liu,
✉ zhengliuent@hotmail.com

RECEIVED 16 June 2024

ACCEPTED 03 July 2024

PUBLISHED 18 July 2024

CITATION

Ruan J-W, Zhao J-F, Li X-L, Liao B, Pan L,
Zhu K-Z, Feng Q-M, Liu J-X, Yu Z-E, Song J,
Wang H and Liu Z (2024), Corrigendum:
Characterizing the neutrophilic inflammation in
chronic rhinosinusitis with nasal polyps.
Front. Cell Dev. Biol. 12:1450040.
doi: 10.3389/fcell.2024.1450040

COPYRIGHT

© 2024 Ruan, Zhao, Li, Liao, Pan, Zhu, Feng, Liu,
Yu, Song, Wang and Liu. This is an open-access
article distributed under the terms of the
[Creative Commons Attribution License \(CC BY\)](#).
The use, distribution or reproduction in other
forums is permitted, provided the original
author(s) and the copyright owner(s) are
credited and that the original publication in this
journal is cited, in accordance with accepted
academic practice. No use, distribution or
reproduction is permitted which does not
comply with these terms.

Corrigendum: Characterizing the neutrophilic inflammation in chronic rhinosinusitis with nasal polyps

Jian-Wen Ruan, Jie-Fang Zhao, Xue-Li Li, Bo Liao, Li Pan,
Ke-Zhang Zhu, Qi-Miao Feng, Jin-Xin Liu, Zi-E. Yu, Jia Song,
Hai Wang* and Zheng Liu*

Department of Otolaryngology-Head and Neck Surgery, Tongji Hospital, Tongji Medical College, Huazhong University of Science and Technology, Wuhan, China

KEYWORDS

apoptosis, chronic rhinosinusitis with nasal polyps, granulocyte colonystimulating factor, neutrophil, inflammation

A Corrigendum on Characterizing the neutrophilic inflammation in chronic rhinosinusitis with nasal polyps

by Ruan J-W, Zhao J-F, Li X-L, Liao B, Pan L, Zhu K-Z, Feng Q-M, Liu J-X, Yu Z-E, Song J, Wang H and Liu Z (2021). *Front. Cell Dev. Biol.* 9:793073. doi: [10.3389/fcell.2021.793073](#)

In the published article, there was an error in [Figure 1B](#) as published. (In the Neu-low NP panel in [Figure 1B](#), an image from Neu-high NP group was mistakenly inserted). The corrected ([Figure 1](#)) and its caption appear below.

The authors apologize for this error and state that this does not change the scientific conclusions of the article in any way. The original article has been updated.

Publisher's note

All claims expressed in this article are solely those of the authors and do not necessarily represent those of their affiliated organizations, or those of the publisher, the editors and the reviewers. Any product that may be evaluated in this article, or claim that may be made by its manufacturer, is not guaranteed or endorsed by the publisher.

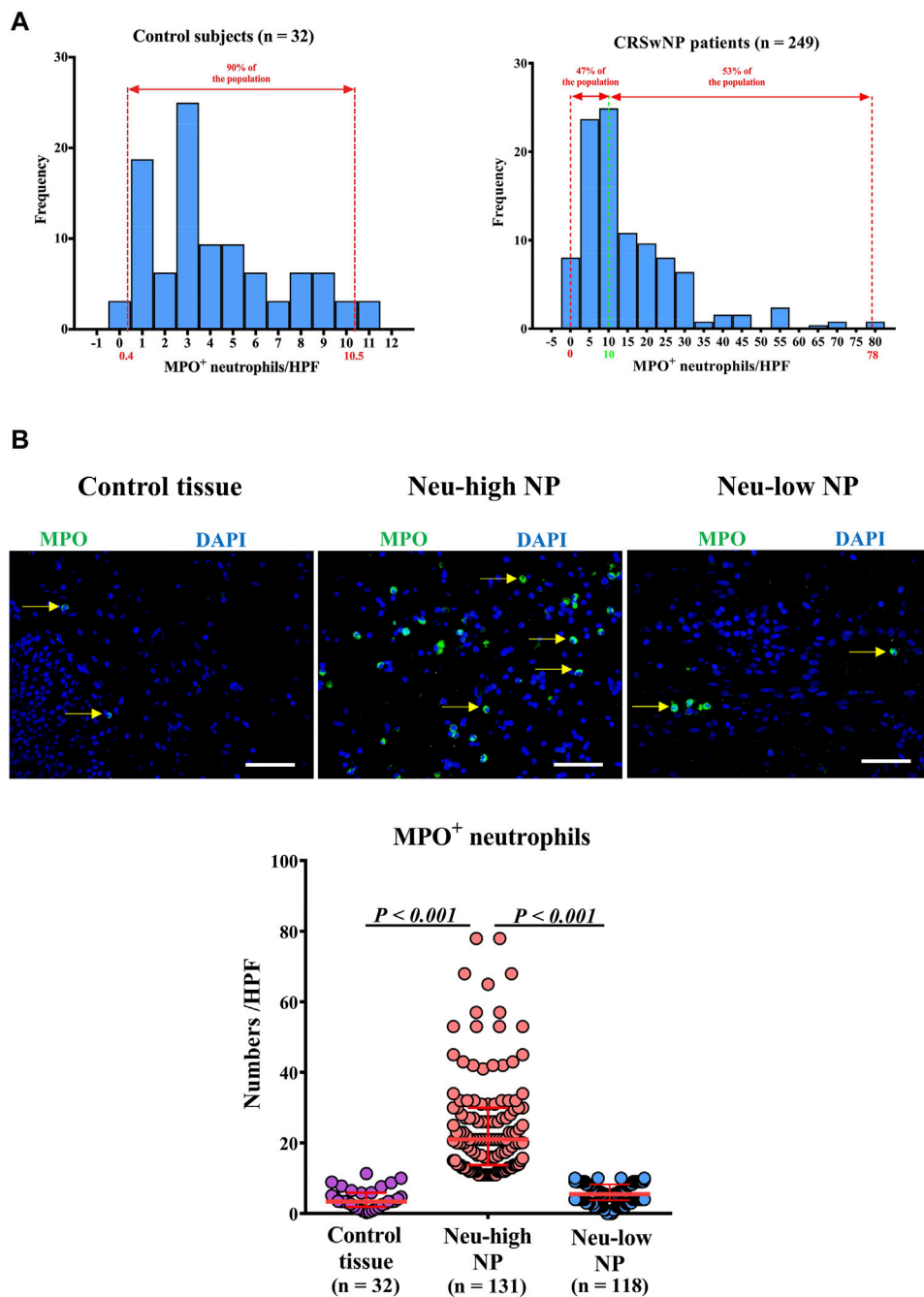


FIGURE 1 Distribution of tissue neutrophils in patients with CRSwNP. **(A)** Distribution of tissue neutrophils in control subjects (right panel) and CRSwNP patients (left panel). The red dotted lines represent 5th percentile (0.4) and 95th percentile (10.5) in the left panel. The red dotted lines represent minimum (0) and maximum (78.0), and the green dotted line represents the cut-off value (10) to define Neu-low and Neu-high NPs in the right panel. **(B)** Representative photomicrographs showing immunofluorescence staining of MPO positive cells and quantification of MPO positive cells. Original magnification $\times 400$. Scale bar, 100 μm . Arrows denote representative positive cells. CRSwNP, chronic rhinosinusitis with nasal polyps; NP, nasal polyp; Neu-high, neutrophil-high; Neu-low, neutrophil-low; MPO, myeloperoxidase; HPF, high-power field.