



Case Report: Residual Atrial Shunt Lesions in Aging Adults With Congenital Heart Disease: An Underestimated Risk of Stroke?

Matthias Schneider^{1,2*}, Varius Dannenberg³, Bernd Opgen-Rhein⁴, Felix Berger^{2,4}, Burkert Pieske^{1,2,5,6}, Harald Gabriel³ and Leif-Hendrik Boldt^{1,5}

¹ Department of Internal Medicine and Cardiology, Charité Universitätsmedizin Berlin, Berlin, Germany, ² German Heart Center Berlin, Berlin, Germany, ³ Department of Internal Medicine II, Cardiology, Medical University of Vienna, Vienna, Austria, ⁴ Department of Pediatric Cardiology, Charité Universitätsmedizin Berlin, Berlin, Germany, ⁵ German Centre for Cardiovascular Research (DZHK), Berlin, Germany, ⁶ Berlin Institute of Health, Berlin, Germany

OPEN ACCESS

Edited by:

Martin Koestenberger,
Medical University of Graz, Austria

Reviewed by:

Omar R. J. Tamimi,
King Fahd Medical City, Saudi Arabia
Michal Odermarsky,
Skåne University Hospital, Sweden

*Correspondence:

Matthias Schneider
matthias.schneider@charite.de

Specialty section:

This article was submitted to
Pediatric Cardiology,
a section of the journal
Frontiers in Cardiovascular Medicine

Received: 01 January 2022

Accepted: 21 February 2022

Published: 16 March 2022

Citation:

Schneider M, Dannenberg V,
Opgen-Rhein B, Berger F, Pieske B,
Gabriel H and Boldt L-H (2022) Case
Report: Residual Atrial Shunt Lesions
in Aging Adults With Congenital Heart
Disease: An Underestimated Risk
of Stroke?
Front. Cardiovasc. Med. 9:847244.
doi: 10.3389/fcvm.2022.847244

We report two cases of paradoxical cerebral embolism in adults with congenital heart disease (ACHD) with residual atrial shunt lesions, a 59 year-old male patient with partial detachment of a surgical ASD closure patch, and a 57 year-old male patient with Ebstein's anomaly and a large patent foramen ovale. Considering these mechanisms and the increasing incidence of venous thrombosis with age, a higher prevalence of paradoxical embolism in ACHD patients with residual atrial shunts may be suspected. Regular follow-up of patients with ACHD remains important throughout life even in seemingly stable lesions.

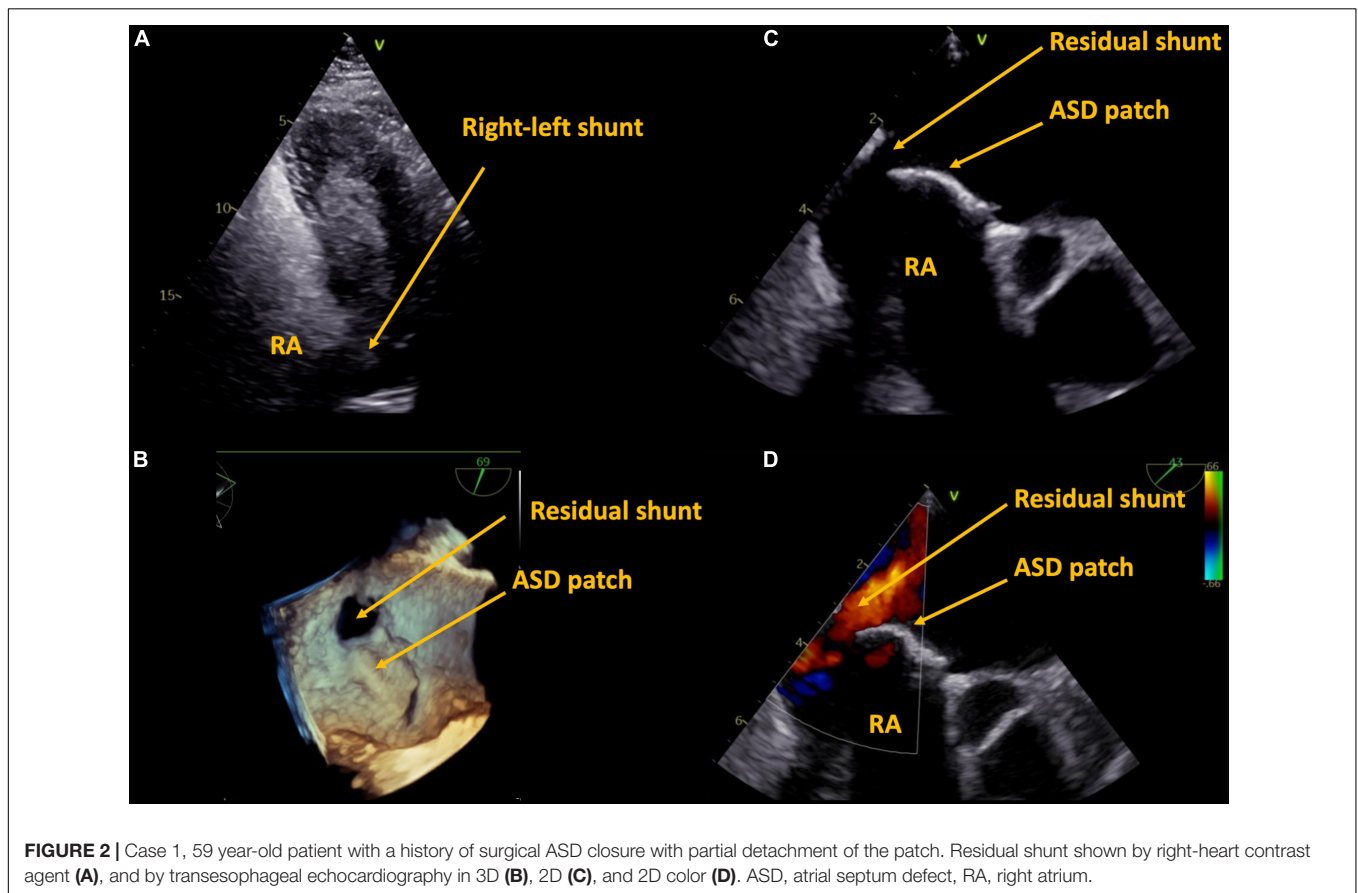
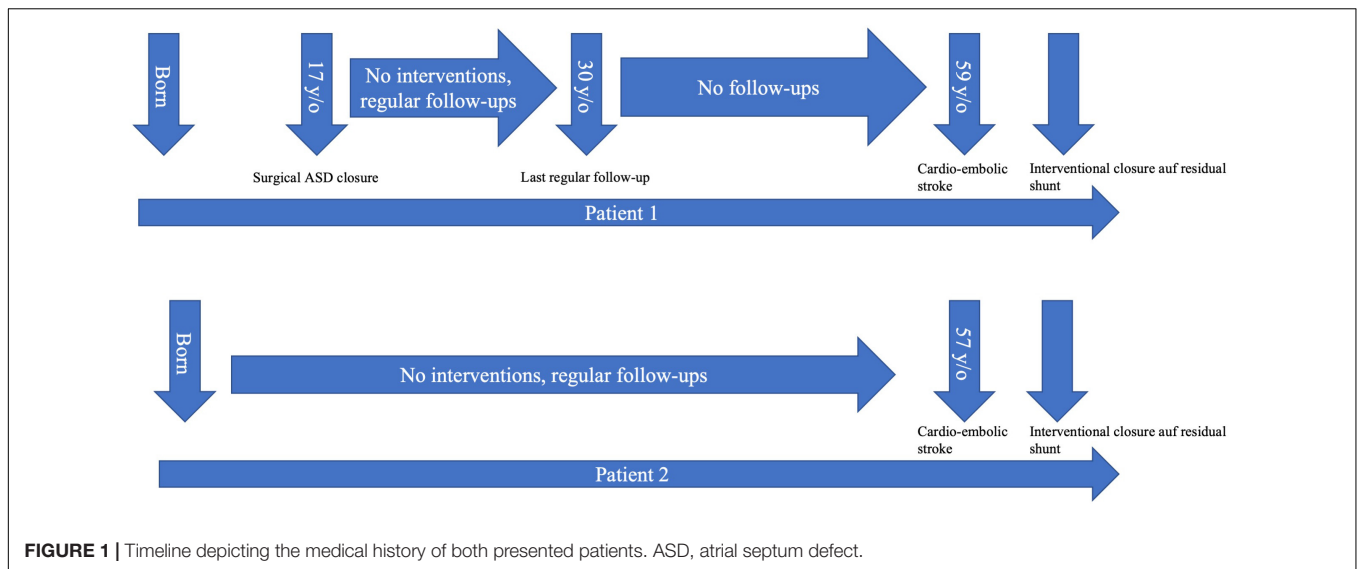
Keywords: embolic stroke, adults with congenital heart disease, echocardiography, cardioembolic and cryptogenic stroke, Ebstein anomaly, ASD, case report

INTRODUCTION

The number of aging adults with congenital heart disease (ACHD) is constantly growing, as are late sequelae in this cohort (1). The risk for ischemic stroke is eleven times higher in young patients with CHD when compared to controls (2), the cumulative risk between the ages of 18 and 64 years is 6–8% (3). The majority of events occur in patients with cyanotic defects and in those without sinus rhythm (4). Arrhythmias are common in ACHD patients (5), in particular there is a high prevalence of atrial arrhythmias (6, 7). While paradoxical embolism *via* a patent foramen ovale (PFO) is associated with cryptogenic stroke in the general population and PFO closure reduces the rate of subsequent events in selected patients (8–10), up to now cryptogenic stroke has not been investigated systematically in ACHD patients.

CASE PRESENTATION

We report two cases of paradoxical cerebral embolism in ACHD patients with residual atrial shunt lesions (**Figure 1**). The first patient is a 59 year-old male who had received surgical repair of



secundum atrial septum defect (ASD) 42 years ago. There were no regular follow-ups after the age of 30, his further medical history was unremarkable, exercise capacity was excellent. The patient presented to our hospital with acute embolic stroke. Transesophageal echocardiography revealed a residual atrial septal defect in the posterior inferior region due to partial

detachment of the surgical patch (Figure 2) with spontaneous transfer of ultrasound contrast agent from right to left. The right ventricle was of borderline size, calculated Qp:Qs was 1.4:1. In absence of other reasons for embolic stroke (non-smoker, no dyslipidemia, no arterial hypertension, no history of atrial fibrillation, and unremarkable carotid ultrasound), paradoxical

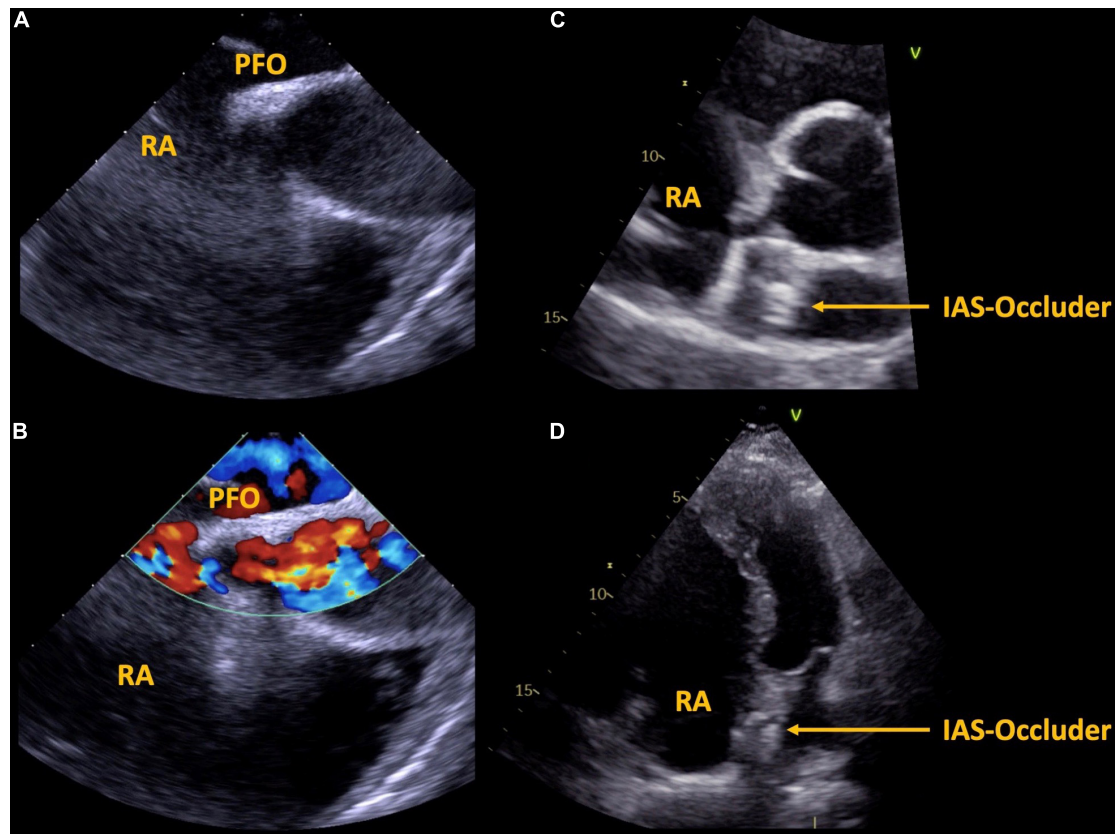


FIGURE 3 | Case 2, 57 year-old patient with Ebstein's anomaly. A large PFO is shown via transesophageal echocardiography without (A) and with (B) color Doppler imaging. Interventional septal occluder implantation was performed, the result is shown in panels (C,D). PFO, patent foramen ovale, IAS, inter atrial septum, RA, right atrium.

embolism was assumed and interventional closure of the residual atrial septum defect was performed with a 25 mm septal occluder device.

The second patient is a 57 year-old male with known Ebstein's anomaly. Exercise capacity had been unchanged for years as were right heart dimensions. This patient also presented with embolic stroke. The patient was a non-smoker, there was no history of dyslipidemia, arterial hypertension, or atrial fibrillation, carotid ultrasound was unremarkable). TEE revealed a large PFO with spontaneous transfer of ultrasound contrast agent from right to left (Figure 3). Paradoxical embolism was assumed and the PFO was closed interventionally with a 25 mm PFO closure device. Exercise capacity remained unchanged after PFO closure.

The two presented cases of paradoxical embolism illustrate that mechanisms of stroke in ACHD patients can be different from those of the general population (e.g., high right atrial pressure in Ebstein's anomaly, large shunt in partial detachment of ASD patch). Considering these mechanisms and the increasing incidence of venous thrombosis with age (11), a higher prevalence of paradoxical embolism in ACHD patients with residual atrial shunts may be suspected and should be investigated in prospective trials.

CONCLUSION

With the increasing number of aging ACHD patients, late sequelae not directly related to the initial congenital heart disease significantly influence their morbidity and mortality. Regular follow-up of patients with ACHD remains important throughout life even in seemingly stable lesions.

DATA AVAILABILITY STATEMENT

The original contributions presented in the study are included in the article/supplementary material, further inquiries can be directed to the corresponding author.

AUTHOR CONTRIBUTIONS

MS: conceptualization and visualization. MS and VD: writing – original draft preparation. HG, VD, FB, BO-R, BP, and L-HB: writing – review and editing. BP, HG, and L-HB: supervision. All authors have read and agreed to the published version of the manuscript.

REFERENCES

- Tutarel O, Kempny A, Alonso-Gonzalez R, Jabbour R, Li W, Uebing A, et al. Congenital heart disease beyond the age of 60: emergence of a new population with high resource utilization, high morbidity, and high mortality. *Eur Heart J*. (2014) 35:725–32. doi: 10.1093/eurheartj/eh257
- Mandalenakis Z, Rosengren A, Lappas G, Eriksson P, Hansson PO, Dellborg M. Ischemic stroke in children and young adults with congenital heart disease. *J Am Heart Assoc*. (2016) 5:e003071. doi: 10.1161/JAHA.115.003071
- Lanz J, Brophy JM, Therrien J, Kaouache M, Guo L, Marelli AJ. Stroke in adults with congenital heart disease: incidence, cumulative risk, and predictors. *Circulation*. (2015) 132:2385–94. doi: 10.1161/CIRCULATIONAHA.115.011241
- Hoffmann A, Chockalingam P, Balint OH, Dadashev A, Dimopoulos K, Engel R, et al. Cerebrovascular accidents in adult patients with congenital heart disease. *Heart*. (2010) 96:1223–6. doi: 10.1136/hrt.2010.196147
- Huntgeburth M, Hohmann C, Ewert P, Freilinger S, Nagdyman N, Neidenbach R, et al. Implantable loop recorder for monitoring patients with congenital heart disease. *Cardiovasc Diagn Ther*. (2021) 11:1334–43. doi: 10.21037/cdt-20-677
- Tsui C, Wan D, Grewal J, Kiess M, Barlow A, Human D, et al. Increasing age and atrial arrhythmias are associated with increased thromboembolic events in a young cohort of adults with repaired tetralogy of Fallot. *J Arrhythm*. (2021) 37:1546–54. doi: 10.1002/joa3.12630
- Sinning C, Zengin E, Blankenberg S, Rickers C, von Kodolitsch Y, Diller G, et al. Anticoagulation management in adult patients with congenital heart disease: a narrative review. *Cardiovasc Diagn Ther*. (2021) 11:1324–33. doi: 10.21037/cdt-20-631
- Søndergaard L, Kasner SE, Rhodes JF, Andersen G, Iversen HK, Nielsen-Kudsk JE, et al. Patent foramen ovale closure or antiplatelet therapy for cryptogenic stroke. *N Engl J Med*. (2017) 377:1033–42.
- Saver JL, Carroll JD, Thaler DE, Smalling RW, MacDonald LA, Marks DS, et al. Long-term outcomes of patent foramen ovale closure or medical therapy after stroke. *N Engl J Med*. (2017) 377:1022–32.
- Mas JL, Derumeaux G, Guillon B, Massardier E, Hosseini H, Mechtouff L, et al. Patent foramen ovale closure or anticoagulation vs. antiplatelets after stroke. *N Engl J Med*. (2017) 377:1011–21. doi: 10.1056/NEJMoa1705915
- Engbers MJ, van Hylckama Vlieg A, Rosendaal FR. Venous thrombosis in the elderly: incidence, risk factors and risk groups. *J Thromb Haemost*. (2010) 8:2105–12. doi: 10.1111/j.1538-7836.2010.03986.x

Conflict of Interest: HG was consultant for ABBOTT Medical and GORE Medical.

The remaining authors declare that the research was conducted in the absence of any commercial or financial relationships that could be construed as a potential conflict of interest.

Publisher's Note: All claims expressed in this article are solely those of the authors and do not necessarily represent those of their affiliated organizations, or those of the publisher, the editors and the reviewers. Any product that may be evaluated in this article, or claim that may be made by its manufacturer, is not guaranteed or endorsed by the publisher.

Copyright © 2022 Schneider, Dannenberg, Opgen-Rhein, Berger, Pieske, Gabriel and Boldt. This is an open-access article distributed under the terms of the Creative Commons Attribution License (CC BY). The use, distribution or reproduction in other forums is permitted, provided the original author(s) and the copyright owner(s) are credited and that the original publication in this journal is cited, in accordance with accepted academic practice. No use, distribution or reproduction is permitted which does not comply with these terms.