



OPEN ACCESS

APPROVED BY
Frontiers in Editorial Office

*CORRESPONDENCE
Frontiers Production Office,
production.office@frontiersin.org

SPECIALTY SECTION
This article was submitted to Tissue
Engineering and Regenerative Medicine,
a section of the journal
Frontiers in Bioengineering and
Biotechnology

RECEIVED 30 September 2022
ACCEPTED 30 September 2022
PUBLISHED 03 November 2022

CITATION
Frontiers Production Office (2022),
Erratum: Tips and tricks and clinical
outcome of cryopreserved human
amniotic membrane application for the
management of medication- related
osteonecrosis of the jaw (MRONJ): A
pilot study.
Front. Bioeng. Biotechnol. 10:1058241.
doi: 10.3389/fbioe.2022.1058241

COPYRIGHT
© 2022 Frontiers Production Office.
This is an open-access article
distributed under the terms of the
[Creative Commons Attribution License
\(CC BY\)](https://creativecommons.org/licenses/by/4.0/). The use, distribution or
reproduction in other forums is
permitted, provided the original
author(s) and the copyright owner(s) are
credited and that the original
publication in this journal is cited, in
accordance with accepted academic
practice. No use, distribution or
reproduction is permitted which does
not comply with these terms.

Erratum: Tips and tricks and clinical outcome of cryopreserved human amniotic membrane application for the management of medication-related osteonecrosis of the jaw (MRONJ): A pilot study

Frontiers Production Office*

KEYWORDS

human amniotic membrane, osteonecrosis, oral mucosa, allograft, bisphosphonates, denosumab, antiangiogenic drugs

An Erratum on

Tips and tricks and clinical outcome of cryopreserved human amniotic membrane application for the management of medication-related osteonecrosis of the Jaw (MRONJ): A pilot study

by Odet S, Meyer C, Gaudet C, Weber E, Quenot J, Derruau S, Laurence S, Bompoy L, Girodon M, Chatelain B, Mauprivez C, Brenet E, Kerdjoudj H, Zwetyenga N, Marchetti P, Hatzfeld A-S, Toubeau D, Pouthier F, Lafarge X, Redl H, Fenelon M, Fricain J-C, Di Pietro R, Ledouble C, Gualdi T, Parmentier A-L, Louvrier A and Gindraux F (2022). *Front. Bioeng. Biotechnol.* 10: 936074. doi: 10.3389/fbioe.2022.936074

Due to a production error, there was a mismatch in [Figures 4D, 5D, 5E](#) as published. The corrected figures appear below.

Additionally, the inactive video link in the **Introduction** section (paragraph 7) has been replaced with the following link: <https://youtu.be/GKy3I-n3NRQ>.

There were two typing errors in the **Figure 3** legend, the correction appears below:

FIGURE 3

Patient 8 (A) hAM application, sutured on a collagen sponge. (B) Three days post-surgery. (C) Ten days post-surgery, with the reepithelialization on more than $\frac{2}{3}$ of the surgical site.

The publisher apologizes for this mistake. The original version of this article has been updated.

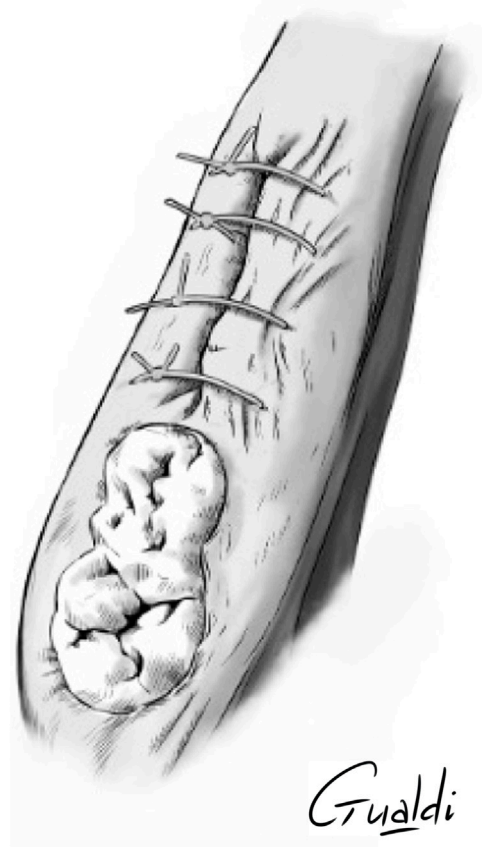


FIGURE 4
 Patient 2 (A) Anterior mandibular stage 2 MRONJ. (B) hAM application. (C) Hermetical sutures from “hAM implantation with complete coverage” nomenclature (Odet et al., 2021). Here the sutures were done above the implanted hAM which was not visible. (D) Upper view and (E) Sagittal section illustrations of “hAM implantation with complete coverage” nomenclature.

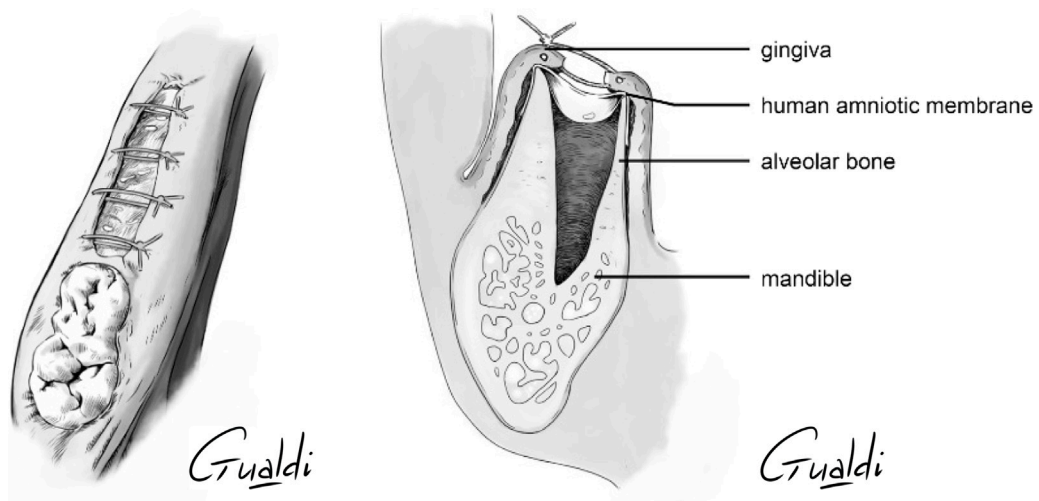


FIGURE 5
 Patient 3 (A) Sector 3 posterior stage 2 MRONJ. (B) hAM application. (C) Non-hermetic sutures from “hAM implantation with partial coverage” nomenclature (Odet et al., 2021). Here the gingiva was sutured above the hAM, but leaving the hAM exposed in the oral cavity. (D) Upper view and (E) Sagittal section illustrations of “hAM implantation with partial coverage” nomenclature.

Publisher's note

All claims expressed in this article are solely those of the authors and do not necessarily represent those of their affiliated

organizations, or those of the publisher, the editors and the reviewers. Any product that may be evaluated in this article, or claim that may be made by its manufacturer, is not guaranteed or endorsed by the publisher.