



Voxel-Based Morphometry of Cerebellar Lobules in Essential Tremor

Richard Ågren^{1*}, Amar Awad^{2,3,4}, Patric Blomstedt² and Anders Fytagoridis⁵

¹ Department of Neuroscience, Karolinska Institutet, Stockholm, Sweden, ² Unit of Functional and Stereotactic Neurosurgery, Department of Pharmacology and Clinical Neuroscience, Umeå University, Umeå, Sweden, ³ Physiology Section, Department of Integrative Medical Biology, Umeå University, Umeå, Sweden, ⁴ Umeå Center for Functional Brain Imaging (UFB), Umeå University, Umeå, Sweden, ⁵ Department of Clinical Neuroscience, Karolinska Institutet, Stockholm, Sweden

Background: The extent of neurodegeneration underlying essential tremor (ET) remains a matter of debate. Despite various extents of cerebellar atrophy on structural magnetic resonance imaging (MRI), previous studies have shown substantial heterogeneity and included a limited number of patients. Novel automated pipelines allow detailed segmentation of cerebellar lobules based on structural MRI.

Objective: To compare the volumes of cerebellar lobules in ET patients with those in healthy controls (HCs) using an automated segmentation pipeline.

Methods: Structural MRI scans of ET patients eligible for deep brain stimulation ($n = 55$) and of age-matched and gender-matched HCs ($n = 55$, from the IXI database) were segmented using the automated CEREBellum Segmentation pipeline. Lobule-specific volume differences between the ET and HC groups were evaluated using a general linear model corrected for multiple tests.

Results: Total brain tissue volumes did not differ between the ET and HC groups. ET patients demonstrated reduced volumes of lobules I-II, left Crus II, left VIIIB, and an increased volume of right X when compared with the HC group.

Conclusion: A large cohort of ET patients demonstrated subtle signs of decreased cerebellar lobule volumes. These findings oppose the hypothesis of localized atrophy in cerebellar motor areas in ET, but not the possibility of cerebellar pathophysiology in ET. Prospective investigations using alternative neuroimaging modalities may further elucidate the pathophysiology of ET and provide insights into diagnostic and therapeutic approaches.

Keywords: essential tremor, cerebellum, voxel-based morphometry, lobule volume, structural MRI

INTRODUCTION

Essential tremor (ET) is the most prevalent movement disorder, affecting approximately 4% of the population over 40 years of age (Zesiewicz et al., 2010). Although it was initially believed to be a benign motor disorder, reports have demonstrated increased occurrences of mood disorders, cognitive disorders, and early mortality in ET patients (Benito-Leon et al., 2006;

OPEN ACCESS

Edited by:

Fernín Segovia,
University of Granada, Spain

Reviewed by:

Rachel Paes Guimarães,
State University of Campinas, Brazil
Brunno Machado De Campos,
State University of Campinas, Brazil

*Correspondence:

Richard Ågren
richard.agren@ki.se

Received: 14 February 2021

Accepted: 03 May 2021

Published: 10 June 2021

Citation:

Ågren R, Awad A, Blomstedt P
and Fytagoridis A (2021) Voxel-Based
Morphometry of Cerebellar Lobules
in Essential Tremor.
Front. Aging Neurosci. 13:667854.
doi: 10.3389/fnagi.2021.667854

Louis et al., 2007a,b). A neurodegenerative origin of ET has been proposed based on neuropathological analyses of ET patients showing cerebellar pathology (Rajput et al., 2012; Benito-León, 2014). Mechanistically, a cerebello-thalamo-cortical network dysfunction has been suggested to cause tremor in ET (Hallett, 2014; Buijink et al., 2015) and lesions or deep brain stimulation (DBS) in this pathway may suppress tremor (Dupuis et al., 2010; Fytogoridis et al., 2012; Elias et al., 2016; Barbe et al., 2018).

Structural magnetic resonance imaging (MRI), which allows for voxel-based morphometric (VBM) analysis, has demonstrated diverse cortical and cerebellar volumetric changes in ET patients. Decreased cerebellar gray matter has been observed in groups of ET patients (Benito-Leon et al., 2009; Bhalsing et al., 2014; Gallea et al., 2015; Dyke et al., 2017). However, other studies have reported no differences (Daniels et al., 2006; Fang et al., 2013; Nicoletti et al., 2015) and abnormalities in white matter (Pietracupa et al., 2019). A recent meta-analysis of 16 structural MRI investigations proposed that previously reported gray matter abnormalities in ET might be related to methodological heterogeneity and small or diverse cohorts, thereby indicating the need for larger studies using standardized protocols (Luo et al., 2019).

In the present study, cerebellar volumes of 55 ET patients eligible for DBS (Fytogoridis et al., 2012) were compared with those of matched healthy controls (HCs) from the IXI repository. We aimed to test the hypothesis of regional atrophy in the cerebellar motor areas of ET patients using an automated segmentation pipeline (Romero et al., 2017).

METHODS

Patient and Control Selection

Patients diagnosed with ET ($n = 70$) who underwent T1-weighted MRI before DBS between 2006 and 2015 at Umeå University Hospital, Sweden were included. The exclusion criteria were the use of alternative MRI protocols ($n = 13$), previous DBS electrode implantation ($n = 1$), or major brain lesions ($n = 1$). T1-weighted MRI scans of HCs ($n = 55$) were retrieved from the IXI repository, which included volunteers from three UK hospitals (<https://brain-development.org/ixi-dataset/>). Subject characteristics (age and sex) and MRI data were collected. To reduce the technical

bias introduced by different scanners and sites, volumes were normalized to total brain tissue, which did not differ significantly between the HC and ET groups (**Table 1** and **Supplementary Figure 1**).

MRI Imaging Procedure

ET patients underwent imaging at Umeå University Hospital, Umeå, Sweden. T1-weighted sequences were acquired using the NT Intera 1.5T MRI scanner (Philips, Amsterdam, Netherlands) with repetition time = 25 ms, echo time = 5.5 ms, number of phase encoding steps = 256, echo train length = 1, reconstruction diameter = 260 mm, and flip angle = 25°. The HC group underwent imaging at Guy's Hospital, UK with a 1.5T scanner (Philips, Amsterdam, Netherlands) with repetition time = 9.813 ms, echo time = 4.603 ms, number of phase encoding steps = 192, echo train length = 0, reconstruction diameter = 240 mm, and flip angle = 8° (<https://brain-development.org/ixi-dataset/>).

Volumetric Analysis

T1-weighted MRI images in DICOM format were anonymized and converted to the NIFTI format using dcm2niix (Li et al., 2016). Cerebellar lobule volumes were determined using the CEREBellum Segmentation (CERES) pipeline, which is a patch-based multi-atlas segmentation pipeline that parcellates the cerebellum into 12 lobules and determines the respective volumes in the native space (Romero et al., 2017). CERES has been demonstrated to outperform several cerebellar pipelines in terms of segmentation accuracy (Romero et al., 2017). Total lobule volumes including both white and gray matter were extracted from the results. The anatomical segmentations in CERES are shown in **Figure 1**. Total brain volumes were determined by analyzing the T1-weighted sequences using the volBrain pipeline (Manjón and Coupé, 2016).

Statistical Analysis

Baseline characteristics (age and brain volume) were compared using Student's *t*-test. Cerebellar regions were compared between the ET and HC groups using a multivariate general linear model with age and total brain volume as covariates. The significance level was adjusted for multiple testing using the Benjamini-Hochberg method (Benjamini and Hochberg, 1995). Statistical analysis was performed using IBM SPSS Statistics version 26 (IBM Corp., Armonk, NY, United States) and GraphPad Prism 8 (GraphPad Software, San Diego, CA, United States).

RESULTS

The ET patients were matched with HCs from the IXI repository based on age and sex (**Table 1**). The images were matched based on the MRI scanner type and magnetic field strength. Total brain volumes determined using volBrain (Manjón and Coupé, 2016) did not differ significantly between the HC and ET groups ($p = 0.2403$, **Table 1** and **Supplementary Figure 1**). Cerebellar lobules were segmented and volumetrically quantified using CERES (Romero et al., 2017) and analyzed using a multivariate general linear model with gender, age, and total brain volume as

TABLE 1 | Subject characteristics and total brain volumes from volBrain.

Group	HC	ET	
Database, country	IXI repository, United Kingdom	Umeå University Hospital, Sweden	
N	55	55	
Male/Female	27/28	29/26	
Age (years)	67.0 (8.4)	67.3 (8.3)	$p = 0.8372$
Total brain (cm ³)	1130 (118)	1158 (129)	$p = 0.2403$

Data are shown as means (SD). Groups were compared using *t*-tests.

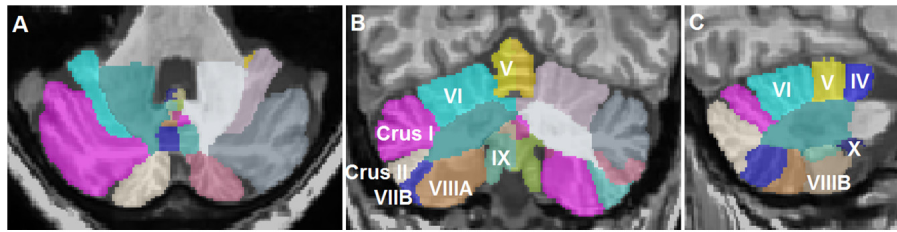


FIGURE 1 | Representative segmentation of a T1-weighted magnetic resonance imaging scan of a patient with essential tremor using the CEREBellum Segmentation pipeline (Romero et al., 2017). **(A)** Axial, **(B)** coronal, and **(C)** sagittal representations of the segmented lobules.

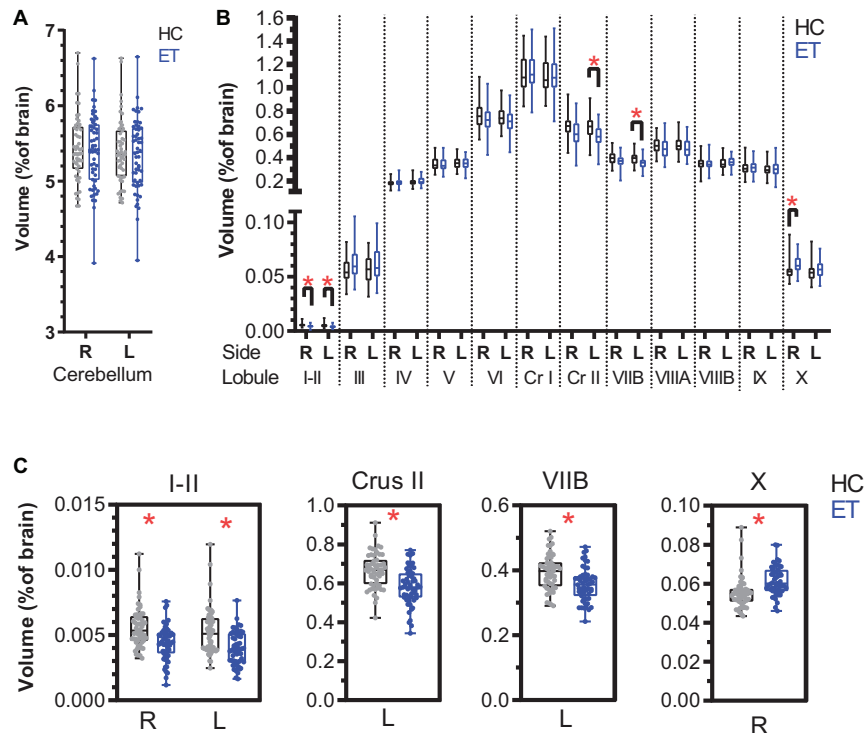


FIGURE 2 | Normalized cerebellar lobule volumes in patients with essential tremor (ET) and in healthy controls (HCs) expressed as percentage of total brain volume. **(A)** Right and left cerebellar lobule volumes for the HC (black) and ET (blue) groups. **(B)** Lobule volumes for the right and left cerebellar hemispheres. **(C)** Lobules with significant volume differences between the HC and ET groups: bilateral I-II, left Crus II, left VII B, and right X (Table 2). The boxplots show the 25th, 50th, and 75th percentiles for all data. A multivariate general linear model was applied to the cerebellum and the 12 lobules (right and left sides) with gender, age, and total brain volume as covariates. The significance level ($p < 0.05$) was adjusted for multiple testing using the Benjamini-Hochberg method. Significance is denoted by *. R: right, L: left, Cr I: Crus I, Cr II: Crus II.

covariates. Total cerebellar volumes did not differ (right: $p = 0.874$ and left: $p = 0.995$, Figure 2A) between the groups, while volumes of lobules I-II (right: $p < 0.001$ and left: $p < 0.001$), left Crus II ($p < 0.001$), and left VII B ($p < 0.001$) were lower in the ET group than in the HC group (Figures 2B,C and Table 2). The right lobule X was larger in the ET group ($p < 0.001$).

DISCUSSION

Structural MRI-derived cerebellar volumes of a large sample of ET patients eligible for DBS were compared with those

of matched HCs. Among ET patients, subtle volume reductions were observed in bilateral lobules I-II, left Crus II, and left VII B. The volume of the right lobule X was increased.

The observations from the present study are partly concordant with those of previous studies. A lobule-based analysis demonstrated reduced gray matter volumes of VI and VII A in a pooled cohort of 39 patients with cerebellar and classic ET (Shin et al., 2016). Another study used the spatially unbiased infratentorial segmentation pipeline and reported reduced gray matter densities in the left lobules I-IV, V, VII B, VII A, IX, and X; right lobules V and IX; and in vermal regions in a subgroup of ET

TABLE 2 | Volumes of cerebellar lobules I–X in healthy controls (HCs) and in patients with essential tremor (ET) normalized to total brain tissue (reported as percentage).

Volume	Side	HC (N=55)		ET (N=55)	
		Average (%)	SD	Average (%)	SD
Cerebellum	R	5,435	0,439	5,398	0,479
	L	5,397	0,422	5,347	0,480
I-II	R	0,006*	0,002	0,004*	0,001
	L	0,005*	0,002	0,004*	0,001
III	R	0,058	0,011	0,062	0,013
	L	0,057	0,012	0,062	0,015
IV	R	0,183	0,027	0,189	0,034
	L	0,191	0,030	0,200	0,036
V	R	0,343	0,054	0,344	0,054
	L	0,353	0,052	0,350	0,050
VI	R	0,769	0,116	0,737	0,114
	L	0,750	0,088	0,719	0,100
Crus I	R	1,125	0,156	1,131	0,141
	L	1,101	0,151	1,107	0,157
Crus II	R	0,677	0,097	0,612	0,107
	L	0,666*	0,089	0,583*	0,095
VIIB	R	0,394	0,056	0,373	0,054
	L	0,394*	0,054	0,356*	0,051
VIII A	R	0,508	0,066	0,479	0,088
	L	0,514	0,070	0,485	0,082
VIII B	R	0,351	0,050	0,345	0,047
	L	0,350	0,052	0,359	0,045
IX	R	0,313	0,060	0,315	0,059
	L	0,302	0,059	0,301	0,065
X	R	0,055*	0,008	0,062*	0,007
	L	0,054	0,008	0,057	0,008

A multivariate general linear model was applied to the cerebellum and the 12 lobules (right and left sides) with gender, age, and total brain volume as covariates. The significance level $p < 0.05$ was adjusted for multiple testing using the Benjamini-Hochberg method. Significance denoted by * (bold). R: right and L: left.

patients with head or jaw tremor (Dyke et al., 2017). Laterality of volumetric changes has been reported in cerebellar gray matter volume (Quattrone et al., 2008). The reduced volumes of Crus II and VIIB in the left cerebellum may be related to technical or biological aspects, which varied between the ET and HC cohorts. Handedness is an example of the latter, although the implications on cerebellar gray matter volumes remain questioned (Ocklenburg et al., 2016).

Interestingly, our results did not show pronounced volumetric reductions within the first (I–VI) and second (VIII A–VIII B) cerebellar motor representations (Buckner et al., 2011; Guell et al., 2018) among ET patients. Instead, the findings are consistent with a recent meta-analysis that challenged the hypothesis of distinct structural cerebellar atrophy patterns in ET and indicated that study size and heterogeneity might explain the diverse VBM findings reported previously (Luo et al., 2019). An alternative explanation for the reduced volumes in the present investigation might be the difference in MRI sites and scanner protocols, which

influence the absolute volumetric measurements (Shinohara et al., 2017).

Histopathological examinations of ET patients demonstrated features suggesting neurodegeneration such as altered axon morphology and orientation of Purkinje cell bodies, reduced cell densities, and loss of dendritic spines (Louis, 2016). However, such changes may not necessarily cause volumetric differences observable on structural imaging. A recent resting-state functional MRI (fMRI) investigation indicated reduced cerebellar connectivity in ET, characterized by eigenvector centrality (Mueller et al., 2017). Additionally, evidence regarding the cerebellar involvement in ET has been obtained from fMRI investigations of ET patients wherein DBS affected cerebello-cerebral networks in task-dependent as well as task-independent manners (Awad et al., 2019). In addition, diffusion tensor imaging of patients with ET and Parkinson’s disease demonstrated increased radial diffusivity in the superior, medial, and inferior cerebellar peduncles in ET, suggesting white matter involvement (Juttukonda et al., 2018).

The present study is limited by the use of MRI data from different sources, retrieved over a long period (2006–2015). However, similar comparisons using MRI scans from the IXI repository have previously been applied to case series (Corral-Juan et al., 2018). To reduce the technical interference introduced by different T1-weighted MRI parameters, volumes were normalized to total brain tissue, which did not differ significantly between the HC and ET groups. Although the CERES and volBrain pipelines are fully automated, differential segmentations based on MRI scan parameters and image quality may affect the results (Manjón and Coupé, 2016; Romero et al., 2017). The present study did not perform corrections for disease severity, ET subtype, hand dominance, and relevant comorbidities such as vascular disease and alcohol consumption. Patient selection was based on ET severity and only the patients eligible for DBS were included, although some previous studies have supported (Bagepally et al., 2012) and others have opposed (Quattrone et al., 2008) a relationship between disease severity and structural gray matter changes.

CONCLUSION

A cohort of 55 patients with ET demonstrated subtle signs of a decrease in cerebellar lobule volumes. These findings do not support the hypothesis of localized atrophy in the cerebellar motor areas in ET. Prospective investigations using structural or functional neuroimaging are needed to confirm these findings and to further elucidate the pathophysiology of ET to provide insights into diagnostic and therapeutic approaches.

DATA AVAILABILITY STATEMENT

The raw data supporting the conclusions of this article will be made available by the authors, without undue reservation, to any qualified researcher.

ETHICS STATEMENT

The studies involving human participants were reviewed and approved by the Umeå Regional Ethical Review Board, Umeå, Sweden. Written informed consent for participation was not required for this study in accordance with the national legislation and the institutional requirements.

AUTHOR CONTRIBUTIONS

RÅ, AA, and AF conceived and planned the study. PB provided the data. RÅ and AA performed the data analysis. PB and AF interpreted the data. RÅ prepared

the manuscript with support from AA, PB, and AF. AF supervised the study. All authors approved the final manuscript.

SUPPLEMENTARY MATERIAL

The Supplementary Material for this article can be found online at: <https://www.frontiersin.org/articles/10.3389/fnagi.2021.667854/full#supplementary-material>

Supplementary Figure 1 | Violin plots of total brain volumes for healthy controls (HC) and patients with essential tremor (ET), determined using the volBrain pipeline (Manjón and Coupé, 2016). The bars represent medians and the 25th and 75th percentiles. The average values and statistics are presented in **Table 1**.

REFERENCES

- Awad, A., Blomstedt, P., Westling, G., and Eriksson, J. (2019). Deep brain stimulation in the caudal zona incerta modulates the sensorimotor cerebello-cerebral circuit in essential tremor. *Neuroimage* 209:116511. doi: 10.1016/j.neuroimage.2019.116511
- Bagepally, B. S., Bhatt, M. D., Chandran, V., Saini, J., Bharath, R. D., Vasudev, M. K., et al. (2012). Decrease in cerebral and cerebellar gray matter in essential tremor: a Voxel-Based Morphometric analysis under 3T MRI. *J. Neuroimag.* 22, 275–278. doi: 10.1111/j.1552-6569.2011.00598.x
- Barbe, M. T., Reker, P., Hamacher, S., Franklin, J., Kraus, D., Dembek, T. A., et al. (2018). DBS of the PSA and the VIM in essential tremor. *Neurology* 91:e543. doi: 10.1212/WNL.00000000000005956
- Benito-León, J. (2014). Essential tremor: a neurodegenerative disease? *Tremor Other Hyperkinet. Mov. (N.Y.)* 4:252. doi: 10.7916/D8765CG0
- Benito-Leon, J., Alvarez-Linera, J., Hernandez-Tamames, J. A., Alonso-Navarro, H., Jimenez-Jimenez, F. J., and Louis, E. D. (2009). Brain structural changes in essential tremor: voxel-based morphometry at 3-Tesla. *J. Neurol. Sci.* 287, 138–142. doi: 10.1016/j.jns.2009.08.037
- Benito-Leon, J., Louis, E. D., Bermejo-Pareja, F., and Neurological Disorders in Central Spain Study Group. (2006). Population-based case-control study of cognitive function in essential tremor. *Neurology* 66, 69–74. doi: 10.1212/01.wnl.0000192393.05850.ec
- Benjamini, Y., and Hochberg, Y. (1995). Controlling the false discovery rate: a practical and powerful approach to multiple testing. *J. R. Stat. Soc. Series B* 57, 289–300. doi: 10.1111/j.2517-6161.1995.tb02031.x
- Bhalsing, K. S., Upadhyay, N., Kumar, K. J., Saini, J., Yadav, R., Gupta, A. K., et al. (2014). Association between cortical volume loss and cognitive impairments in essential tremor. *Eur. J. Neurol.* 21, 874–883. doi: 10.1111/ene.12399
- Buckner, R. L., Krienen, F. M., Castellanos, A., Diaz, J. C., and Yeo, B. T. (2011). The organization of the human cerebellum estimated by intrinsic functional connectivity. *J. Neurophysiol.* 106, 2322–2345. doi: 10.1152/jn.00339.2011
- Buijink, A. W., van der Stouwe, A. M., Broersma, M., Sharifi, S., Groot, P. F., Speelman, J. D., et al. (2015). Motor network disruption in essential tremor: a functional and effective connectivity study. *Brain* 138, 2934–2947. doi: 10.1093/brain/awv225
- Corral-Juan, M., Serrano-Munuera, C., Rábano, A., Cota-González, D., Segarra-Roca, A., Isperto, L., et al. (2018). Clinical, genetic and neuropathological characterization of spinocerebellar ataxia type 37. *Brain* 141, 1981–1997. doi: 10.1093/brain/awy137
- Daniels, C., Peller, M., Wolff, S., Alfke, K., Witt, K., Gaser, C., et al. (2006). Voxel-based morphometry shows no decreases in cerebellar gray matter volume in essential tremor. *Neurology* 67:1452. doi: 10.1212/01.wnl.0000240130.94408.99
- Dupuis, M. J. M., Evrard, F. L. A., Jacquerye, P. G., Picard, G. R., and Lermen, O. G. (2010). Disappearance of essential tremor after stroke. *Movement Disord.* 25, 2884–2887. doi: 10.1002/mds.23328
- Dyke, J. P., Cameron, E., Hernandez, N., Dydak, U., and Louis, E. D. (2017). Gray matter density loss in essential tremor: a lobule by lobule analysis of the cerebellum. *Cerebellum Ataxias* 4:10. doi: 10.1186/s40673-017-0069-3
- Elias, W. J., Lipsman, N., Ondo, W. G., Ghanouni, P., Kim, Y. G., Lee, W., et al. (2016). A randomized trial of focused ultrasound thalamotomy for essential tremor. *N. Engl. J. Med.* 375, 730–739. doi: 10.1056/NEJMoa1600159
- Fang, W., Lv, F., Luo, T., Cheng, O., Liao, W., Sheng, K., et al. (2013). Abnormal regional homogeneity in patients with essential tremor revealed by resting-state functional MRI. *PLoS One* 8:e69199. doi: 10.1371/journal.pone.0069199
- Fyttagoridis, A., Sandvik, U., Aström, M., Bergenheim, T., and Blomstedt, P. (2012). Long term follow-up of deep brain stimulation of the caudal zona incerta for essential tremor. *J. Neurol. Neurosurg. Psychiatry* 83, 258–262. doi: 10.1136/jnnp-2011-300765
- Gallea, C., Popa, T., García-Lorenzo, D., Valabregue, R., Legrand, A.-P., Marais, L., et al. (2015). Intrinsic signature of essential tremor in the cerebello-frontal network. *Brain* 138, 2920–2933. doi: 10.1093/brain/awv171
- Guell, X., Gabrieli, J. D. E., and Schmahmann, J. D. (2018). Triple representation of language, working memory, social and emotion processing in the cerebellum: convergent evidence from task and seed-based resting-state fMRI analyses in a single large cohort. *Neuroimage* 172, 437–449. doi: 10.1016/j.neuroimage.2018.01.082
- Hallett, M. (2014). Tremor: Pathophysiology. *Parkinsonism Relat. Disord.* 20, S118–S122. doi: 10.1016/S1353-8020(13)70029-4
- Juttukonda, M. R., Franco, G., Englot, D. J., Lin, Y.-C., Petersen, K. J., Trujillo, P., et al. (2018). White matter differences between essential tremor and Parkinson disease. *Neurology* 92, e30–e39. doi: 10.1212/WNL.0000000000006694
- Li, X., Morgan, P. S., Ashburner, J., Smith, J., and Rorden, C. (2016). The first step for neuroimaging data analysis: DICOM to NIFTI conversion. *J. Neurosci. Methods* 264, 47–56. doi: 10.1016/j.jneumeth.2016.03.001
- Louis, E. D. (2016). Essential tremor: a common disorder of purkinje neurons? *Neuroscientist* 22, 108–118. doi: 10.1177/1073858415590351
- Louis, E. D., Benito-Leon, J., Bermejo-Pareja, F., and Neurological Disorders in Central Spain Study Group. (2007). Self-reported depression and antidepressant medication use in essential tremor: cross-sectional and prospective analyses in a population-based study. *Eur. J. Neurol.* 14, 1138–1146. doi: 10.1111/j.1468-1331.2007.01923.x
- Louis, E. D., Benito-Leon, J., Ottman, R., Bermejo-Pareja, F., and Neurological Disorders in Central Spain Study Group. (2007). A population-based study of mortality in essential tremor. *Neurology* 69, 1982–1989. doi: 10.1212/01.wnl.0000279339.87987.d7
- Luo, R., Pan, P., Xu, Y., and Chen, L. (2019). No reliable gray matter changes in essential tremor. *Neurol. Sci.* 40, 2051–2063. doi: 10.1007/s10072-019-03933-0
- Manjón, J. V., and Coupé, P. (2016). volBrain: an online MRI Brain volumetry system. *Front. Neuroinform.* 10:30. doi: 10.3389/fninf.2016.00030
- Mueller, K., Jech, R., Hoskocová, M., Ulmanová, O., Urgošik, D., Vymazal, J., et al. (2017). General and selective brain connectivity alterations in essential tremor: A resting state fMRI study. *Neuroimage Clin.* 16, 468–476. doi: 10.1016/j.nicl.2017.06.004

- Nicoletti, V., Cecchi, P., Frosini, D., Pesaresi, I., Fabbri, S., Diciotti, S., et al. (2015). Morphometric and functional MRI changes in essential tremor with and without resting tremor. *J. Neurol.* 262, 719–728. doi: 10.1007/s00415-014-7626-y
- Ocklenburg, S., Friedrich, P., Güntürkün, O., and Genç, E. (2016). Voxel-wise grey matter asymmetry analysis in left- and right-handers. *Neurosci. Lett.* 633, 210–214. doi: 10.1016/j.neulet.2016.09.046
- Pietracupa, S., Bologna, M., Bharti, K., Pasqua, G., Tommasin, S., Elifani, F., et al. (2019). White matter rather than gray matter damage characterizes essential tremor. *Eur. Radiol.* 29, 6634–6642. doi: 10.1007/s00330-019-06267-9
- Quattrone, A., Cerasa, A., Messina, D., Nicoletti, G., Hagberg, G. E., Lemieux, L., et al. (2008). Essential head tremor is associated with cerebellar vermis atrophy: a volumetric and Voxel-Based Morphometry MR Imaging Study. *Am. J. Neuroradiol.* 29:1692. doi: 10.3174/ajnr.A1190
- Rajput, A. H., Adler, C. H., Shill, H. A., and Rajput, A. (2012). Essential tremor is not a neurodegenerative disease. *Neurodegenerative Dis. Manage.* 2, 259–268. doi: 10.2217/nmt.12.23
- Romero, J. E., Coupé, P., Giraud, R., Ta, V.-T., Fonov, V., Park, M. T. M., et al. (2017). CERES: a new cerebellum lobule segmentation method. *NeuroImage* 147, 916–924. doi: 10.1016/j.neuroimage.2016.11.003
- Shin, H., Lee, D.-K., Lee, J.-M., Huh, Y.-E., Youn, J., Louis, E. D., et al. (2016). Atrophy of the cerebellar vermis in essential tremor: segmental volumetric MRI analysis. *Cerebellum* 15, 174–181. doi: 10.1007/s12311-015-0682-8
- Shinohara, R. T., Oh, J., Nair, G., Calabresi, P. A., Davatzikos, C., Doshi, J., et al. (2017). Volumetric analysis from a harmonized multisite brain MRI study of a single subject with multiple sclerosis. *AJNR Am. J. Neuroradiol.* 38, 1501–1509. doi: 10.3174/ajnr.A5254
- Zesiewicz, T. A., Chari, A., Jahan, I., Miller, A. M., and Sullivan, K. L. (2010). Overview of essential tremor. *Neuropsychiat. Dis. Treatment* 6, 401–408. doi: 10.2147/ndt.s4795

Conflict of Interest: PB is a consultant for Abbott, Medtronic, and Boston Scientific. He is a shareholder in Mithridaticum AB.

The remaining authors declare that the research was conducted in the absence of any commercial or financial relationships that could be construed as a potential conflict of interest.

Copyright © 2021 Ågren, Awad, Blomstedt and Fytagoridis. This is an open-access article distributed under the terms of the Creative Commons Attribution License (CC BY). The use, distribution or reproduction in other forums is permitted, provided the original author(s) and the copyright owner(s) are credited and that the original publication in this journal is cited, in accordance with accepted academic practice. No use, distribution or reproduction is permitted which does not comply with these terms.