



# Recombinant Human Nerve Growth Factor (Cenegermin)–Driven Corneal Wound Healing Process: An Evidence-Based Analysis

Chiara Bonzano<sup>1,2\*</sup>, Sara Olivari<sup>1,2</sup>, Carlo Alberto Cutolo<sup>1,2</sup>, Angelo Macri<sup>2</sup>, Daniele Sindaco<sup>1,2</sup>, Davide Borroni<sup>3</sup>, Elisabetta Bonzano<sup>4,5</sup> and Carlo Enrico Traverso<sup>1,2</sup>

<sup>1</sup>Eye Clinic, Department of Neuroscience, Rehabilitation, Ophthalmology, Genetics, Maternal and Child Health, University of Genoa, Genoa, Italy, <sup>2</sup>IRCCS San Martino Polyclinic Hospital, Genoa, Italy, <sup>3</sup>Cornea Unit, Royal Liverpool University Hospital, Liverpool, United Kingdom, <sup>4</sup>Department of Radiation Oncology, IRCCS San Matteo Polyclinic Foundation, Pavia, Italy, <sup>5</sup>PhD School in Experimental Medicine, University of Pavia, Pavia, Italy

## OPEN ACCESS

### Edited by:

Mario Damiano Toro,  
Medical University of Lublin, Poland

### Reviewed by:

Bijorn Omar Balzamino,  
GB Bietti Foundation (IRCCS), Italy  
Ignacio Alcalde,  
Instituto Universitario Fernández-  
Vega, Spain

### \*Correspondence:

Chiara Bonzano  
oculistabonzano@gmail.com

### Specialty section:

This article was submitted to  
Experimental Pharmacology and Drug  
Discovery,  
a section of the journal  
Frontiers in Pharmacology

**Received:** 18 August 2021

**Accepted:** 13 December 2021

**Published:** 28 January 2022

### Citation:

Bonzano C, Olivari S, Cutolo CA,  
Macri A, Sindaco D, Borroni D,  
Bonzano E and Traverso CE (2022)  
Recombinant Human Nerve Growth  
Factor (Cenegermin)–Driven Corneal  
Wound Healing Process: An Evidence-  
Based Analysis.  
*Front. Pharmacol.* 12:760507.  
doi: 10.3389/fphar.2021.760507

**Purpose:** To evaluate anterior segment optical coherence tomography (AS-OCT) to detect the wound healing process as per monitoring the effectiveness of cenegermin to treat moderate to severe neurotrophic keratoplasty.

**Methods:** A retrospective chart review was realized to identify patients treated with cenegermin at the Clinica Oculistica, University of Genoa, Italy. All patients underwent careful examinations at baseline and follow-up visits. AS-OCT scans centered on the minimum corneal thickness (CT) area were always performed. We compared findings of AS-OCT with the findings from the slit-lamp examination. A linear regression analysis was used to evaluate factors associated with corneal healing. A further analysis, including a control group treated with 50% autologous serum (AS), was done to investigate and compare the efficacy of cenegermin.

**Results:** Data from 16 eyes were studied. The average patients' age was  $60.9 \pm 21.1$  years; five (31.2%) eyes experienced persistent epithelial defect and 11 (68.8%) eyes had neurotrophic corneal ulcer. The average reepithelialization time was  $3.9 \pm 0.5$  weeks in the cenegermin group versus  $5.9 \pm 1.9$  weeks in the AS group ( $p < 0.01$ ). The AS-OCT scans revealed an average CT at the thinnest point of  $276.3 \pm 74.1 \mu\text{m}$  before treatment with an average increase of  $176.5 \pm 60.3 \mu\text{m}$  at the end of the cenegermin treatment ( $B = -0.15$ ;  $p = 0.035$ ). The AS-OCT percentage increase in corneal thickness between the two groups was statistically significant ( $p < 0.02$ ).

**Conclusion:** Understanding the cascade of events involved in the nerve growth factor–driven corneal wound healing process is clinically meaningful for the clinician. AS-OCT is an effective tool for systematic anterior segment imaging, allowing the detailed detection of the front-to-back layered corneal structure for quantitative analysis and monitoring of the healing process.

**Keywords:** cenegermin, neurotrophic keratoplasty, corneal diseases, ocular pharmacology, pharmacological targets, anterior segment optical coherence tomography (AS-OCT), rh-NGF, autologous serum

## INTRODUCTION

Several ocular and systemic diseases have been associated with damage to the fifth cranial nerve axons, from the trigeminal nucleus to the corneal nerve endings, possibly resulting in the development of neurotrophic keratoplasty (NK) (Dua et al., 2018).

Among the multitude of causes of NK, herpetic keratoplasty (herpes simplex and herpes zoster viral infection) are the most common, followed by intracranial space-occupying lesions or neurosurgical procedures that damage the trigeminal ophthalmic branch (Sacchetti and Lambiase, 2014).

Other ocular causes of NK include chemical burns, physical injuries, corneal dystrophy, chronic use of topical medications (topical anesthetics, timolol, betaxolol, sulfacetamide, and diclofenac sodium), and anterior-segment surgery involving nerve damage (Semeraro et al., 2014). Additional systemic conditions associated with corneal nerve impairment are diabetes mellitus (DM), multiple sclerosis, congenital syndromes, and leprosy (Sacchetti and Lambiase, 2014).

Corneal blindness is the fourth leading cause of blindness worldwide (Jeng and Ahmad, 2021); however, nearly 80% of all cases are avoidable and reversible (Jeng and Ahmad, 2021). Thus, treating corneal diseases such as trauma or keratoplasty represents an urgent or emergent care issue for ophthalmologists. For these reasons, more evidence on new and recent drugs for conservative treatment is highly required, especially in such a crucial time where there is a restriction regarding access to surgical corneal treatments (Toro et al., 2020).

Cenegermin is a novel recombinant human nerve growth factor (rh-NGF) recently approved to treat moderate to severe NK (European Medicines Agency, 2021). Cenegermin eye drop proved to be safe and successful in regenerating corneal integrity in two phase-II clinical trials (Bonini et al., 2018a; Bonini et al., 2018b). The understanding of the cascade of events involved in the NGF-driven corneal wound healing process and the evaluation of how corneal wound healing affects corneal biomechanics and optics are crucial to improving the outcome of the treatment.

Anterior segment optical coherence tomography (AS-OCT) is a noninvasive instrument for systematic anterior segment imaging, allowing the detection of the front-to-back layered corneal structure with sufficient detail to make a quantitative analysis. There have been reports on the assessment of corneal thickness (CT) (Muscat et al., 2002; Ishibazawa et al., 2011); AS-OCT also contributes to the diagnosis of anterior eye diseases, monitoring of pathological conditions, and their healing process (Nubile et al., 2011; Mastropasqua et al., 2017; Venkateswaran et al., 2018; Kowalczyk et al., 2020). OCT technology is also widely used for posterior segment imaging; several studies have shown its effectiveness in disease monitoring with good intra-session reproducibility even in case of corneal pathologies (Reibaldi et al., 2012), as well as in detecting the onset of possible treatment-related complications (Ceravolo et al., 2020; Arumuganathan et al., 2021). Furthermore, it is commonly used as a screening tool for not only ocular diseases but also systemic diseases (Chisari et al., 2019; Carnevali et al., 2021; Koman-Wierdak et al., 2021; Wiest

et al., 2021; Zweifel et al., 2021). Recently, AS-OCT has been introduced as a valid tool to optimize the classification of Stage 3 NK (Mastropasqua et al., 2019). The use of AS-OCT for the corneal morphological analysis in patients treated with cenegermin has yet to be described. Our study aims to evaluate AS-OCT to detect the wound healing process as per monitoring the efficacy of cenegermin. A further analysis, including a control group, was performed to investigate and compare the efficacy of cenegermin.

## MATERIALS AND METHODS

A retrospective chart review was performed to identify patients treated with topical cenegermin eye drops at the Clinica Oculistica, University of Genova, Italy. To evaluate the ability of AS-OCT in detecting the wound healing process as per monitoring the efficacy of cenegermin, the AS-OCT data were compared with an historical control group of patients affected by NK who received standard conventional treatment, 50% autologous serum (AS) eye drops, since 2018 at the same institution.

### Patients Inclusion and Exclusion Criteria

The inclusion criteria were unilateral Stage 2 or 3 NK refractory to one or more conventional treatments for at least 2 weeks, evidence of decreased corneal sensitivity, and the presence of negative corneal cultures, which were taken at admission to our department before the treatment. Finally, only patients with at least 12 months of follow-up after treatment were included.

The diagnosis of NK was established using the Mackie classification: Stage 2 [persistent epithelial defect (PED)] or Stage 3 [neurotrophic corneal ulcer (NCU)]. According to Mastropasqua et al., 2019, the Stage 3 enclosed Stage 3A (corneal ulceration with stromal thinning  $\leq 50\%$  of the total CT) and Stage 3B (corneal ulceration with stromal thinning  $\geq 50\%$  of the total CT). During the treatment period with cenegermin, therapeutic contact lens application and additional topical treatments were discontinued. In addition, possible impending perforation or surgical management needs, and active ocular infection or inflammation unrelated to NK were considered as the exclusion criteria, as were pregnancy and breastfeeding. The same eligibility criteria were applied to enclose the 16 historical controls.

### Data Collection

All patients underwent a complete ophthalmic evaluation before starting the treatment and at each follow-up visit on a weekly basis for 8 weeks. Clinical assessment included slit-lamp (NIKON FS-3V Zoom Photo slit-lamp) examination implemented with corneal epithelial fluorescein staining, epithelialization times weekly monitoring, and AS-OCT (RTVue-100 applied anterior corneal module; Optovue, Fremont, CA). The size (mm) and depth ( $\mu\text{m}$ ) of NK were recorded. Corneal hypoesthesia was confirmed using a Cochet-Bonnet aesthesiometer. At the first and at each follow-up visit, several AS-OCT scans were performed: pachymetric map, horizontal raster scan centered on the thinnest area of the cornea (17 horizontal scans within a height of 6 mm), cross-line (horizontal and vertical 8.00-mm

scans), and line mode (horizontal 8.00-mm scans) on the area of minimum thinning. All scans were centered in the same area at the different visits. We identified the thinnest part of the cornea and measured the corneal and stromal thickness of this portion using the caliper tools that were built into the RTVue-100 system.

## Intervention

In the treatment group, we used a sterile, preservative-free ophthalmic solution containing 0.002% (0.02 mg/ml) of the active ingredient, cenegermin (Oxervate<sup>®</sup>, Dompé Farmaceutici Spa, Milan, Italy). It was packaged in a carton of seven multidose vials (1.0 ml). The patients were instructed to use one vial per day before being discarded and to keep the remaining vials in the carton refrigerated between 2°C and 8°C until the time of use. The scheduled treatment was one drop, six times a day at 2-h intervals for 8 weeks.

In the control group, we used 50% AS eye drops. All patients were screened for blood-borne infections, including syphilis, Hepatitis B and C, and HIV serology before the preparation of AS eye drops. Venipuncture was performed at the antecubital fossa under aseptic conditions to collect 100 ml of whole blood into sterile containers. These were left standing for 2 h to ensure complete clotting. The blood was then centrifuged for 15 min at 3000 RPM. The serum was then separated in a sterile manner and diluted to 50% using saline solution. Patients were recommended to keep the serum at 4°C. We suggested using a bottle for 1 week and administering this six times daily for 8 weeks. Additionally, this group received a prophylactic topical antibiotic (Exocin, Allergan), twice a day. The patients were seen regularly every 7 days for 8 weeks.

## Outcome Measures

- Corneal healing (time frame: at Week 8)

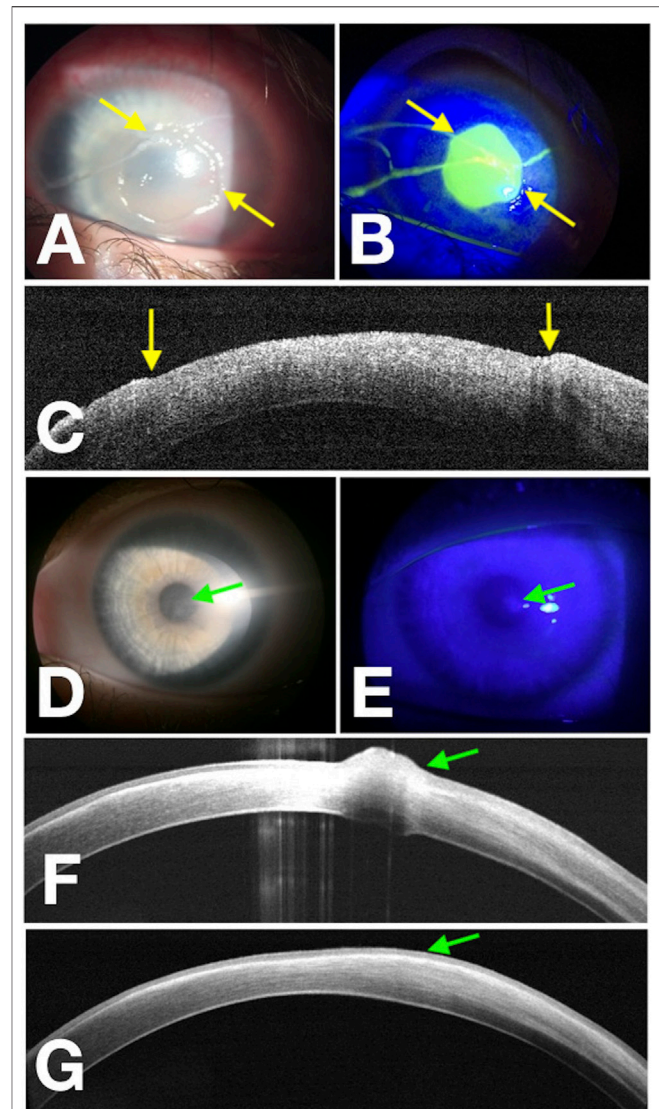
The primary outcome of this study was to achieve complete corneal healing of PED or NCU at Week 8, defined as no corneal fluorescein staining in the area of PED or NCU.

- Quantitative analysis and monitoring of the healing process (time frame: at Week 8)

The secondary end point was to assess the CT, stromal, and epithelial changes through AS-OCT (RTVue-100) and to register any adverse reactions to drug or any disease recurrence with at least 12 months of follow-up.

## Statistical Analysis

We compared the results of the AS-OCT scans with the biomicroscopic findings. The variables were summarized with mean and standard deviation for continuous variables and absolute value and percentage for frequency of categorical variables. In addition, a univariate linear regression analysis was performed to identify variables associated with the percentage change of CT by AS-OCT at the thinnest point. A standard statistical two-tailed paired *t* test was used to estimate the statistical significance of the differences between groups. All statistical analyses were performed with Stata version 15.1 (StataCorp LP, College Station, TX). The alpha level (type I error) was set at 0.05 for all analysis.

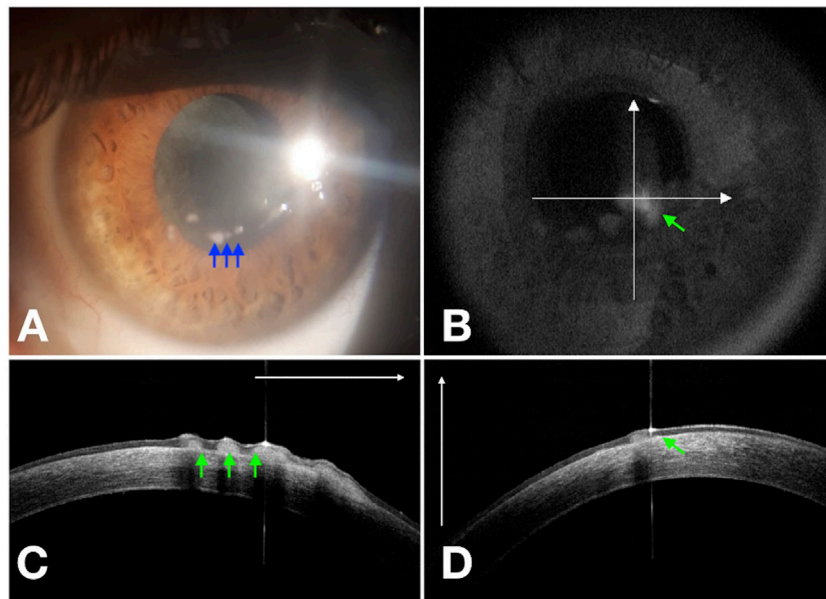


**FIGURE 1 |** Corneal wound healing of pediatric NK (rh-NGF Case 1) imaged with a multimodal approach. Yellow arrows point at the edges of the epithelial fronts in the photograph obtained at baseline with diffuse white light (A), with fluorescein staining (green) photograph obtained under cobalt-blue light illumination (B), and points to the epithelial edges in the OCT scan over the thinnest area at baseline (C). (D–F) Images acquired at the end of the treatment at Week 8, and the green arrows show a residual paracentral corneal epithelial hyperplasia. About 1 month later, OCT scan (G) reveals complete regression of the corneal epithelial hyperplasia.

## RESULTS

### Affected Eyes in the Cenegermin Group

There were 11 female and five male patients with a mean age of  $60.9 \pm 21.1$  years (range, 7–88 years) in the cenegermin group. In this group, five (31.2%) eyes experienced PED and 11 (68.8%) eyes had NCUs to varying degrees. According to the substages of NK, at Stage 3 of the Mackie's classification suggested by Mastropasqua et al. (2017), seven were Stage 3A and four were Stage 3B.



**FIGURE 2** | Residual corneal epithelial hyperplasia (blue arrows) of NK (rh-NGF Case 4) at Week 8 (A). Cross-line OCT (B) confirms the epithelial hyperplasia (green arrows) in the horizontal (C) and vertical (D) scans.

Affected eyes with PED: one recurrent herpetic epithelial lesion despite antiviral therapy, one epithelial defect after surgical treatment for acoustic nerve neuroma refractory to previously tarsorrhaphy, one PED developed on a previously transplanted cornea, one PED occurred in a child affected by a diffuse midline glioma, and one developed in the context of severe dry eye concomitant to corneal anesthesia.

Affected eyes with NCU: a cornea ulcer subsequent to a severe alkali burn, three recurrent herpetic stromal ulcers, and one NCU developed on a previously transplanted cornea in a diabetic patient. Four NCU occurred in eyes previously underwent surgical retinal detachment repair (Pars Plana Vitrectomy and endolaser). One NCU developed in the context of systemic polyneuropathy, and one occurred after a long-term topical glaucoma medication concomitant to corneal hypoesthesia.

All patients were treated by cenegermin eye drops six times a day. A total of 16 eyes of 16 patients healed completely with minimal scarring. There was no recurrence in these patients during the 12 months of follow-up time. Three eyes affected by PED (60% of PED) experienced epithelial hyperplasia regressed within the following month (Figure 1 and Figure 2). The demographic data, etiologies, stages of NK before the treatment, and percentage increase in CT after cenegermin administration are summarized in Table 1.

### Affected Eyes in the Autologous Serum Group

In the control group, there were 11 female and five male patients, and the mean age was  $67.2 \pm 18.4$  years (range, 13–86 years). There were five (31.2%) PED and 11 (68.8%) NCU, with only two in Stage 3B.

Affected eyes with PED: three recurrent herpetic epithelial lesions, one PED developed in the context of corneal hypoesthesia, and one occurred after a long-term topical glaucoma medication.

Affected eyes with NCU: one recurrent herpetic stromal ulcer, one NCU developed on a previously transplanted cornea, and one NCU refractory to previously amniotic membrane transplantation. Two NCU occurred in eyes that had previously undergone surgical retinal detachment repair (Pars Plana Vitrectomy and endolaser) and two NCU resulting from post-surgical trigeminal nerve injury. One NCU developed in systemic polyneuropathy, and three NCU developed in the context of severe dry eye disease.

We administered 50% AS eye drops six times a day. A total of 16 eyes of 16 patients healed completely with minimal scarring. The follow-up time was 12 months, and the defect recurred after the suspension of therapy in four (25%) patients during the follow-up period. The demographic data, etiologies, stages of NK, and percentage increase in CT in the AS control group are summarized in Table 1.

As in the literature data (Bonini et al., 2018a; Bonini et al., 2018b), the most common cause of NK in our patients was herpes simplex keratoplasty, followed by ocular surgery, neurosurgical trigeminal damage, and severe dry eye disease (Table 2).

Additionally, three patients reported associated systemic conditions: DM, systemic polyneuropathy, and diffuse midline glioma, respectively.

### Slit-Lamp Monitoring of the Cornea Healing Process

The epithelialization was screened by fluorescein staining test on slit-lamp examination. The mean time for closure of the

**TABLE 1** | Ocular and demographic characteristics of the treated cases and the control group, \*measured by AS-OCT.

N	Age	Gender	Eye	Underlying cause	NK (stage)	Healing time (weeks)	Post-TP CT* (%)
<b>rh-NGF</b>							
					<b>PED</b>		
1	7	M	OS	Neurosurgical procedure	2	3	73.2
2	47	M	OD	Neurosurgical procedure	2	4	31.9
3	88	F	OD	Herpetic eye disease	2	3	20.6
4	46	F	OD	Corneal hypoesthesia	2	4	54.8
5	74	F	OS	keratoplasty	2	4	50
<i>mean ± SD</i>	<i>52.4 ± 31.1</i>					<i>3.6 ± 0.5</i>	<i>46.1 ± 20.5</i>
					<b>NCU</b>		
6	76	F	OD	DM/keratoplasty	3 (IIIa)	5	53
7	64	M	OD	Herpetic eye disease	3 (IIIa)	3	81.5
8	76	F	OS	Herpetic eye disease	3 (IIIa)	4	73.2
9	58	F	OS	Ocular surgery	3 (IIIa)	4	69.5
10	45	M	OD	Ocular surgery	3 (IIIa)	5	96.2
11	86	F	OS	Polyneuropathy	3 (IIIa)	3	62
12	39	M	OD	Ocular surface injury (Chemical burn)	3 (IIIa)	4	65.3
13	61	F	OD	Ocular surgery	3 (IIIb)	4	85
14	53	F	OD	Ocular surgery	3 (IIIb)	4	90.4
15	79	F	OS	Glaucoma medication (drops)	3 (IIIb)	4	85.6
16	75	F	OS	Herpetic eye disease	3 (IIIb)	4	74
<i>mean ± SD</i>	<i>64.7 ± 15</i>					<i>4 ± 0.5</i>	<i>75.9 ± 13.1</i>
<b>PED + NCU</b>	<b>60.9 ± 21.1 (7–88)</b>					<b>3.9 ± 0.5</b>	<b>66.6 ± 20.7</b>
<b>AS</b>							
					<b>PED</b>		
1	81	M	OS	Herpetic eye disease	2	8	14
2	68	F	OD	Corneal hypoesthesia	2	7	10
3	70	F	OD	Herpetic eye disease	2	7	13.9
4	61	F	OD	Glaucoma medication (drops)	2	3	9.5
5	80	F	OS	Herpetic eye disease	2	5	9.1
<i>mean ± SD</i>	<i>72 ± 8.5</i>					<i>6 ± 2</i>	<i>11,3 ± 2.4</i>
					<b>NCU</b>		
6	69	F	OD	Severe dry eye	3 (IIIa)	3	12.4
7	77	F	OS	Severe dry eye	3 (IIIa)	4	15
8	86	M	OS	Ocular surgery	3 (IIIa)	8	16
9	74	F	OS	Herpetic eye disease	3 (IIIa)	8	18
10	84	F	OD	Ocular surgery	3 (IIIa)	8	17
11	47	M	OD	Neurosurgical procedure	3 (IIIa)	7	23.9
12	53	F	OS	Polyneuropathy	3 (IIIa)	6	11
13	56	M	OS	keratoplasty	3 (IIIa)	4	19
14	77	F	OD	Severe dry eye	3 (IIIa)	5	16
15	13	M	OS	Ocular surgery	3 (IIIb)	3	18
16	79	F	OD	Neurosurgical procedure	3 (IIIb)	8	13
<i>mean ± SD</i>	<i>65 ± 21.5</i>					<i>5.8 ± 2.1</i>	<i>16.3 ± 3.6</i>
<b>PED + NCU</b>	<b>67.2 ± 18.4 (13–86)</b>					<b>5.9 ± 2</b>	<b>14.7 ± 4</b>

*n*=number, *SD*=standard deviation, *PT CT\** (%)= post-treatment percentage increase in corneal thickness

corneal lesion was 3.9 weeks ± 0.5 (range: 3–5 weeks) and 5.9 weeks ± 1.9 (range: 3–8 weeks) for the cenegermin group and AS group, respectively. The difference in epithelialization times between the two groups was statistically significant ( $p < 0.01$ ).

Then in the cenegermin group, we clinically observed that the cornea healing was faster in patients younger than 75 years, but it was not statistically significant ( $p > 0.05$ ).

In the AS control group, we observed a 25% recurrence rate compared with no recurrence in the cenegermin group.

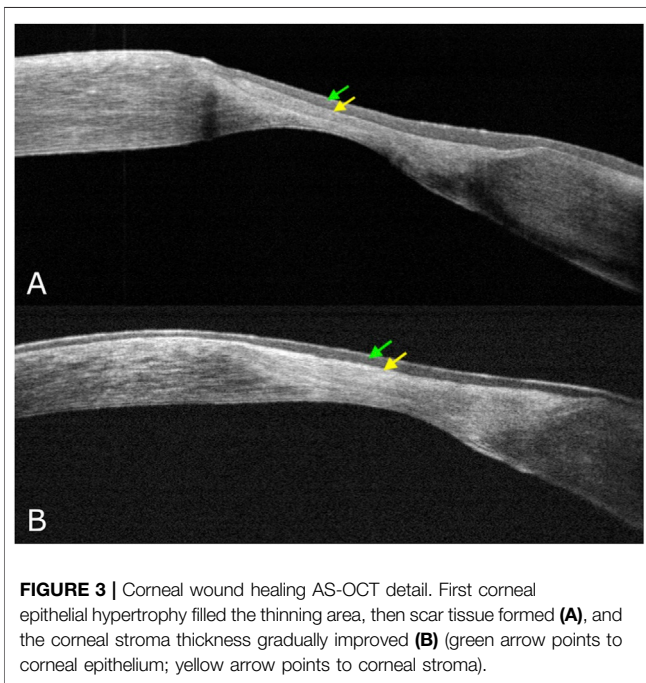
During the first phase of NK healing, opaque slit-lamp scar tissue with high reflectivity on AS-OCT, looking

different from the normal corneal stroma, was detected (**Figure 3**). At first, corneal epithelial hypertrophy filled the thinning area. Then scar tissue formed, and the corneal stroma thickness gradually improved. Second, when the scar tissue disappeared on slit-lamp examination, AS-OCT still detected an increased reflectivity of the anterior stroma at the corneal lesion site (**Figure 4**). In three PED, epithelial hyperplasia co-occurred with reepithelialization. It was appreciable with both the slit-lamp (**Figure 1D,E** and **Figure 2A**) and AS-OCT (**Figure 1F** and **Figure 2C**). Finally, within a month, it resolved in all three cases and was no longer detectable (**Figure 1G**).

**TABLE 2** | Participant baseline characteristics demonstrating that there were no significant differences in patient demographics between the treatment and historical control groups.

Baseline characteristics	rh-NGF (n = 16 eyes)	As (n = 16 eyes)	p Value
Age (years), mean ± SD (range)	60.9 ± 21.1 (7–88)	67.2 ± 18.4 (13–86)	0.13
<b>Sex</b>			0.67
Male	5 (31.2%)	5 (31.2%)	
Female	11 (68.8%)	11 (68.8%)	
<b>Diagnosis</b>			
Neurosurgical procedure	2	2	
Ocular surgery	4	3	
keratoplasty	2	1	
Herpetic eye disease	4	4	
Corneal hypoesthesia	1	1	
Ocular surface injury (chemical burn)	1	—	
Glaucoma medication (drops)	1	1	
Polyneuropathy	1	1	
Severe dry eye	—	3	

n = number, SD = standard deviation.



**FIGURE 3** | Corneal wound healing AS-OCT detail. First corneal epithelial hypertrophy filled the thinning area, then scar tissue formed (A), and the corneal stroma thickness gradually improved (B) (green arrow points to corneal epithelium; yellow arrow points to corneal stroma).

### AS-OCT Analysis and Monitoring of the Cornea Healing Process

AS-OCT scans revealed an average CT in the thinnest point of  $276.3 \pm 74.1 \mu\text{m}$  at baseline and an average increase in CT of  $176.5 \pm 60.3 \mu\text{m}$  at the end of the cenegegermin treatment (Week 8). Linear regression showed that the percentage increase of CT at the end of treatment with cenegegermin was associated with the pre-treatment CT ( $B = -0.15$ ;  $p = 0.035$ ) (Graph 1). Table 3 shows the results of the regression analysis. No other variables such as demographic factors or the epithelial defect area were associated with changes detected by AS-OCT.

Compared with the control group, AS-OCT data showed that the average percent change in CT detection was 66.6% [95% confidence interval (CI), 20.6–96.2] in the cenegegermin treatment

group and 14.7% (95% CI, 9.1–23.9) in the control group. The difference of percentage AS-OCT increase in cornea thickness between the two groups was statistically significant ( $p < 0.02$ ) (Graph 2 and Graph 3).

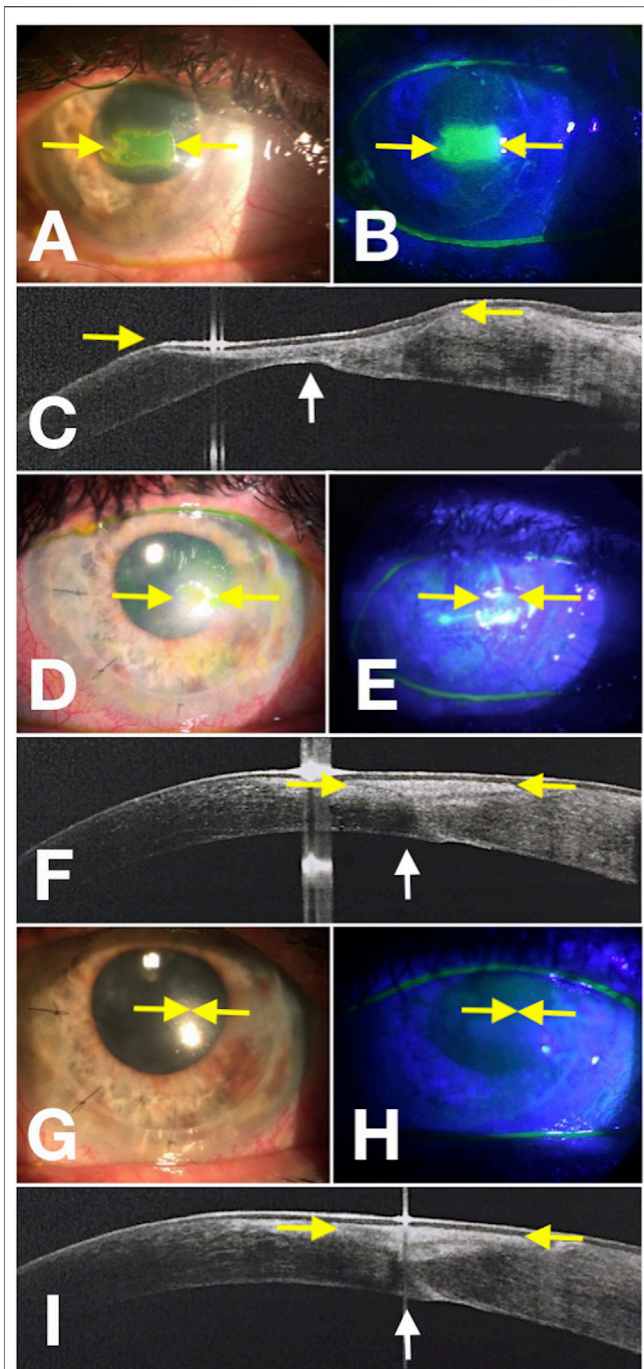
No side effects were observed in patients who received cenegegermin or AS eye drops. Furthermore, there were no serious complications such as infectious keratoplasty that were encountered during the entire study period.

### DISCUSSION

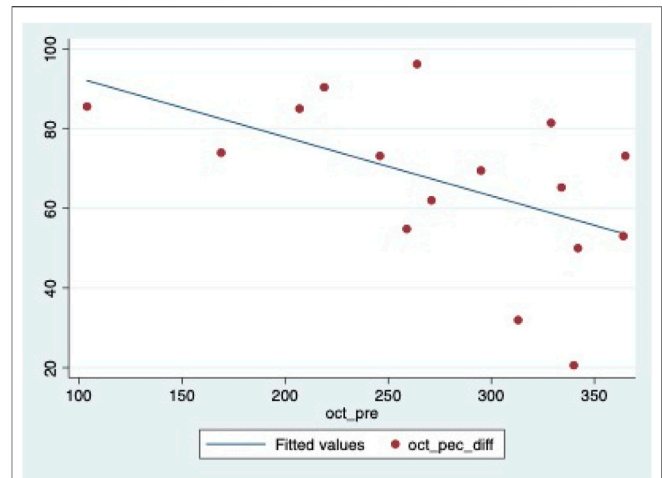
Of our cohort of patients, herpetic keratoplasty was the leading cause of corneal innervation impairment. Neurological and ocular surgical procedures, DM, and chronic glaucoma medication were other conditions involved in the disease pathogenesis.

We showed that baseline CT significantly correlates with post-treatment CT increase. The lower the baseline stromal thickness, the more significant was the effect of cenegegermin in restoring CT.

Keratocytes, collagen fibrils, and proteoglycans are essential components of the corneal stroma (Hassell and Birk, 2010). Corneal transparency is guaranteed thanks to the uniform distribution of collagen lamellae (Maurice, 1957; Meek, 2009). This primary ultrastructure could be compromised during the wound healing process, giving way to a progressive swelling and a subsequent corneal opacity, identified as a scar on slit-lamp examination. It means decreased visual acuity in clinical practice, and AS-OCT could detect it as hyper-reflective scar tissue (McCally et al., 2007; Kamma-Lorger et al., 2009; Alafaleq et al., 2021). Type 3 collagen expression is initially significantly improved during the corneal healing process (Cintrón et al., 1988). It is synthesized and deposited primarily by fibroblasts; however, it is easily broken down during tissue remodeling (Wilson et al., 2012). The scar tissue formation is probably due to the fibrotic cellular responses and an abnormally large fibril diameter formation (Wilson et al., 2012). First, the scar tissue appeared opaque, as seen with the slit lamp, and had a



**FIGURE 4 |** Corneal wound healing of neurotrophic corneal ulcer (rh-NGF Case 6) imaged with a multimodal approach. Yellow arrows point to the edges of the epithelial fronts in the photograph obtained at baseline with diffuse white light (A), with fluorescein staining (green) photograph obtained under cobalt-blue light illumination (B), and points to the ulcer area in the OCT scan detected over the thinnest area at baseline (C). (D–F) Images show the progression at Week 4, and the yellow arrows point to the epithelial edges. (G–I) Images were acquired at the end of the treatment at Week 8. The white arrows point to the change in CT detected by the AS-OCT scan (C,F,I).



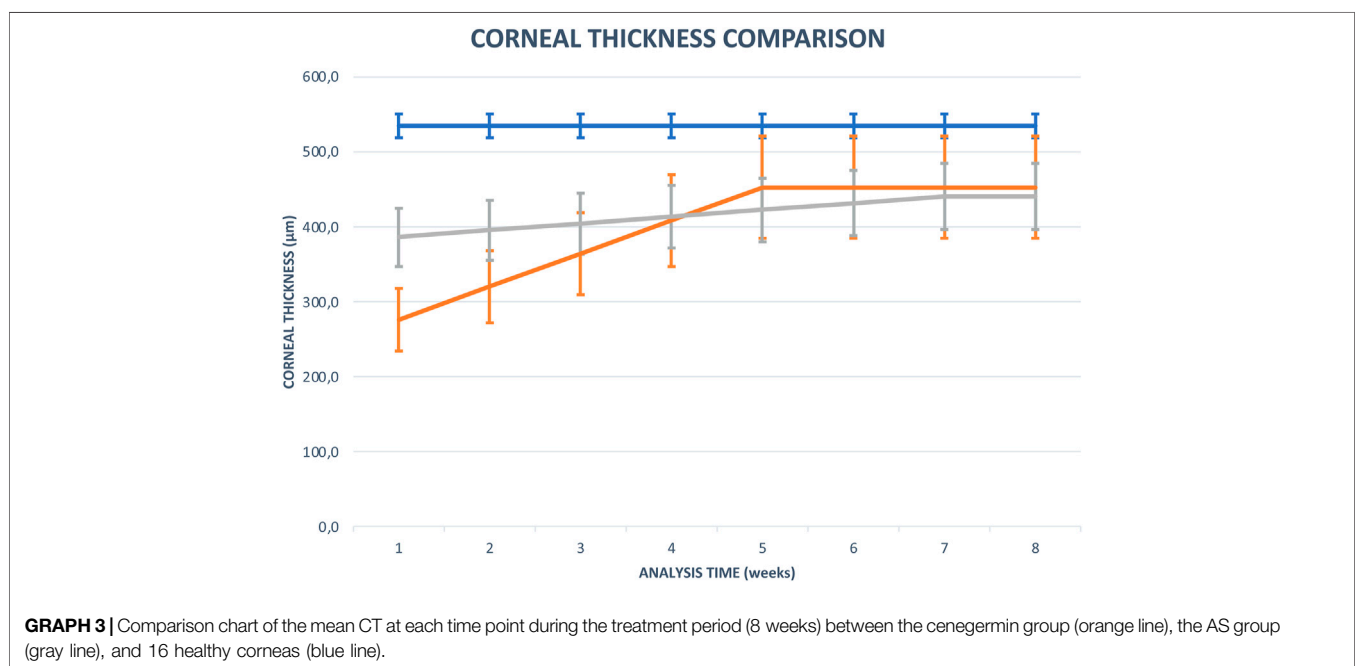
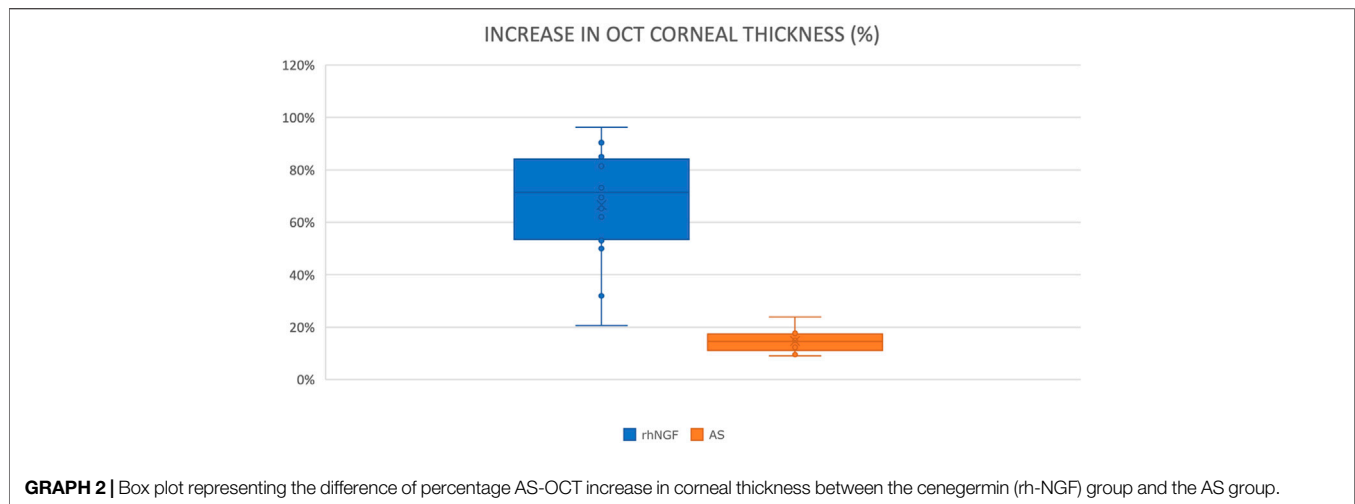
**GRAPH 1 |** Scattergram representing the association between pre-treatment CT and gain in CT at the end of the treatment.

**TABLE 3 |** Linear regression analysis. Outcome: percentage change in CT at the end of cenegermin treatment.

	Coefficient	95% CI	p-value
Age, years	-0.35	-0.88 to 0.18	0.179
Gender, female	-9.35	-33.60 to 14.90	0.422
Healing time, weeks	4.88	-14.12 to 23.87	0.591
Area pre-treatment, mm <sup>2</sup>	0.04	-0.15 to 0.24	0.631
CT pre-treatment, μm	-0.15	-0.28 to -0.02	0.035

high signal on AS-OCT, looking different from the normal corneal stroma. Second, the scar tissue disappeared on slit-lamp examination, suggesting that the cornea healing process had switched from an acute wound healing stage to a remodeling one. Utsunomiya et al. (2014) had stated that a long-term AS-OCT hyper-reflectivity persists even when the cornea clears up on slit-lamp examination, and they supposed it could be due to the scar tissue’s incapacity to come back to the original arrangement.

The characteristic of scar tissue is an abnormal alignment of the collagen fibrils, directly associated with the tissue’s transparency (Zhou et al., 2017). In our case series, we also observed that the younger the patient was, the faster the scar tissue formation, and the less time-consuming the process was to restore transparency. It is only a clinical remark, and there is no statistical significance for the small number of patients. It could mean an age-related cornea healing capacity, confirming age-related changes in the human cornea described in the literature (Marr, 1967; Alvarado et al., 1983; Faragher et al., 1997; Berlau et al., 2002; Roszkowska et al., 2004; Niederer et al., 2007; Gipson, 2013; Bonzano et al., 2021). Mechanisms underlying an age-related slowdown of collagen synthesis in damaged stroma have not been fully delineated yet.



Both cenegermin and AS eye drops proved to be effective in treating NK from different etiologies. Thanks to its biomechanical and biochemical properties, similar to natural tears (Geerling and Hartwig, 2002), the serum has gained wide acceptance in treating ocular surface disorders unresponsive to conventional medical treatment (Tsubota et al., 1999; Matsumoto et al., 2004; Bonzano et al., 2018). Epithelial growth factors such as vitamin A, fibronectin, epidermal growth factor, transforming growth factor b, substance P, and insulin-like growth factor-1 in serum could explain its efficacy in healing cornea lesion, which is usually associated with an already compromised ocular surface (Matsumoto et al., 2004).

Cenegermin in our patients proved to heal the NK faster than the AS and prevent NK recurrence in the 12-months follow-up.

According to literature data, this could be explained thanks to the ability of cenegermin in inducing corneal recovery by restoring sensory nerve supply (Bonini et al., 2018b; Pflugfelder et al., 2020).

Both treatments proved to heal NK within 8 weeks in our patients, but with different mechanisms: AS seems to restore the ocular surface providing some neural healers when administered (Matsumoto et al., 2004) and, in four cases, it required to be continued over time to maintain healing; cenegermin, by addressing the underlying cause, induces recovery of corneal nerves, and then it seems to ensure a stable framework even when discontinued with less risk of recurrence (Sacchetti et al., 2021). As recently reported by Pflugfelder et al. (2020), variables such as disease stage, time since diagnosis, and underlying



etiologies did not significantly affect the healing status. Furthermore, in our patients, as reported in the literature, no initial NK lesion size (Pflugfelder et al., 2020) impacted significantly; conversely, the pre-treatment cornea thickness detected by AS-OCT was associated with the percentage increase of CT. Therefore, monitoring the healing improvements in terms of thickness and transparency of the cornea by AS-OCT could help understand the corneal healing response to cenegermin.

We used RTVue-100 for AS-OCT that is a spectral-domain OCT that was developed for the retinal analysis. This instrument uses an 840-nm wavelength beam. We are aware that other specialized AS-OCTs by using a 1310-nm wavelength could be more performing (Georgeon et al., 2021). Anyway, RTVue-100 allowed us to detect detailed scans of the corneal healing process and its improvements over time. Thanks to its dedicated caliper tool, it also allowed us to accurately document changes by measuring the stromal thickness at the thinnest part. AS-OCT is an effective tool for systematic anterior-segment imaging, allowing the detailed detection of the front-to-back layered corneal structure for quantitative analysis and monitoring of the healing process (David et al., 2021). Using AS-OCT granted us quantitative monitoring of structural changes in NK treated by cenegermin, obtaining a better understanding of rh-NGF-driven corneal wound healing process.

## REFERENCES

- Alalafeq, M., Knoeri, J., Boutboul, S., and Borderie, V. (2021). Contact Lens Induced Bacterial Keratitis in LCD II: Management and Multimodal Imaging: a Case Report and Review of Literature. *Eur. J. Ophthalmol.* 31 (5), 2313–2318. doi:10.1177/1120672120968724
- Alvarado, J., Murphy, C., and Juster, R. (1983). Age-Related Changes in the Basement Membrane of the Human Corneal Epithelium. *Invest. Ophthalmol. Vis. Sci.* 24 (8), 1015–1028.
- Arumuganathan, N., Wiest, M. R. J., Toro, M. D., Hamann, T., Fasler, K., and Zweifel, S. A. (2021). Acute and Subacute Macular and Peripapillary Angiographic Changes in Choroidal and Retinal Blood Flow post-intravitreal Injections. *Sci. Rep.* 11 (1), 19381. doi:10.1038/s41598-021-98850-8
- Berlau, J., Becker, H. H., Stave, J., Oriwol, C., and Guthoff, R. F. (2002). Depth and Age-Dependent Distribution of Keratocytes in Healthy Human Corneas: A Study Using Scanning-Slit Confocal Microscopy *In Vivo*. *J. Cataract Refract Surg.* 28 (4), 611–616. doi:10.1016/s0886-3350(01)01227-5
- Bonini, S., Lambiase, A., Rama, P., Filatori, I., Allegretti, M., Chao, W., et al. (2018). Phase I Trial of Recombinant Human Nerve Growth Factor for Neurotrophic Keratitis. *Ophthalmology* 125 (9), 1468–1471. doi:10.1016/j.ophtha.2018.03.004
- Bonini, S., Lambiase, A., Rama, P., Sinigaglia, F., Allegretti, M., Chao, W., et al. (2018). Phase II Randomized, Double-Masked, Vehicle-Controlled Trial of Recombinant Human Nerve Growth Factor for Neurotrophic Keratitis. *Ophthalmology* 125 (9), 1332–1343. doi:10.1016/j.ophtha.2018.02.022
- Bonzano, C., Bonzano, E., Cutolo, C. A., Scotto, R., and Traverso, C. E. (2018). A Case of Neurotrophic Keratopathy Concomitant to Brain Metastasis. *Cureus* 10 (3), e2309. doi:10.7759/cureus.2309
- Bonzano, C., Cutolo, C. A., Musetti, D., Di Mola, I., Pizzorno, C., Scotto, R., et al. (2021). Delayed Re-epithelialization after Epithelium-Off Crosslinking: Predictors and Impact on Keratoconus Progression. *Front. Med.* 8, 657993. doi:10.3389/fmed.2021.657993
- Carnevali, A., Giannaccare, G., Gatti, V., Battaglia, C., Randazzo, G., Yu, A. C., et al. (2021). Retinal Microcirculation Abnormalities in Patients with Systemic Sclerosis:

## DATA AVAILABILITY STATEMENT

The raw data supporting the conclusion of this article will be made available by the authors, without undue reservation.

## ETHICS STATEMENT

This study was conducted in accordance with the Declaration of Helsinki. The protocol was reviewed and approved by the institutional independent ethics committee (code 0782019). Written informed consent from the participants was not required to participate in this study in accordance with the national legislation and the institutional requirements. However, the details of the study were explained to the patients and written informed consent was obtained from the individuals for the publication of any potentially identifiable images or data included in this article.

## AUTHOR CONTRIBUTIONS

BC: designed and directed the study. CB, SO, AM, and DS: acquisition and interpretation of data for the work. CC and EB: provided critical feedback and statistical analysis. CB, DB, EB, and CT: review and editing of the final manuscript. All authors reviewed the manuscript and agreed with its content.

- An Explorative Optical Coherence Tomography Angiography Study. *Rheumatology (Oxford)* 60 (12), 5827–5832. doi:10.1093/rheumatology/keab258
- Ceravolo, I., Oliverio, G. W., Alibrandi, A., Bhatti, A., Trombetta, L., Rejdak, R., et al. (2020). The Application of Structural Retinal Biomarkers to Evaluate the Effect of Intravitreal Ranibizumab and Dexamethasone Intravitreal Implant on Treatment of Diabetic Macular Edema. *Diagnostics (Basel)* 10 (6), E413. doi:10.3390/diagnostics10060413
- Chisari, C. G., Toro, M. D., Cimino, V., Rejdak, R., Luca, M., Rapisarda, L., et al. (2019). Retinal Nerve Fiber Layer Thickness and Higher Relapse Frequency May Predict Poor Recovery after Optic Neuritis in MS Patients. *J. Clin. Med.* 8 (11), 2022. doi:10.3390/jcm8112022
- Cintron, C., Hong, B. S., Covington, H. I., and Macarak, E. J. (1988). Heterogeneity of Collagens in Rabbit Cornea: Type III Collagen. *Invest. Ophthalmol. Vis. Sci.* 29 (5), 767–775.
- David, C., Reinstein, D. Z., Archer, T. J., Kallel, S., Vida, R. S., Goemaere, I., et al. (2021). Postoperative Corneal Epithelial Remodeling after Intracorneal Ring Segment Procedures for Keratoconus: An Optical Coherence Tomography Study. *J. Refract Surg.* 37 (6), 404–413. doi:10.3928/1081597X-20210225-02
- Dua, H. S., Said, D. G., Messmer, E. M., Rolando, M., Benitez-del-Castillo, J. M., Hossain, P. N., et al. (2018). Neurotrophic Keratopathy. *Prog. Retin. Eye Res.* 66, 107–131. doi:10.1016/j.preteyeres.2018.04.003
- European Medicines Agency (2021). EU/3/15/1586 | European Medicines Agency. Available at: <https://www.ema.europa.eu/en/medicines/human/orphan-designations/eu3151586> (Accessed July 6, 2017).
- Faragher, R. G., Mulholland, B., Tuft, S. J., Sandeman, S., and Khaw, P. T. (1997). Aging and the Cornea. *Br. J. Ophthalmol.* 81 (10), 814–817. doi:10.1136/bjo.81.10.814
- Geerling, G., and Hartwig, D. (2002). Autologous Serum-Eye-Drops for Ocular Surface Disorders. A Literature Review and Recommendations for Their Application. *Ophthalmologie* 99, 949–959. doi:10.1007/s00347-002-0661-6
- Georgeon, C., Marciano, I., Cuyaubère, R., Sandali, O., Bouheraoua, N., and Borderie, V. (2021). Corneal and Epithelial Thickness Mapping: Comparison of Swept-Source- and Spectral-Domain-Optical Coherence Tomography. *J. Ophthalmol.* 2021, 1–6. doi:10.1155/2021/3444083

- Gipson, I. K. (2013). Age-Related Changes and Diseases of the Ocular Surface and Cornea. *Invest. Ophthalmol. Vis. Sci.* 54 (14), ORSF48. doi:10.1167/iovs.13-12840
- Hassell, J. R., and Birk, D. E. (2010). The Molecular Basis of Corneal Transparency. *Exp. Eye Res.* 91 (3), 326–335. doi:10.1016/j.exer.2010.06.021
- Ishibazawa, A., Igarashi, S., Hanada, K., Nagaoka, T., Ishiko, S., Ito, H., et al. (2011). Central Corneal Thickness Measurements with Fourier-Domain Optical Coherence Tomography versus Ultrasonic Pachymetry and Rotating Scheimpflug Camera. *Cornea* 30 (6), 615–619. doi:10.1097/ICO.0b013e3181d00800
- Jeng, B. H., and Ahmad, S. (2021). In Pursuit of the Elimination of Corneal Blindness: Is Establishing Eye Banks and Training Surgeons Enough. *Ophthalmology* 128 (6), 813–815. doi:10.1016/j.ophtha.2020.06.042
- Kamma-Lorger, C. S., Boote, C., Hayes, S., Albon, J., Boulton, M. E., and Meek, K. M. (2009). Collagen Ultrastructural Changes during Stromal Wound Healing in Organ Cultured Bovine Corneas. *Exp. Eye Res.* 88 (5), 953–959. doi:10.1016/j.exer.2008.12.005
- Koman-Wierdak, E., Róg, J., Brzozowska, A., Toro, M. D., Bonfiglio, V., Załuska-Ogryzek, K., et al. (2021). Analysis of the Peripapillary and Macular Regions Using OCT Angiography in Patients with Schizophrenia and Bipolar Disorder. *J. Clin. Med.* 10 (18), 4131. doi:10.3390/jcm10184131
- Kowalczyk, M., Toro, M. D., Rejdak, R., Załuska, W., Gagliano, C., and Sikora, P. (2020). Ophthalmic Evaluation of Diagnosed Cases of Eye Cystinosis: A Tertiary Care Center's Experience. *Diagnostics (Basel)* 10 (11), 911. doi:10.3390/diagnostics10110911
- Marr, M. (1967). Zur Altersabhängigkeit der Heilung von Hornhautepitheldefektnngigkeit der Heilung von Hornhautepitheldefekten. *Albrecht von Graefes Arch. Klin. Ophthalmol. r Klin Exp. Ophthalmol.* 173 (3), 250–255. doi:10.1007/bf00410848
- Mastropasqua, L., Massaro-Giordano, G., Nubile, M., and Sacchetti, M. (2017). Understanding the Pathogenesis of Neurotrophic Keratitis: The Role of Corneal Nerves. *J. Cel Physiol* 232 (4), 717–724. doi:10.1002/jcp.25623
- Mastropasqua, L., Nubile, M., Lanzini, M., Calienno, R., and Dua, H. S. (2019). *In Vivo* microscopic and Optical Coherence Tomography Classification of Neurotrophic Keratopathy. *J. Cel Physiol* 234 (5), 6108–6115. doi:10.1002/jcp.27345
- Matsumoto, Y., Dogru, M., Goto, E., Ohashi, Y., Kojima, T., Ishida, R., et al. (2004). Autologous Serum Application in the Treatment of Neurotrophic Keratopathy. *Ophthalmology* 111, 1115–1120. doi:10.1016/j.ophtha.2003.10.019
- Maurice, D. M. (1957). The Structure and Transparency of the Cornea. *J. Physiol.* 136 (2), 263–286. doi:10.1113/jphysiol.1957.sp005758
- McCally, R. L., Freund, D. E., Zorn, A., Bonney-Ray, J., Grebe, R., de la Cruz, Z., et al. (2007). Light-Scattering and Ultrastructure of Healed Penetrating Corneal Wounds. *Invest. Ophthalmol. Vis. Sci.* 48 (1), 157–165. doi:10.1167/iovs.06-0935
- Meek, K. M. (2009). Corneal Collagen-Its Role in Maintaining Corneal Shape and Transparency. *Biophys. Rev.* 1 (2), 83–93. doi:10.1007/s12551-009-0011-x
- Muscat, S., McKay, N., Parks, S., Kemp, E., and Keating, D. (2002). Repeatability and Reproducibility of Corneal Thickness Measurements by Optical Coherence Tomography. *Invest. Ophthalmol. Vis. Sci.* 43 (6), 1791–1795.
- Niederer, R. L., Perumal, D., Sherwin, T., and McGhee, C. N. (2007). Age-related Differences in the normal Human Cornea: A Laser Scanning *In Vivo* Confocal Microscopy Study. *Br. J. Ophthalmol.* 91 (9), 1165–1169. doi:10.1136/bjo.2006.112656
- Nubile, M., Dua, H. S., Lanzini, M., Ciancaglini, M., Calienno, R., Said, D. G., et al. (2011). *In Vivo* analysis of Stromal Integration of Multilayer Amniotic Membrane Transplantation in Corneal Ulcers. *Am. J. Ophthalmol.* 151 (5), 809–822. doi:10.1016/j.ajo.2010.11.002
- Pflugfelder, S. C., Massaro-Giordano, M., Perez, V. L., Hamrah, P., Deng, S. X., Espandar, L., et al. (2020). Topical Recombinant Human Nerve Growth Factor (Cenegegermin) for Neurotrophic Keratopathy: A Multicenter Randomized Vehicle-Controlled Pivotal Trial. *Ophthalmology* 127 (1), 14–26. doi:10.1016/j.ophtha.2019.08.020
- Reibaldi, M., Uva, M. G., Avitabile, T., Toro, M. D., Zagari, M., Mariotti, C., et al. (2012). Intrasession Reproducibility of RNFL Thickness Measurements Using SD-OCT in Eyes with Keratoconus. *Ophthalmic Surg. Lasers Imaging* 43 (6 Suppl. 1), S83–S89. doi:10.3928/15428877-20121001-04
- Roszkowska, A. M., Colosi, P., Ferreri, F. M., and Galasso, S. (2004). Age-Related Modifications of Corneal Sensitivity. *Ophthalmologica* 218 (5), 350–355. doi:10.1159/000079478
- Sacchetti, M., Komaiha, C., Bruscolini, A., Albanese, G. M., Marengo, M., Colabelli Gisoldi, R. A. M., et al. (2021). Long-term Clinical Outcome and Satisfaction Survey in Patients with Neurotrophic Keratopathy after Treatment with Cenegegermin Eye Drops or Amniotic Membrane Transplantation. *Graefes Arch. Clin. Exp. Ophthalmol* [Epub ahead of print]. doi:10.1007/s00417-021-05431-6
- Sacchetti, M., and Lambiase, A. (2014). Diagnosis and Management of Neurotrophic Keratitis. *Clin. Ophthalmol.* 8, 571–579. doi:10.2147/OPTH.S45921
- Semeraro, F., Forbice, E., Romano, V., Angi, M., Romano, M. R., Filippelli, M. E., et al. (2014). Neurotrophic Keratitis. *Ophthalmologica* 231 (4), 191–197. doi:10.1159/000354380
- Toro, M., Choragiewicz, T., Posarelli, C., Figus, M., and Rejdak, R. (2020). Early Impact of COVID-19 Outbreak on the Availability of Cornea Donors: Warnings and Recommendations. *Clin. Ophthalmol.* 14, 2879–2882. doi:10.2147/OPTH.S260960
- Tsubota, K., Goto, E., Shimmura, S., and Shimazaki, J. (1999). Treatment of Persistent Corneal Epithelial Defect by Autologous Serum Application. *Ophthalmology* 106, 1984–1989. doi:10.1016/S0161-6420(99)90412-8
- Utsunomiya, T., Hanada, K., Muramatsu, O., Ishibazawa, A., Nishikawa, N., and Yoshida, A. (2014). Wound Healing Process after Corneal Stromal Thinning Observed with Anterior Segment Optical Coherence Tomography. *Cornea* 33 (10), 1056–1060. doi:10.1097/ICO.0000000000000223
- Venkateswaran, N., Galor, A., Wang, J., and Karp, C. L. (2018). Optical Coherence Tomography for Ocular Surface and Corneal Diseases: A Review. *Eye Vis. (Lond)* 5 (1), 13. doi:10.1186/s40662-018-0107-0
- Wiest, M. R. J., Toro, M. D., Nowak, A., Baur, J., Fasler, K., Hamann, T., et al. (2021). Globotriaosylsphingosine Levels and Optical Coherence Tomography Angiography in Fabry Disease Patients. *J. Clin. Med.* 10 (5), 1093. doi:10.3390/jcm10051093
- Wilson, S. L., El Haj, A. J., and Yang, Y. (2012). Control of Scar Tissue Formation in the Cornea: Strategies in Clinical and Corneal Tissue Engineering. *J. Funct. Biomater.* 3 (3), 642–687. doi:10.3390/jfb3030642
- Zhou, H. Y., Cao, Y., Wu, J., and Zhang, W. S. (2017). Role of Corneal Collagen Fibrils in Corneal Disorders and Related Pathological Conditions. *Int. J. Ophthalmol.* 10 (5), 803–811. doi:10.18240/ijo.2017.05.24
- Zweifel, S. A., Foa, N., Wiest, M. R. J., Carnevali, A., Załuska-Ogryzek, K., Rejdak, R., et al. (2021). Differences between Mycobacterium Chimaera and Tuberculosis Using Ocular Multimodal Imaging: A Systematic Review. *J. Clin. Med.* 10 (21), 4880. doi:10.3390/jcm10214880

**Conflict of Interest:** The authors declare that the research was conducted in the absence of any commercial or financial relationships that could be construed as a potential conflict of interest.

**Publisher's Note:** All claims expressed in this article are solely those of the authors and do not necessarily represent those of their affiliated organizations, or those of the publisher, the editors, and the reviewers. Any product that may be evaluated in this article, or claim that may be made by its manufacturer, is not guaranteed or endorsed by the publisher.

Copyright © 2022 Bonzano, Olivari, Cutolo, Macri, Sindaco, Borroni, Bonzano and Traverso. This is an open-access article distributed under the terms of the Creative Commons Attribution License (CC BY). The use, distribution or reproduction in other forums is permitted, provided the original author(s) and the copyright owner(s) are credited and that the original publication in this journal is cited, in accordance with accepted academic practice. No use, distribution or reproduction is permitted which does not comply with these terms.