



Yolk Sac Tumor in an Eight-Year-Old Girl: A Case Report and Literature Review

Li Hsun Chen^{1†}, Kui-Chuen Yip^{2†}, Hsing-Ju Wu^{3,4} and Su-Boon Yong^{5,6,7*}

¹ Asian Institute of Tele-surgery (IRCAD-Taiwan), Chang Bing Show Chwan Memorial Hospital, Lukang, Taiwan, ² Division of Family Medicine, Chang Bing Show Chwan Memorial Hospital, Lukang, Taiwan, ³ Research Assistant Center, Show Chwan Memorial Hospital, Changhua, Taiwan, ⁴ Department of Medical Research, Chang Bing Show Chwan Memorial Hospital, Lukang, Taiwan, ⁵ Institute of Medicine, Chung Shan Medical University, Taichung, Taiwan, ⁶ Division of Pediatric Allergy, Immunology and Rheumatology, Department of Pediatrics, Show Chwan Memorial Hospital, Changhua, Taiwan, ⁷ Department of Nursing, Meiho University, Pingtung, Taiwan

OPEN ACCESS

Edited by:

Qiangsong Tong,
Huazhong University of Science and
Technology, China

Reviewed by:

Alfredo Berrettini,
IRCCS Ca 'Granda Foundation
Maggiore Policlinico Hospital, Italy
María José Martínez-Urrutia,
Hospital de Niños La Paz, Bolivia

*Correspondence:

Su-Boon Yong
yongsuboon@gmail.com

[†]Co-first authors

Specialty section:

This article was submitted to
Pediatric Urology,
a section of the journal
Frontiers in Pediatrics

Received: 23 January 2019

Accepted: 12 April 2019

Published: 30 April 2019

Citation:

Chen LH, Yip K-C, Wu H-J and
Yong S-B (2019) Yolk Sac Tumor in an
Eight-Year-Old Girl: A Case Report
and Literature Review.
Front. Pediatr. 7:169.
doi: 10.3389/fped.2019.00169

Yolk sac tumor (YST), which most frequently arises in the gonads as a type of germ cell tumor, is rare in children but is highly malignant. It has been suggested that alpha-fetoprotein (AFP) can be applied as a feasible tumor marker because its level was elevated in >90% of YST. The treatment generally involves debulking surgery of tumors followed by systemic chemotherapy. Metastasis process of YST in children is different from that in adults and thus the treatment option is required. In this study, we described a rare case of YST in terms of the clinical manifestation, imaging, and histopathology findings, diagnosis and treatment in an 8-year-old girl. Furthermore, it is important to investigate more thoroughly a patient with history of intermittent abdominal pain and fever with previously multiple accesses, because these might be the critical signs for YST that should be alarmed for early treatment. Although YST is rare in children, pediatric physicians should be aware of this and prompt treatment should be addressed.

Keywords: alpha-fetoprotein, chemotherapy, yolk sac tumor, pediatric, surgery

INTRODUCTION

Ovarian germ cell tumors (OGCTs) in which neoplasms form in the germ cells of the ovary, account for about 15~20% of all ovarian neoplasms (1). Only 1~2% of OGCTs are malignant called malignant ovarian germ cell tumors (MOGCTs) and constitute around 3~5% of all malignant ovarian neoplasms (2). Yolk sac tumor (YST) or endodermal primitive tumor accounting the second most common tumor in MOGCTs (3) is rare and typically occurs in gonads (4, 5). YST often presents in young women or adolescent girls with the ages between 18 and 30 years old; ~33% of YST patients are premenarchal (1, 6). In comparison with epithelial ovarian tumors, YST is highly malignant growing rapidly with a very brief duration of symptoms which metastasizes fast and intrudes all intra-abdominal structures and retroperitoneal lymph nodes (5, 7). YST was universally life-threatening before the development of combination chemotherapy. With the introduction of novel chemotherapeutic regimens in the end of 1970s, the 5-year survival rates of YST significantly improved from 14% to nearly 90% (8). Especially adding cisplatin to combination therapies, prognosis of the patients reached excellent values, even for patients with advanced stages (5). Therefore, YST is rare in children and malignant; however, it could be cured usually. In this study, we described a rare case of YST in an 8-year-old girl in terms of the clinical presentation, imaging findings, diagnosis, and treatment.

CASE PRESENTATION

An 8-year-old girl suffered from intermittent abdominal pain and fever for 3 weeks. She had visited local clinics and regional hospital for several times. Oral medication was prescribed for pain and constipation, but her symptoms persisted. Then, she was brought to the Pediatrics outpatient department with nausea, vomiting and lower abdominal pain for 2 months. On physical examination, lower abdomen tenderness, and pale looking were noted. The ultrasonography (US) showed a huge pelvic tumor measuring 11.1×9.4 cm in size with cystic mass (3.6×2.8 cm) and bloody ascites over right subhepatic and lower abdominal area. There was no family history of cancer. The clinical diagnosis was pelvic mass, possibly neoplastic in nature. Computed tomography (CT) revealed a large pelvic mass, measuring $12 \times 9.7 \times 7.38$ cm in size with internal heterogeneity and gynecological origin (ovary or uterus), enlarged paraaortic and mesenteric lymph nodes and fluid in Morrison pouch (**Figure 1A**). A three-dimensional (3D) virtual model was created from 1.25-mm thin-slice CT images and the green area illustrates the tumor (**Figure 1B**). The personal 3D model of patient's pelvic part may further improve the understanding of complex anatomy of the uterus, bladder and blood vessels. The values of tumor markers, alpha-fetoprotein (AFP), CA125 and beta human chorionic gonadotropin (hCG) were 13220.25 ng/ml, 536.7 U/ml, and <1.2 mIU/ml, respectively. The tumor was at the central pelvic cavity with direct invasion to the surrounding organs including the rectal and sigmoid colon walls, small

bowel walls, the bladder wall and the cul-de-sac. In addition, it also involved the left para-adnexal tissues and the tip of appendix. Thus, the patient underwent debulking operation in which bilateral salpingo-oophorectomy, pelvic lymph node dissection, omentectomy, appendectomy, and radical excision of the implanted tumors were performed. Although the left ovary *per se* was grossly not involved by tumor, metastasis occurred as tumor invasion to the left periaortic tissues and the left infundibulopelvic ligament were noted, thus left salpingo-oophorectomy was also done in order to prevent residual tumors and possible secondary surgery.

The patient was discharged 5 days after operation and recovered well. Gross examination of the specimen submitted for pathology showed a piece of necrotic tissue, measuring $3.5 \times 2.0 \times 0.3$ cm in size. H&E stained sections of the specimen revealed tumor necrosis with small focus of atypical cells with hyperchromatic nuclei mainly in glandular or reticular pattern. Immunohistochemical staining revealed the residual cells were immunoreactive to AFP and glypican-3 (GPC-3). The findings were consistent with YST. The patient was then referred to the oncologist for further treatment and under stringent follow-up.

DISCUSSION

YST is a rare tumor of childhood, which account for $\sim 3.5\%$ of all childhood cancers (<15 years) and usually arises in gonads, testis or ovary, thus a type of germ cell tumor. The incidence between the ages 15 and 19 rises to 16% (9). Approximately

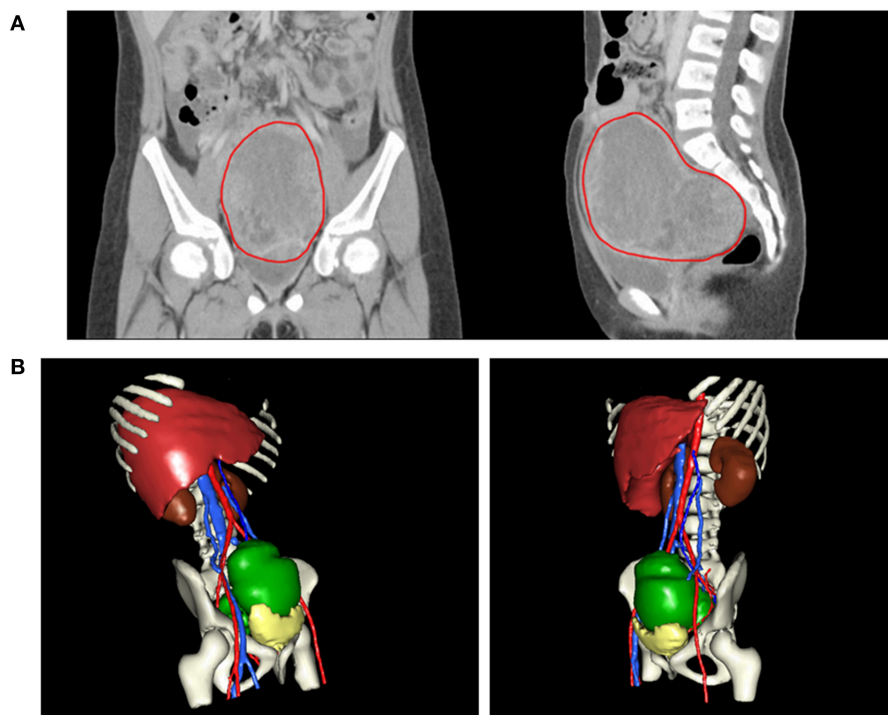


FIGURE 1 | (A) CT revealing a large pelvic mass measuring $12 \times 9.7 \times 7.38$ cm in size (circled by red line). **(B)** A three-dimensional virtual model created from 1.25-mm thin-slice CT images showing the tumor of $12 \times 9.7 \times 7.38$ cm in size (green).

one-third are extra-gonadal origins, such as vagina, mediastinum, pineal gland, cervix, endometrium, and sacrococcygeal area (9–12). It has also been reported that YST occurred in penile shaft, urachus, stomach, liver, lungs, heart, thyroid, nasal region, cranial base, vulva, retroperitoneum, prostate, pericardium, diaphragm, mesentery, mouth, ears, omentum, eyes, and subcutaneous region (13–30). Also, the recent YST case reports in children are summarized in **Table 1**. There are two types of MOGCTs, germinomatous and non-germinomatous (2, 34). YST are the commonest non-germinomatous MOGCTs (34). In children, the vast majority of YST (85%) presented as clinical stage I in comparison with 35% in adults (35).

There are a number of diagnostic tools applied for YST, such as US, CT, magnetic resonance imaging (MRI) and histopathological analysis (**Table 1**). US characterizes the adnexal mass and shows ascites or hepatic metastasis. CT scan detects carcinosis and adenopathy, MRI reveals the hyper-vascularized and hemorrhagic feature of the mass (36). Moreover, exploratory laparotomy is emerging as a tool to detect the details of the tumor and surrounding involvement and also for biopsy (10, 32). YST are heterogeneous with a number of different histopathological subtypes. In newborns and younger children, YST are predominant variant, whereas there are a wide variety of subtypes in adolescent. The typical histopathological features of YST are solid, tubular and focal papillary patterns with Schiller-Duval bodies and sinusoidal structures with fibrovascular cores lined by tumor cells, frequent mitotic figures and are cytokeratinpositive (14, 31).

It has been suggested that AFP can be applied as a feasible tumor marker because its level was elevated in >90% of YST (37). In our case, the level of AFP was also increased (13220.25 ng/ml). Thus, the prognosis of patients can be monitored by the AFP level after operation. It has been reported that the lowering level of post-operative serum AFP could be a useful marker for determining if residual cancer cells still exist after surgery (38). The national comprehensive cancer network (2016) recommends that patients who completed clinical course are monitored by AFP every 2–4 months for 2 years after treatment (36). Also, response to chemotherapy could be assessed by the AFP level (34). In particular, a postoperative AFP level of >1,000 ng/ml could serve as a prognostic indicator for the ovarian YST patients (39). However, the studies suggest a slight increase in AFP should not be applied as the sole criterion for chemotherapy decision (40).

The exact pathogenesis of YST remains obscure. However, some studies propose that it occurs from malignant transformation of misplaced germ cells. During the 4–6th week of embryogenesis, germ cells migrate laterally between the embryonic ectoderm and endoderm; germ cell tumor can arise anywhere along the migration from the mesoderm to the future cranial area (4). Although the pathogenesis of extragonadal germ cell tumors is unclear, two possible explanations were proposed: (1) misintegration of germ cells during development of embryo and (2) distribution of germ cells to other organs (41). Therefore, more research is required for investigating the mechanism of pathogenesis in order to develop for effective treatment for YST.

The general treatment for YST is surgery for eliminating the primary tumor without severe morbidity (34) (**Table 1**). In patients with stage I YST, previous studies proved that treatment of adnexectomy showed equivalent results to extensive surgery (8, 42). The treatment of OGCTs in the advanced stage generally involves debulking surgery of tumors followed by adjuvant chemotherapy (7) (**Table 1**). Several studies support the regimen of BEP (bleomycin, etoposide, and cisplatin) for primary treatment of the OGCT patients (36). They demonstrated a significantly high 5-year survival rate of 94%, even for the patients with residual cancers (42–44). The national comprehensive cancer network recommends 3–4 BEP cycles after surgical resection (36). Furthermore, it was reported that platinum-based chemotherapy should be used for the more malignant tumors such as endodermal sinus tumor and mixed germ cell tumor (45, 46). Neoadjuvant chemotherapy could be considered for the patients having extensive intra-abdominal disorders when initial surgical debulking is not preferred (47). Chemotherapy is suggested for treating recurrence (37). BEP chemotherapy is considered as a gold-standard first-line treatment for germ cell tumors at all stages (48). An important issue to consider for treating young patients is to reserve fertility by using fertility sparing strategy. Fertility-sparing surgery is possible to achieve because most tumors are unilateral (34). Furthermore, minimally invasive surgery has been proved to have better prognosis (34). Rudaitis et al. (47) applied neoadjuvant chemotherapy of four BEP cycles to decrease the tumor size in order to minimize the extent of surgery and thus the impact on the patient's fertility. In spite of the risks of damaging the reproductive function of female patients involved in chemotherapy, previous investigations have revealed that most of the women could recover their normal menstrual and reproductive functions post treatment (49, 50). After treatment, follow-ups are required such as abdominal and pelvic examination, CT, chest X-ray and AFP levels (51). Furthermore, YST metastasizes through the hematogenous route in >50% of the pediatric patients in comparison with only 4–6% of the adult patients (52). This fact modifies the therapeutic strategy. Thus, Retroperitoneal Lymph Node Dissection (RPLND) would not be the appropriate treatment for pediatric patients and complications such as wound infection, atelectasis, pulmonary insufficiency secondary to bleomycin-induced interstitial fibrosis, chylous ascities, small bowel obstruction, and subsequently ejaculatory dysfunction could occur (37). Herein, we also provided our experience in managing YST in children.

CONCLUSION

Our case highlights the importance of YST in children, and we provided our valuable experiences in the approaches of diagnosis and treatment for YST in children. Furthermore, it is important to investigate more thoroughly a patient with history of intermittent abdominal pain and fever with previously multiple accesses, because these might be the critical signs for YST that should not be neglected in order to treat the patient earlier. Although YST is rare in children, pediatric physicians should be still aware of this as it can be fatal and prompt treatment should be addressed.

TABLE 1 | Summary of the reported cases for yolk sac tumor in children after 2010.

| No. | Age/gender | Initial symptoms | Diagnosis | Size and location of tumor | Alpha fetoprotein (AFP) | Treatment | Death | References |
|-----|---------------------------------------|---|---|--|-----------------------------|--|-----------|------------|
| 1 | 12 months/female; 46 months/female | Vaginal bleeding; Vaginal bleeding | US, CT, MRI, exploratory laparotomy and histopathological analysis; Otoscope, US, MRI, vaginotomy, cystoscopy and histopathological analysis | 5 cm, 2 cm | 34, 247 ng/ml; 4.4 ng/ml | Three cycles of PEB (cisplatin, etoposide, bleomycin) chemotherapy every 3 weeks. Thereafter, JEB (carboplatin, etoposide, and bleomycin) chemotherapy every 4 or 5 weeks. Surgery and four cycles of JEB chemotherapy every 3 or 4 weeks | No; No | (10) |
| 2 | 9 months/female | Right-sided facial swelling | MRI, histopathological analysis, US, bone marrow examination, cerebrospinal fluid examination, and bone scan | 3.2 × 3.0 × 5.6 cm, right masticator space | 18,964 ng/ml | Surgery and four cycles of PEB chemotherapy | No | (25) |
| 3 | 9 months/female | Intermittent fever, cough, and mild tachypnea | Chest X-ray, US, CT, laparotomy, and pathological analysis | 10 × 10 × 7.4 cm, right upper abdomen, and right lower chest | 10,055 ng/ml | Chemotherapy with eight cycles of carboplatin, etoposide, and bleomycin (the JEB regimen) every 3 weeks, surgery and 1 more cycle of chemotherapy with carboplatin, VP16, and bleomycin | No | (17) |
| 4 | 5 years/male | A large distal penile shaft mass associated with multiple groin swellings | US and pathological analysis | Two masses of 10 × 8 × 6 cm and 6 × 6 × 4 cm, penile shaft | – | Surgery and three courses of PEB chemotherapy | Yes | (15) |
| 5 | 10 years/female | An enlarging, non-painful right-sided neck mass | US, CT, histopathological analysis and flexible bronchoscopy | 5.1 × 3.5 × 3.6 cm, right thyroid lobe | 14,204.7 ng/ml | Right hemithyroidectomy and four 3-week cycles of PEB chemotherapy | No | (21) |
| 6 | 14 months/female | A rapidly-growing mass in the floor of her mouth, dysphagia | MRI and histopathological analysis | 3 × 4 cm, oral cavity above the geniohyoid muscles | – | Surgery | Yes | (23) |
| 7 | 3 years/female | A swelling in the back | X-ray, US, histopathological analysis, CT, MRI, and bone scintigraphy | 5 × 7 mm, left lumbar paravertebral subcutaneous region | 278 IU/ml | Surgery and five cycles of PEB chemotherapy | No | (24) |
| 8 | 2 years/male | Gradual progressive forward protrusion of the right eye | CT, MRI and histopathological analysis | supernasal quadrant of the right orbit | 78.1 ng/ml | Surgery and four 3-week cycles of PEB chemotherapy | No | (26) |
| 9 | 13 months/female | Hematoma on the upper lip | MRI, histopathological analysis, CT and US | 4 × 5 cm, at the midline of the upper lip | >1,308 ng/ml | Two cycles of Adriamycin, vincristine, cyclophosphamide and cisplatin (AVCP) chemotherapy and 1 cycle of ifosfamide, etoposide, and vincristine (IEV) chemotherapy and surgery | No | (27) |
| 10 | 18 months/male | Fever, cough, and breathlessness | CT and histopathological analysis | multiple hyperchoic nodules in both lung fields | 9,322 ng/ml | Surgery and adjuvant chemotherapy | Yes | (28) |

(Continued)

TABLE 1 | Continued

| No. | Age/gender | Initial symptoms | Diagnosis | Size and location of tumor | Alpha fetoprotein (AFP) | Treatment | Death | References |
|-----|------------------|--|--|---|-------------------------|---|-------|------------|
| 11 | 18 months/female | – | Histopathological analysis, MRI, and US | 1.5 × 1.3 × 0.8 cm, right hypochoondriac region of the abdominal wall connected to skin | 58 ng/ml | Surgery | No | (31) |
| 12 | 9 years/female | Abdominal distention with a dull aching pain | CT, exploratory laparotomy, and histopathological analysis | 15 × 13 × 12 cm, left ovary | > 1,000 ng/ml | Surgery (left salpingo-oophorectomy, omentectomy, appendectomy with removal of the serosal deposits over the terminal ileum and sigmoid) and BEP chemotherapy | No | (32) |
| 13 | 14 months/female | Intermittent blood in the diaper | US, cystoscopy, vaginotomy, and MRI | 3.6 × 2.3 × 2.5 cm, vagina | 1,386 ng/ml | Four cycles of PEB chemotherapy | No | (12) |
| 14 | 15 years/male | Swelling of his face and neck, dyspnea, cough with whitish sputum, dysphagia | Chest X-ray, CT, electrocardiogram (ECG), echocardiography, and histopathological analysis | 15 × 12 cm, anterior mediastinum predominantly on the left hemithorax | > 8,000 ng/ml | Five fraction of radiotherapy (total of 1,500 cGy) | Yes | (29) |
| 15 | 3 years/male | Melena, anemia, progressive abdominal distention and low-grade fever | Upper gastrointestinal endoscopy, CT, histopathological analysis, and laparotomy | 7 × 8 cm, epigastrium | 21,000 ng/ml | Three courses of 3 weekly PEB chemotherapy and sleeve gastrectomy with omentectomy | No | (30) |
| 16 | 13 years/female | Deepening of the voice and amenorrhea | MRI and histopathological analysis | 14.3 × 14.5 × 8.0 cm, displacing the front of the uterus | > 1,210 ng/ml | Surgery: unilateral salpingo-oophorectomy and partial omentectomy and four courses of PEB chemotherapy | No | (33) |
| 17 | 8 years/female | Intermittent abdominal pain and fever | US, CT, and histopathological analysis | 12 × 9.7 × 7.38 cm, over right subhepatic and lower abdominal area | 13,220.25 ng/ml | Debulking operation: bilateral salpingo-oophorectomy, pelvic lymph node dissection, omentectomy, appendectomy, and radical excision of the implanted tumors | No | Our case |

ETHICS STATEMENT

We have obtained verbal and written informed consent from the patient's guardian for the publication of this case report.

REFERENCES

- Kojimahara T, Nakahara K, Takano T, Yaegashi N, Nishiyama H, Fujimori K, et al. Yolk sac tumor of the ovary: a retrospective multicenter study of 33 Japanese women by Tohoku Gynecologic Cancer Unit (TGCU). *Tohoku J Exp Med.* (2013) 230:211–7. doi: 10.1620/tjem.230.211
- Dallenbach P, Bonnefoi H, Pelte MF, Vlastos G. Yolk sac tumours of the ovary: an update. *Eur J Surg Oncol.* (2006) 32:1063–75. doi: 10.1016/j.ejso.2006.07.010
- Quirk JT, Natarajan N. Ovarian cancer incidence in the United States, 1992–1999. *Gynecol Oncol.* (2005) 97:519–23. doi: 10.1016/j.ygyno.2005.02.007
- Dede M, Pabuccu R, Yagci G, Yenen MC, Goktolga U, Gunhan O. Extragenital yolk sac tumor in pelvic localization: a case report and literature review. *Gynecol Oncol.* (2004) 92:989–91. doi: 10.1016/j.ygyno.2003.12.026
- Umezumi T, Kajiyama H, Terauchi M, Shibata K, Ino K, Nawa A, et al. Long-term outcome and prognostic factors for yolk sac tumor of the ovary. *Nagoya J Med Sci.* (2008) 70:29–34.
- Fujita M, Inoue M, Tanizawa O, Minagawa J, Yamada T, Tani T. Retrospective review of 41 patients with endodermal sinus tumor of the ovary. *Int J Gynecol Cancer.* (1993) 3:329–35.
- McBee WC Jr, Brainard J, Sawady J, Rose PG. Yolk sac tumor of the ovary associated with endometrioid carcinoma with metastasis to the vagina: a case report. *Gynecol Oncol.* (2007) 105:244–7. doi: 10.1016/j.ygyno.2006.07.042
- Nawa A, Obata N, Kikkawa F, Kawai M, Nagasaka T, Goto S, et al. Prognostic factors of patients with yolk sac tumors of the ovary. *Am J Obstet Gynecol.* (2001) 184:1182–8. doi: 10.1067/mob.2001.113323
- Bernstein L, Smith ML. Germ cell trophoblastic and other gonadal neoplasms ICCX 1975–2004. In: Ries L, Melbert D, Krapcho M, editors. *SEER Cancer Statistics Review*. Bethesda, MD: National Cancer Institute (2007). p. 125–37.
- Watanabe N, Okita H, Matsuoka K, Kiyotani C, Fujii E, Kumagai M, et al. Vaginal yolk sac (endodermal sinus) tumors in infancy presenting persistent vaginal bleeding. *J Obstet Gynaecol Res.* (2010) 36:213–6. doi: 10.1111/j.1447-0756.2009.01083.x
- Sudour-Bonnange H, Orbach D, Kalfa N, Fasola S, Patte C. Germ cell tumors in atypical locations: experience of the TGM 95 SFCE trial. *J Pediatr Hematol Oncol.* (2014) 36:646–8. doi: 10.1097/MPH.0000000000000083
- Lightfoot MA, Bilgutay AN, Kirsch AJ. A rare case of pediatric vaginal yolk sac tumor. *Urology.* (2018) 119:137–9. doi: 10.1016/j.urology.2018.01.007
- Liang TC, Lu MY, Chen SJ, Lu FL, Lin KH. Cardiac tamponade caused by intrapericardial yolk sac tumor in a boy. *J Formos Med Assoc.* (2002) 101:355–8.
- Alkatan HM, Al-Kofide A, Al-Hussain H. Yolk sac tumor: histopathologic report of 2 cases. *Can J Ophthalmol.* (2008) 43:125–6. doi: 10.3129/i07-198
- Samaila MO, Maitama HY, Abdullahi K, Mbibu H, Waziri GD. Yolk sac tumour of the penile shaft: a rare primary extra-gonadal presentation. *Afr J Paediatr Surg.* (2011) 8:241–3. doi: 10.4103/0189-6725.86074
- Magni E, Sonzogni A, Zampino MG. Primary pure gastric yolk sac tumor. *Rare Tumors.* (2010) 2:e10. doi: 10.4081/rt.2010.e10
- Choi YS, Liu HC, Yeh TC, Hou JY, Sheu JC, Chen BF, et al. Primary diaphragmatic yolk sac tumor and review of the literature. *J Pediatr Hematol Oncol.* (2011) 33:e77–9. doi: 10.1097/MPH.0b013e3181ff0e17
- Haibin Z, Yue J, Yaxian X. Primary yolk sac tumor of the omentum: a case report and literature review. *Eur J Gynaecol Oncol.* (2010) 31:682–4. doi: 10.1159/000337281
- Subrahmanya NB, Kapadi SN, Junaid TA. Primary yolk sac (endodermal sinus) tumour of the vulva: a case report. *Med Princ Pract.* (2011) 20:90–2. doi: 10.1159/000319917
- Warren M, Thompson KS. Two cases of primary yolk sac tumor of the liver in childhood: case reports and literature review. *Pediatr Dev Pathol.* (2009) 12:410–6. doi: 10.2350/08-09-0521.1
- Furtado LV, Leventaki V, Layfield LJ, Lowichik A, Muntz HR, Pysher TJ. Yolk sac tumor of the thyroid gland: a case report. *Pediatr Dev Pathol.* (2011) 14:475–9. doi: 10.2350/11-01-0975-CR.1
- Filho BC, McHugh JB, Carrau RL, Kassam AB. Yolk sac tumor in the nasal cavity. *Am J Otolaryngol.* (2008) 29:250–4. doi: 10.1016/j.amjoto.2007.09.001
- Zhang Q, Huang Y, Bao CY, Li LJ. Yolk sac tumour involving floor of mouth: case report. *Br J Oral Maxillofac Surg.* (2013) 51:e67–9. doi: 10.1016/j.bjoms.2012.04.074
- Tekgunduz SA, Bozkurt C, Sahin G, Apaydin S, Oren AC, Balkaya E, et al. A subcutaneous paraspinous yolk sac tumor in a child. *J Pediatr Hematol Oncol.* (2014) 36:e115–7. doi: 10.1097/MPH.0b013e31829d140a
- Pasricha S, Gupta A, Shah M, Vadodaria H. Extragenital yolk sac tumor of face in a female infant: a case report. *Indian J Pathol Microbiol.* (2010) 53:592–3. doi: 10.4103/0377-4929.68269
- Kamal S, Kaliki S, Sreedhar A, Mishra DK. Primary orbital yolk sac tumor: report of a case and review of literature. *Int Ophthalmol.* (2016) 36:435–44. doi: 10.1007/s10792-015-0142-y
- Chen Z, Zheng P, Huang S, Zhang D. Yolk sac tumor of upper lip: a case report. *Oncol Lett.* (2017) 14:6238–42. doi: 10.3892/ol.2017.6918
- Mondal K, Mandal R. Bilateral lung metastases unveils an asymptomatic sacrococcygeal yolk sac tumor. *Indian J Pathol Microbiol.* (2017) 60:565–7. doi: 10.4103/IJPM.IJPM_385_16
- Imaniar R, Syahrudin E, Soepandi PZ, Putra AC, Nurwidya F. Mediastinal yolk sac tumor infiltrating the heart. *Exp Oncol.* (2018) 40:82–4. doi: 10.31768/2312-8852.2018
- Mandelia A, Mutt N, Lal R, Prasad R. Yolk Sac tumor of stomach: case report and review of literature. *J Indian Assoc Pediatr Surg.* (2018) 23:232–3. doi: 10.4103/jiaps.JIAPS_17_18
- van den Akker M, Vervloessem D, Huybrechts A, Declercq S, van der Werff Ten Bosch J. Yolk sac tumor in the abdominal wall of an 18-month-old girl: a case report. *J Med Case Rep.* (2017) 11:47. doi: 10.1186/s13256-017-1216-4
- Sharma C, Shah H, Sisodiya Shenoy N, Makhija D, Waghmare M. Ovarian yolk sac tumour in a girl - case report. *Dev Period Med.* (2017) 21:101–3.
- Yang M, Xin Y. Virilization in a girl caused by an ovarian yolk sac tumor: a case report. *J Pediatr Adolesc Gynecol.* (2019) S1083-3188(19)30001-4. doi: 10.1016/j.jpog.2019.01.001
- Guida M, Pignata S, Palumbo AR, Miele G, Marra ML, Visconti F, et al. Laparoscopic treatment of a Yolk Sac Tumor: case report and literature review. *Transl Med UniSa.* (2013) 7:1–5.
- Christopher SC. *Prepubertal Testicular and Paratesticular Tumors: Medscape Reference*. New York, NY: WebMD LLC (2011).
- Eddaoualline H, Sami H, Rais H, Belbaraka R, El Omrani A, Khouchani M. Ovarian Yolk sac tumor: a case report and literature review. *Clin Case Rep Int.* (2018) 2:1057.
- Khan IU, Jose J, Fawazy T, Hadi WA, Sharma PK. Testicular yolk sac tumor in an eight-month old child: a case report. *Gulf Med J.* (2012) 1:37–40.
- Sell A, Sogaard H, Norgaard-Pedersen B. Serum alpha-fetoprotein as a marker for the effect of post-operative radiation therapy and/or chemotherapy in eight cases of ovarian endodermal sinus tumour. *Int J Cancer.* (1976) 18:574–80.
- Guo YL, Zhang YL, Zhu JQ. Prognostic value of serum alpha-fetoprotein in ovarian yolk sac tumors: a systematic review and meta-analysis. *Mol Clin Oncol.* (2015) 3:125–32. doi: 10.3892/mco.2014.417
- Albany C, Einhorn L. Pitfalls in management of patients with germ cell tumors and slight elevation of serum alpha-fetoprotein. *J Clin Oncol.* (2014) 32:2114–5. doi: 10.1200/JCO.2014.56.0607

AUTHOR CONTRIBUTIONS

LC, K-CY, and S-BY wrote the manuscript. H-JW reviewed and revised the manuscript. All authors approved the final version of this manuscript.

41. Bokemeyer C, Nichols CR, Droz JB, Schmoll HJ, Horwich A, Gerl A, et al. Extragonadal germ cell tumors of the mediastinum and retroperitoneum: results from an international analysis. *J Clin Oncol.* (2002) 20:1864–73. doi: 10.1200/JCO.2002.07.062
42. Ayhan A, Taskiran C, Bozdag G, Altinbas S, Altinbas A, Yuca K. Endodermal sinus tumor of the ovary: the Hacettepe University experience. *Eur J Obstet Gynecol Reprod Biol.* (2005) 123:230–4. doi: 10.1016/j.ejogrb.2005.04.021
43. Curtin JP, Morrow CP, D'Ablaing G, Schlaerth JB. Malignant germ cell tumors of the ovary: 20-year report of LAC-USC Women's Hospital. *Int J Gynecol Cancer.* (1994) 4:29–35.
44. Williams SD, Birch R, Einhorn LH, Irwin L, Greco FA, Loehrer PJ. Treatment of disseminated germ-cell tumors with cisplatin, bleomycin, and either vinblastine or etoposide. *N Engl J Med.* (1987) 316:1435–40.
45. Chang FH, Lai CH, Chu KK, Chang TC, Hsueh S, Hung IJ. Treatment of malignant germ cell tumors of the ovary. *J Formos Med Assoc.* (1994) 93:411–6.
46. Gobel U, Calaminus G, Schneider DT, Schmidt P, Haas RJ, Makei, et al. Management of germ cell tumors in children: approaches to cure. *Onkologie.* (2002) 25:14–22. doi: 10.1159/000055197
47. Rudaitis V, Mickys U, Katinaite J, Dulko J. Successful treatment of advanced stage yolk sac tumour of extragonadal origin: a case report and review of literature. *Acta Med Litu.* (2016) 23:110–6. doi: 10.6001/actamedica.v23i2.3327
48. Williams S, Blessing JA, Liao SY, Ball H, Hanjani P. Adjuvant therapy of ovarian germ cell tumors with cisplatin, etoposide, and bleomycin: a trial of the Gynecologic Oncology Group. *J Clin Oncol.* (1994) 12:701–6.
49. Zanetta G, Bonazzi C, Cantu M, Binidagger S, Locatelli A, Bratina G, et al. Survival and reproductive function after treatment of malignant germ cell ovarian tumors. *J Clin Oncol.* (2001) 19:1015–20. doi: 10.1200/JCO.2001.19.4.1015
50. Byrne J, Mulvihill JJ, Myers MH, Connelly RR, Naughton MD, Krauss MR, et al. Effects of treatment on fertility in long-term survivors of childhood or adolescent cancer. *N Engl J Med.* (1987) 317:1315–21.
51. Kawai M, Kano T, Furuhashi Y, Mizuno K, Nakashima N, Hattori SE, et al. Prognostic factors in yolk sac tumors of the ovary. A clinicopathologic analysis of 29 cases. *Cancer.* (1991) 67:184–92.
52. Ahmed HU, Arya M, Muneer A, Mushtaq I, Sebire NJ. Testicular and paratesticular tumours in the prepubertal population. *Lancet Oncol.* (2010) 11:476–83. doi: 10.1016/S1470-2045(10)70012-7

Conflict of Interest Statement: The authors declare that the research was conducted in the absence of any commercial or financial relationships that could be construed as a potential conflict of interest.

Copyright © 2019 Chen, Yip, Wu and Yong. This is an open-access article distributed under the terms of the Creative Commons Attribution License (CC BY). The use, distribution or reproduction in other forums is permitted, provided the original author(s) and the copyright owner(s) are credited and that the original publication in this journal is cited, in accordance with accepted academic practice. No use, distribution or reproduction is permitted which does not comply with these terms.